paradoxale reacties bij biologische therapieën

An Van Laethem
Dermatologie

Inflammatory bowel disease



Rheumatological diseases



IMIDs

1/3 IBD

Dermatological diseases

- Psoriasis
- Hidradenitis suppurativa
- Pyoderma gangrenosum
- …

Skin manifestations of inflammatory bowel disease

Skin = most frequent extra-intestinal manifestation
≈1/3 IBD patients will develop cutaneous manifestations

- **Malabsorption:** nutritional deficiencies



- **Inflammatory**
  - **Specific**
  - **Reactive**
  - **Associated**



With a common pathogenic link



More frequently encountered
HS prevalence in 1/5 CD reported

Psoriasis incidence (0R 1,8) is increased in IBD

Skin manifestations of Rheumatological diseases

Skin = often relevant extra-articular manifestation

- Systemic auto-immune rheumatological disease **with involvement of the skin**
  SLE, systemic scleroderma, Rheumatoïd arthritis, …

- **Associated skin diseases**

  Psoriatic arthritis ⇢ psoriasis

  Seronegative spondylarthropathy ⇢ Hidradenits suppurativa

  Rheumatoïd arthritis ⇢ Pyoderma gangrenosum

  …

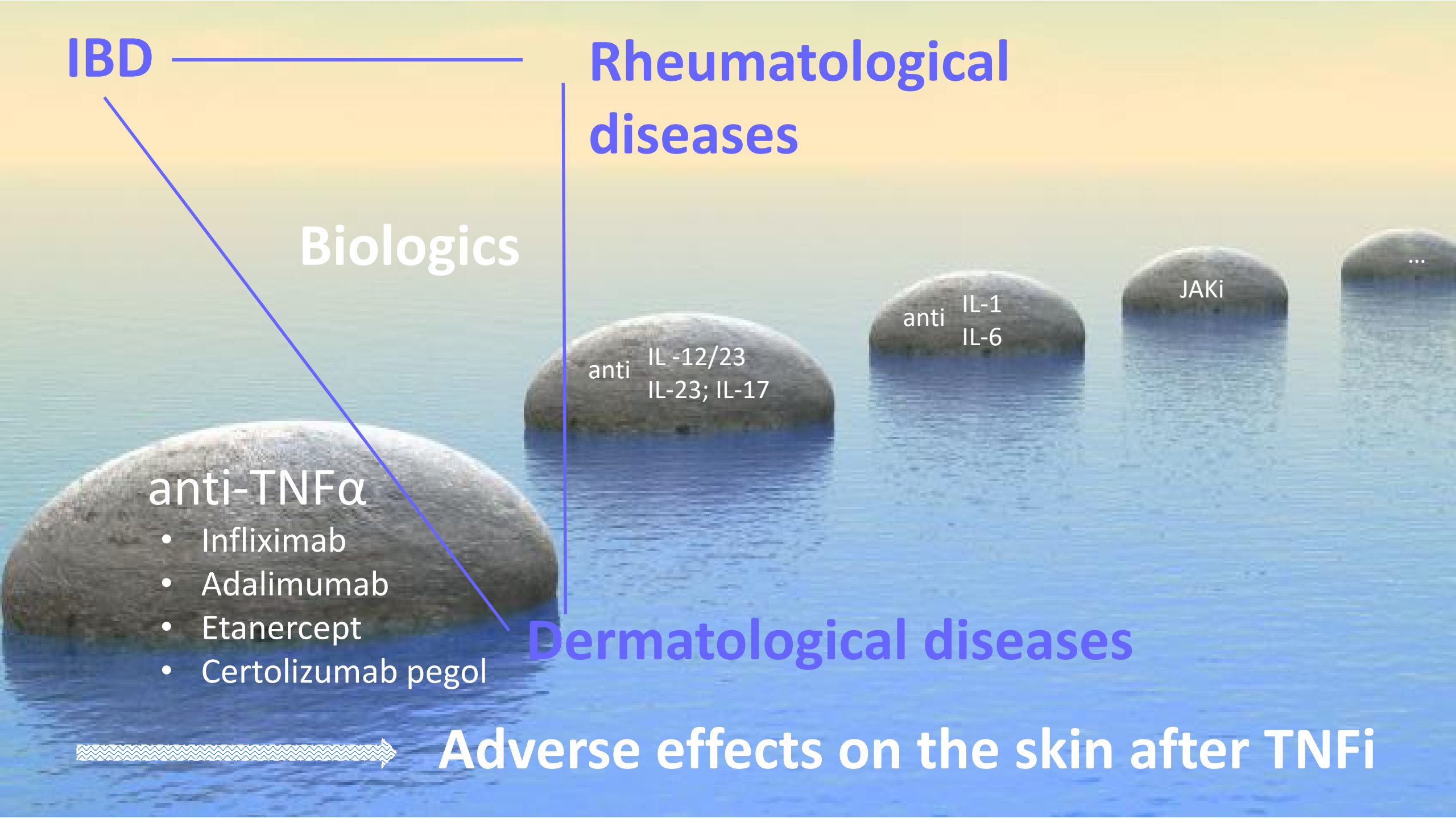
IBD
Rheumatological diseases
Biologics
anti IL -12/23 IL-23; IL-17
anti IL-1 IL-6
JAKi
...
anti-TNFα
• Infliximab
• Adalimumab
• Etanercept
• Certolizumab pegol
Dermatological diseases
Adverse effects on the skin after TNFi

Adverse effects on the skin after TNFi

Skin adverse events after TNFi: 20,5-29%

(More with younger age at initiation and Crohn's disease)

- **Injection site reaction/infusion reaction**
- **Infections** (most common)

  Bacterial, fungal, less common herpes zoster
- **Neoplastic**

  NMSC and Melanoma
- **Auto-immune inflammatory**

  - psoriasis, psoriasiform manifestations
  - Alopecia areata
  - Hidradenitis suppurativa

  - eczema
  - vasculitis
  - Bullous (BP, Linear IgA, ..)
  - Lupus/Lupus-like syndromes
  - ….

→ **New class of adverse events: Biological induced paradoxical skin diseases**

Biological induced paradoxical skin manifestations

Definition

- inflammatory immune- mediated skin reactions
- developing paradoxically during treatment with targeted biologics
- with biologicals that are used to treat the idiopatic counterpart of these skin reactions

class effect of targeted biological agent ⟶ most described with TNFi



Prevalence of cutaneous paradoxical reaction on TNFi 5-10 %

→ prototype reaction: psoriasis, psoriasiform lesions

clinical picture

Like the skin diseases that are normally treated with these biologicals

- **psoriasis**

  plaque, pustular, generalized, palmoplantar, guttate, inverse, scalp

- **psoriasisform eczema**

- **hidradenitis suppurativa**

- **neutrophilic dermatosis**

  pyoderma gangrenosum

- **granulomatous skin diseases**

  granuloma annulare, sarcoïdosis, …

- **…**



Sarcoidosis-Like Lesions: Another Paradoxical Reaction to Anti-TNF Therapy?

Amelie Decock,[a] Gert Van Assche,[b] Séverine Vermeire,[b] Wim Wuyts,[c] Marc Ferrante[b]

Journal of Crohn's and Colitis, 2017, 378–383

Skin diseases often associated with RA and IBD !

TNFi induced because

- improvement after stop TNFi
- relapse when TNFi is reintroduced

ORIGINAL RESEARCH

Annals of Internal Medicine

Characteristics of Skin Lesions Associated With Anti–Tumor Necrosis Factor Therapy in Patients With Inflammatory Bowel Disease

A Cohort Study

Isabelle Cleynen, PhD; Wouter Van Moerkercke, MD; Thomas Billiet, MD; Pieter Vandecandelaere, MD; Niels Vande Casteele, PhD; Christine Breynaert, MD, PhD; Vera Ballet; Marc Ferrante, MD, PhD; Maja Noman, MD; Gert Van Assche, MD, PhD; Paul Rutgeerts, MD, PhD; Joost J. van den Oord, MD, PhD; Ann Gils, PharmD, PhD; Siegfried Segaert, MD, PhD*; and Séverine Vermeire, MD, PhD*

Ann Intern Med 2016

- 264 of 917 (29%) patients developed anti-TNF induced skin lesions

- **30,6% psoriasiform eczema**; 23,5% eczema; 10,6% xerosis cutis

5,3% palmoplantar pustulosis; **3,8% psoriasis;** 26,1% other

clinical picture



plaques





generalized



Ada for Crohn ‘s

pustular



palmoplantar

5m after start Ada for Crohn’s









palmoplantar pustulosis

Infliximab



scalp

Psoriatic alopecia





(↔ can show overlapping features with alopecia areata)

Female, 43 y





Hidradenitis suppurativa

Pyoderma gangrenosum

↓

Adalimumab 03/2016

… about one year later

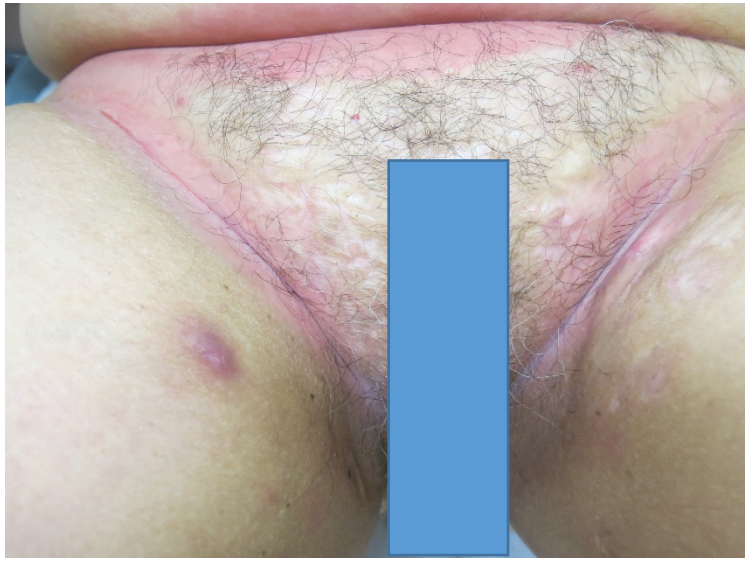







Candida +++
Staphylococcus aureus +++
Streptococcus groep C ++





psoriasiform eczema

Histopathological spectrum

Psoriasiform –like pattern, with spongiotic features and eosinophils

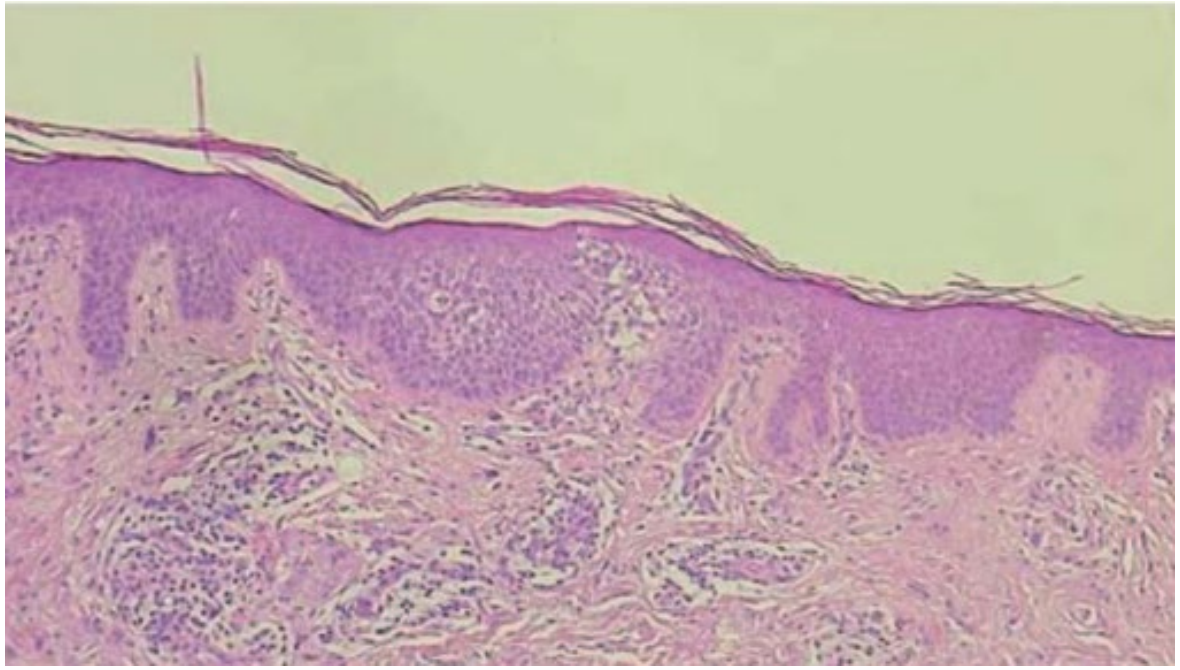

Ann Intern Med 2016



Incidence, Clinical Characteristics, and Management of Psoriasis Induced by Anti-TNF Therapy in Patients with Inflammatory Bowel Disease: A Nationwide Cohort Study *On behalf of the Spanish GETECCU group (ENEIDA project)*

Inflamm Bowel Dis • Volume 22, Number 4, April 2016

Incidence of psoriasiform diseases secondary to tumour necrosis factor antagonists in patients with inflammatory bowel disease: a nationwide population-based cohort study

Aliment Pharmacol Ther. 2018;48:196–205.

The association of psoriasiform rash with anti-tumor necrosis factor (anti-TNF) therapy in inflammatory bowel disease: A single academic center case series

Journal of Crohn's and Colitis (2014) **8**, 480–488

...

- Incidence rate of psoriasis by TNFi is 0,5% (95% C.i.) per patient year (IBD population)
  of new onset psoriasis is 1,04-1,54 per 1000 patient-years
  (British Society for Rheumatology Register)

- Lesions develop 6m (Rheumatol) -12m (IBD) after starting TNFi

- **risk factors**

  Female patients

  (former) smokers

In IBD

- No Familiy or personal history of psoriasis
- No correlation with intestinal disease activity
- Incident rate similar for all anti-TNF

In PsA/pso

- New onset?
- New or different morphology: pustular or guttate lesions,

Mechanism of biological induced paradoxical skin manifestations

- No direct molecular effect of TNFi ?
- Auto-immune via Ab ?
  - More ANA and dsDNA in our cohort
  - No difference in TL; cumulative dose; ADAbs
- targeted manipulation of cytokine molecular network



- specific shift in cytokine and cellular immune response pattern
  - shift of innate immune cells and/or adaptive immune cells to the skin
  - Imbalance or dysfunction of Treg cells
- patients' genetic predisposition

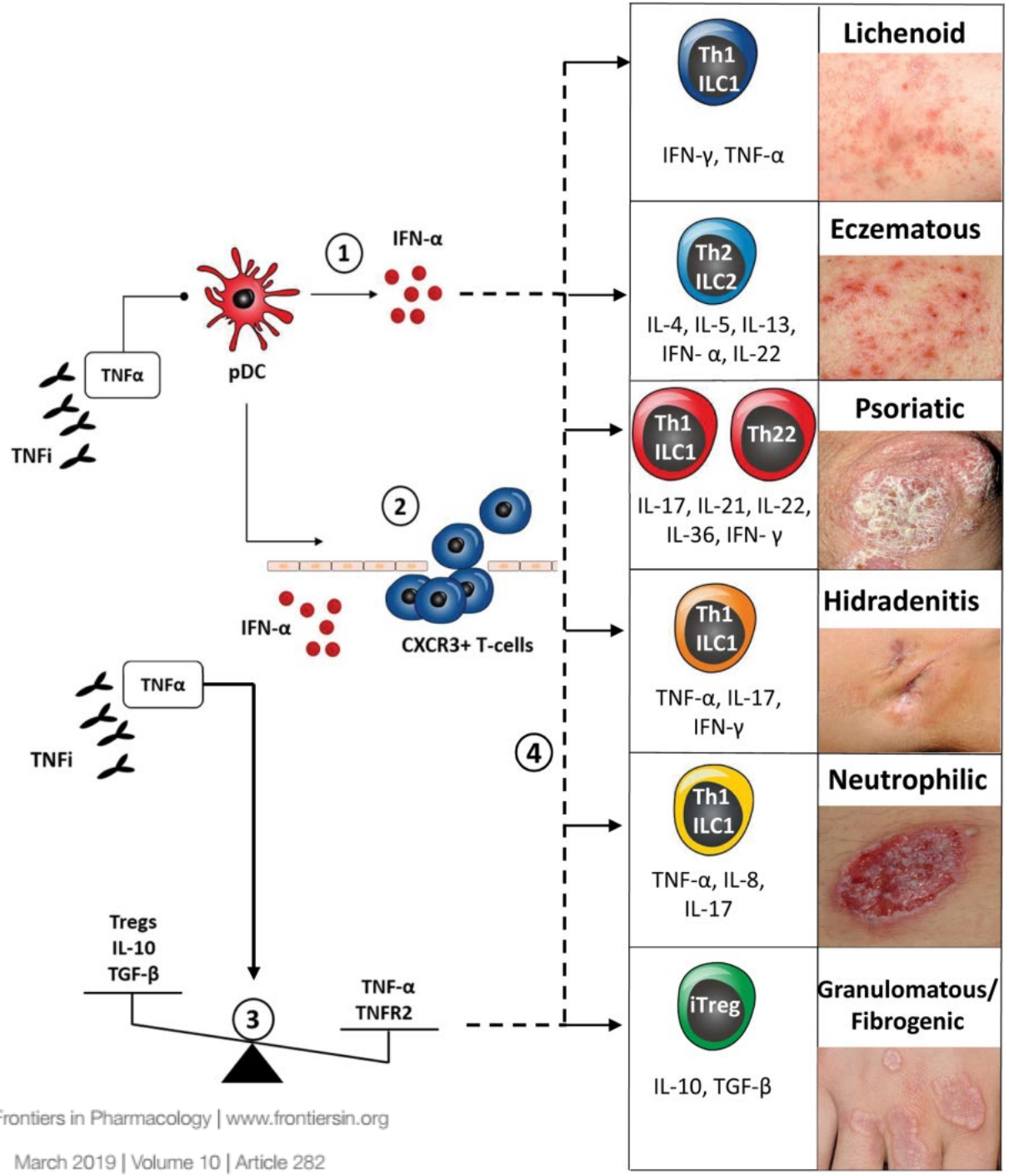

Frontiers in Pharmacology | www.frontiersin.org

March 2019 | Volume 10 | Article 282

psoriasiform lesion

cytokine imbalance



shift in skin immune response pattern of cytokines and cells

↓ Skin homing via CXCR3 on Th1 cells
Role for the IL-23/Th17 immune axis

shift in innate and adaptive immune cells to the skin

↓

in a genetic susceptible host

- known psoriasis risk loci more prevalent in patients with skin lesions
- specific IL23R polymorphism

Management of biological induced paradoxical skin manifestations

- Skin lesions can lead to discontinuation of antiTNF therapy in up to 50% of patients
- Treating the cutaneous condition
- Maintain control of the underlying IMID
  - ✓ Extent and severity of skin symptoms
  - ✓ Activity/severity of background IMID
  - ✓ Patient quality of life and comorbidities
  - ✓ Possible loss of efficacy of culprit BA if cessation
  - ✓ Availability of alternative treatment options

- **No definitive guidelines** → **Case by case**

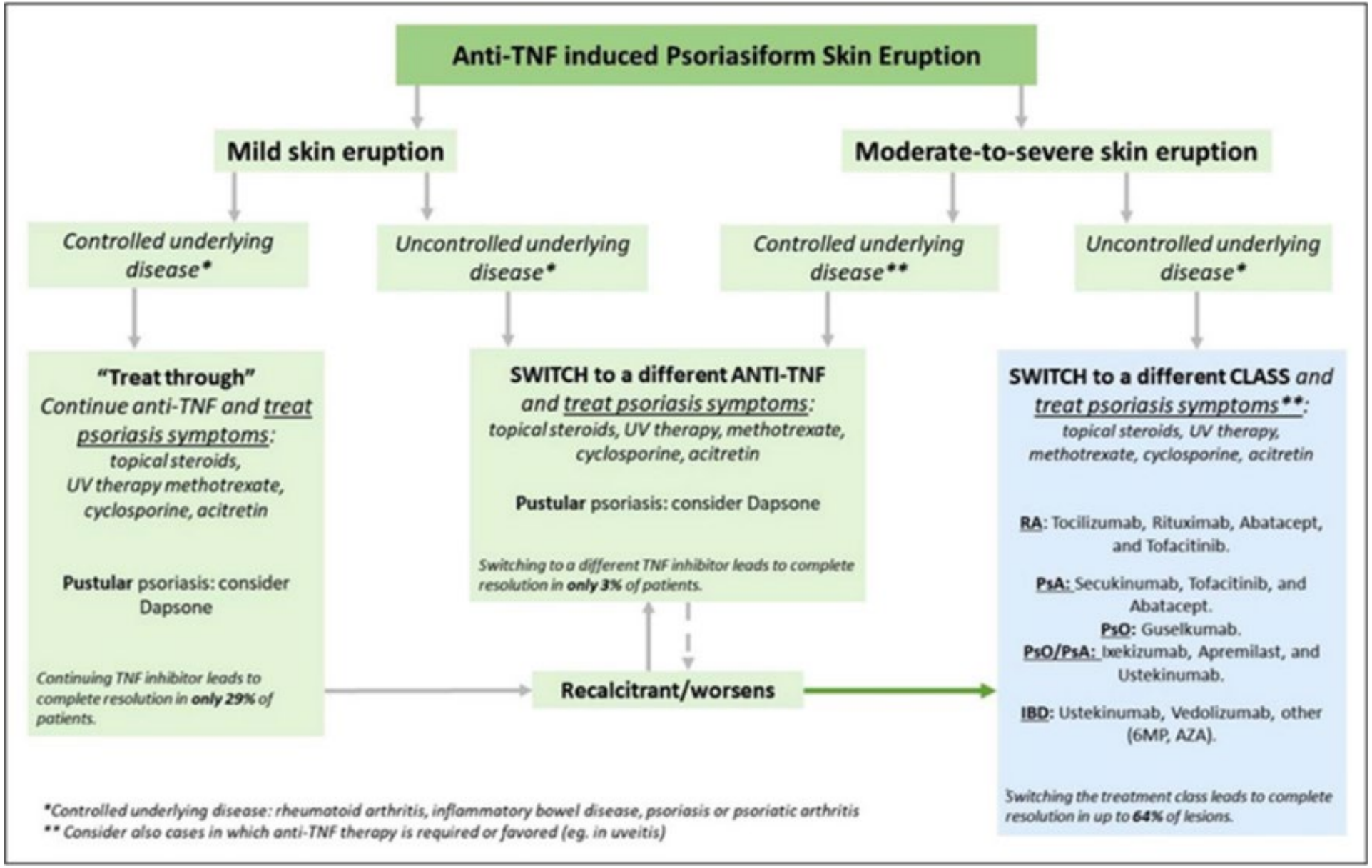

J Psoriasis Psoriatic Arthritis. 2019

Treat through

Mild disease burden, low BSA

More extensive, more burden

STOP/SWITCH



Vitamine D analogue and
potent steroid

Oral acitretine, MTX
UV-therapy (!)



Stop smoking, treat superinfection
Ultrapotent topical steroid
(+ salicylic acid + coal tear)

Oral minocycline, acitretine

Dapsone, MTX
cyclosporine (!)



Avoid superinfection by
decontamination of nose and
anus

Moderately potent topical steroid
Oral antihistamines

Oral AB
MTX?

Conclusion 1/8 pt response on MTX + TNFi continuation
Methotrexate does not appear effective in treating psoriasiform lesions associated with anti-TNF therapy refractory to topical therapy in IBD.

Aliment Pharmacol Ther 2012; **35**: 1175–1180

Succes rate: complete resolution in 26-41%; partial response in 25-57,4 %

STOP/SWITCH

Other TNFi? → Low succes rate (5%) → **Class effect**

Outside the TNFi class → 64,3% resolution of psoriasiform lesions

- **IBD**

  Ustekinumab (IL12/23i)

  Or

  Vedolizumab (anti-integrine)

- **RA**

  Tocilizumab (anti-IL6); Rituximab (anti-B); JAK-i

- **PsA/pso**

  Guselkumab; risankisumab (anti-IL23)
  Ixekizumab; secukinumab (anti-IL17)

(Our hidradenitis patient: acitretine and MTX + stop ADA)



Under ADA for Crohn’s



After Ustekinumab

Paradoxical skin manifestations that are treatment induced

Specific phenomenon in the era of TNF antagonists



also with other class therapies



Paradoxical pustular psoriasis induced by ustekinumab in a patient with Crohn's disease-associated spondyloarthropathy

Michael Benzaquen[1] Benoit Flachaire[1] · Frank Rouby[2] · Philippe Berbis[1] · Sandrine Guis[2,3]

Rheumatology International (2018) 38:1297–1299

CASES WITH A MESSAGE

Secukinumab-induced paradoxical hidradenitis suppurativa

Francisco J. Navarro-Triviño[1] | Ricardo Sanchez-Parera[2] | Ricardo Ruiz-Villaverde[1]

Dermatologic Therapy. 2019;e13150.
https://doi.org/10.1111/dth.13150

Other organ paradoxical manifestations that are treatment induced

Paradoxical ulcerative colitis during adalimumab treatment of psoriasis resolved by switch to ustekinumab

A.G.A. Kolios,[1,2] L. Biedermann,[3] A. Weber,[4] A.A. Navarini,[2] J. Meier,[5] A. Cozzio[6] and L.E. French[2]

British Journal of Dermatology (2018) **178**, pp551–555

Do Anti-TNF Agents Increase the Risk of Inflammatory Bowel Disease Evolution in Patients with Ankylosing Spondylitis? Real Life Data

Döndü Üsküdar Cansu, M.D., Hava Üsküdar Teke, M.D., Tuncer Temel, M.D., Adem Ertürk, M.D., Osman Kahraman, M.D., Cengiz Korkmaz, M.D.

JOURNAL OF THE NATIONAL MEDICAL ASSOCIATION VOL 111, NO 3, JUNE 2019 **263**

thanks for listening!

