PSMA-PET: beyond biochemisch herval?

Prof. dr. Karolien Goffin
Nuclear Medicine & Molecular Imaging
UZ Leuven – KU Leuven

Pentalfa 7 mei 2020 – Theranostics in prostaatkanker

PSMA

- Prostate-specific membrane antigen
  - Type II transmembrane protein with a short NH_2-terminal cytoplasmic domain (CD), a hydrophobic transmembrane region (TM), and a large extracellular domain (ED).
- Excellent target for imaging and therapy
  - Expressed by nearly all prostate cancer cells
    - But keep in mind that 10% of PCa is PSMA negative!
  - Enhanced expression levels in poorly differentiated, metastatic, and hormone-refractory carcinomas
  - Low levels of physiologic PSMA expression in brain, salivary glands, kidney, spleen, liver, and small intestine
- Different types of diagnostic and therapeutic ligands available

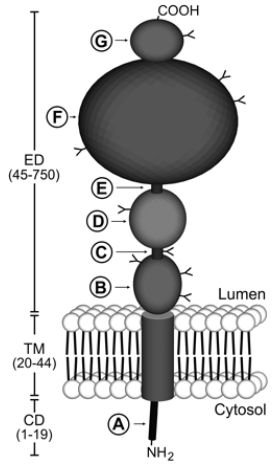

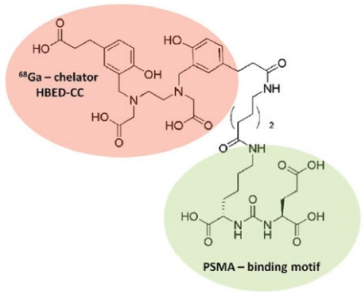

Murphy et al., Cancer 1998
Silver et al., Clin Cancer Res 1997
Rieter et al., Clin Nucl Med 2011
Rajasekaran et al., Amer Journal Phys 2005
Vallabhajosula et al., JNM 2014
Eder et al., Bioconjug Chem 2012

When life was easy…



- ^{68}Ga-PSMA-11
- Biochemisch recidief

^{68}Ga-PSMA-11



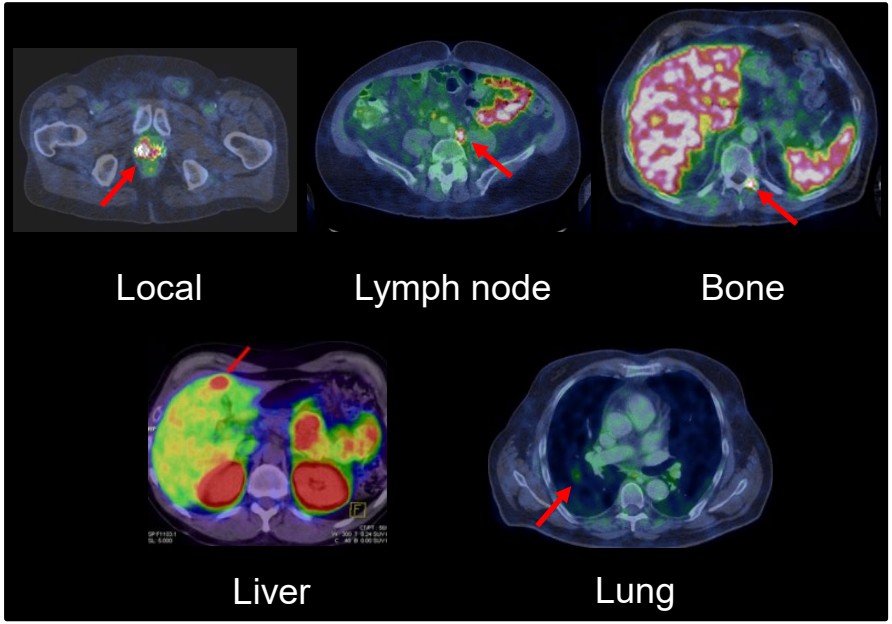

Fig. 1 MIP of a patient with normal biodistribution of ^{68}Ga-PSMA 1 h after injection. Accumulation is seen in lacrimal and salivary glands, nasal mucosa, liver, spleen, bowel, kidneys and bladder

^{68}Ga-PSMA PET/CT: eerste studie

PET imaging with a [^{68}Ga]gallium-labelled PSMA ligand for the diagnosis of prostate cancer: biodistribution in humans and first evaluation of tumour lesions

A. Afshar-Oromieh · A. Malcher · M. Eder · M. Eisenhut · H. G. Linhart · B. A. Hadaschik · T. Holland-Letz · F. L. Giesel · C. Kratochwil · S. Haufe · U. Haberkorn · C. M. Zechmann

- 37 patients with biochemical recurrence
- Overall detection rate 84%
- PSA
  - <2.2 ng/ml: detection rate 60%
  - >2.2 ng/ml: detection rate 100 %
- Excellent tumor-to-background ratio

Patient no.	Age (years)	Dosage (MBq)	GSC	PSA (ng/ml)	Lymph node metastases	Bone metastases	Local relapse	Soft tissue metastases
1	70	120	7	1.13	0	0	1	0
2	**65**	**120**	**8**	**0.10**	**0**	**0**	**0**	**0**
3	72	96	7	2.00	1	0	0	0
4	68	105	9	36.00	2	>5	0	0
5	69	90	7	1.10	1	0	0	0
6	72	116	5	4.00	0	0	1	0
7	73	139	6	7.40	0	0	1	0
8	**66**	**123**	**7**	**0.80**	**0**	**0**	**0**	**0**
9	52	148	6	0.10	0	0	0	1
10	68	68	9	9.60	0	0	2	0
11	63	152	7	0.10	2	3	0	0
12	75	169	7	19.80	0	1	0	0
13	80	182	9	7.50	1	0	0	0
14	86	93	7	2.60	0	0	2	0
15	71	172	7	2.90	0	1	0	0
16	74	133	7	34.00	>5	0	0	0
17	56	103	9	148.00	0	>5	0	0
18	70	117	7	7.40	2	0	0	0
19	73	96	9	4.80	1	0	0	0
20	75	82	8	0.04	1	0	0	1
21	67	96	9	0.01	0	1	0	2
22	76	52	5	11.90	>5	0	0	0
23	71	130	7	31.00	>5	1	1	0
24	61	59	8	1.50	0	0	0	1
25	66	185	9	7.10	0	>5	1	0
26	**71**	**200**	**7**	**0.50**	**0**	**0**	**0**	**0**
27	87	121	8	2.90	0	0	1	0
28	73	130	8	3.30	0	0	0	1
29	65	212	6	11.20	0	0	2	0
30	62	65	7	1.70	0	1	0	0
31	**68**	**148**	**7**	**0.10**	**0**	**0**	**0**	**0**
32	73	79	8	10.60	1	0	0	0
33	**62**	**85**	**9**	**2.20**	**0**	**0**	**0**	**0**
34	82	148	7	14.60	1	0	0	0
35	62	142	9	3.80	>5	>5	0	0
36	**63**	**161**	**7**	**0.10**	**0**	**0**	**0**	**0**
37	60	154	9	4.20	0	>5	0	0

Afshar-Oromieh et al., EJNMMI 2013

^{68}Ga-PSMA PET/CT: grote retrospectieve reeksen

Diagnostic performance of ^{68}Ga-PSMA-11 (HBED-CC) PET/CT in patients with recurrent prostate cancer: evaluation in 1007 patients

Ali Afshar-Oromieh[1,2] · Tim Holland-Letz[3] · Frederik L. Giesel[1] · Clemens Kratochwil[1] · Walter Mier[1] · Sabine Haufe[1] · Nils Debus[1] · Matthias Eder[2] · Michael Eisenhut[4] · Martin Schäfer[4] · Oliver Neels[4] · Markus Hohenfellner[5] · Klaus Kopka[4] · Hans-Ulrich Kauczor[6] · Jürgen Debus[7] · Uwe Haberkorn[1,2]

Characteristic	Value
Age (years) (n = 1007)	
Mean ± SD	68 ± 7.8
Median (range)	68 (39–90)
Gleason score (n = 864; missing 143)	
Mean ± SD	8.0 ± 1.0
Median (range)	7 (5–10)
PSA at PET (ng/ml) (n = 971; missing 36)	
Mean ± SD	12.1 ± 53.9
Median (range)	2.2 (0.01–1,237)
Prostatectomy (n)	
Yes	828
No	175
Radiation therapy (n)[a]	
Yes	600
No	392
Androgen deprivation therapy at PET (n)	
Yes	221
No	680

[a] To the prostate gland or the prostate fossa after prostatectomy

Afshar-Oromieh et al., EJNMMI 2017

Evaluation of Hybrid ^{68}Ga-PSMA Ligand PET/CT in 248 Patients with Biochemical Recurrence After Radical Prostatectomy

Matthias Eiber*[1,2], Tobias Maurer*[3], Michael Souvatzoglou[1], Ambros J. Beer[1,4], Alexander Ruffani[1], Bernhard Haller[5], Frank-Philipp Graner[1], Hubert Kübler[3], Uwe Haberhorn[6], Michael Eisenhut[6], Hans-Jürgen Wester[7], Jürgen E. Gschwend[3], and Markus Schwaiger[1]

Characteristic	*n*
No. of patients	248
Primary RP	241 (97.2%)
Salvage prostatectomy after primary radiation therapy	7 (2.8%)
Age (y)	
Median	70
Range	46–85
Primary Gleason score*	
Median	7
Range	6–10
PSA (ng/mL)	
Median	1.99
Range	0.2–59.4
Further treatment	
No. of patients with external radiation after RP	20
No. of patients with antihormonal treatment during/within 6 mo prior imaging	70

Eiber et al., JNM 2015

^{68}Ga-PSMA PET/CT: grote retrospectieve reeksen

The diagnostic value of PET/CT imaging with the ^{68}Ga-labelled PSMA ligand HBED-CC in the diagnosis of recurrent prostate cancer

Ali Afshar-Oromieh · Eleni Avtzi · Frederik L. Giesel · Tim Holland-Letz · Heinz G. Linhart · Matthias Eder · Michael Eisenhut · Silvan Boxler · Boris A. Hadaschik · Clemens Kratochwil · Wilko Weichert · Klaus Kopka · Jürgen Debus · Uwe Haberkorn

- Detection rate: 80%

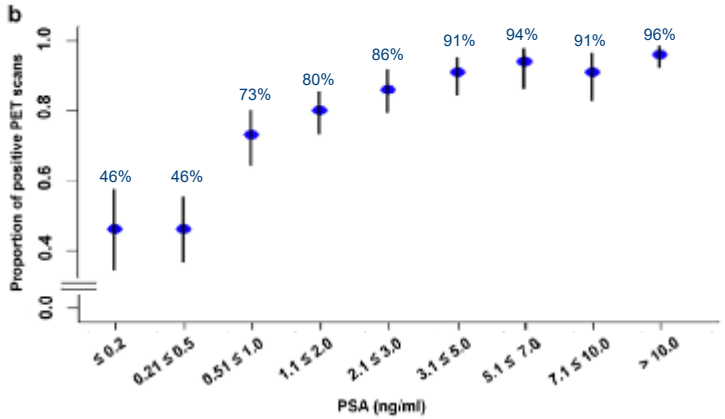

Afshar-Oromieh et al., EJNMMI 2015

Evaluation of Hybrid ^{68}Ga-PSMA Ligand PET/CT in 248 Patients with Biochemical Recurrence After Radical Prostatectomy

Matthias Eiber*[1,2], Tobias Maurer*[3], Michael Souvatzoglou[1], Ambros J. Beer[1,4], Alexander Ruffani[1], Bernhard Haller[5], Frank-Philipp Graner[1], Hubert Kübler[3], Uwe Haberhorn[6], Michael Eisenhut[6], Hans-Jürgen Wester[7], Jürgen E. Gschwend[3], and Markus Schwaiger[1]

- Detection rate: 90%

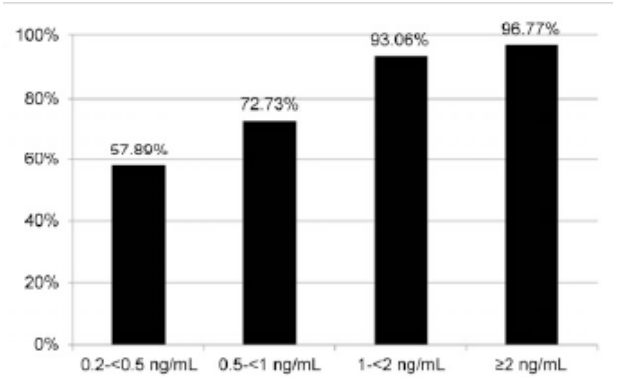

Eiber et al., JNM 2015

PSMA ligands



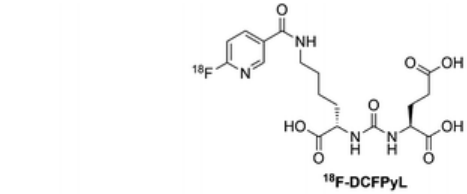

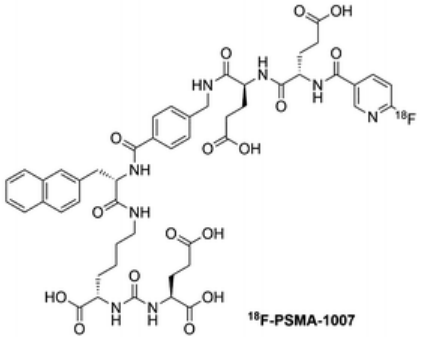

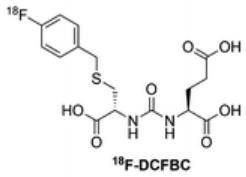

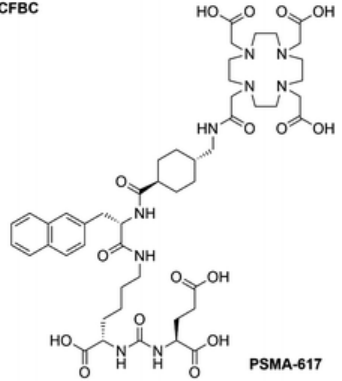

...

^{18}F-PSMA-1007 PET/CT

Detection Efficacy of ^{18}F-PSMA-1007 PET/CT in 251 Patients with Biochemical Recurrence of Prostate Cancer After Radical Prostatectomy

Frederik L. Giesel[1–3], Karina Knorr[4], Fabian Spohn[1,2], Leon Will[1], Tobias Maurer[5], Paul Flechsig[1], Oliver Neels[2,6], Kilian Schiller[7], Horacio Amaral[8], Wolfgang A. Weber[4], Uwe Haberkorn[1,3], Markus Schwaiger[4], Clemens Kratochwil[1], Peter Choyke[9], Vasko Kramer[8], Klaus Kopka[2,6], and Matthias Eiber[2,4]

- Retrospective analysis
- 251 patients with biochemical recurrence
  - Median PSA 1.2 ng/ml (range 0.02-228 ng/ml)
- Detection rate: 81%

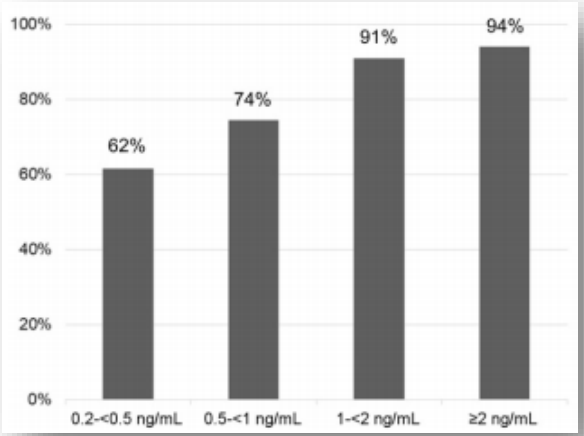

Giesel et al., JNM 2019

Advantages? YES!

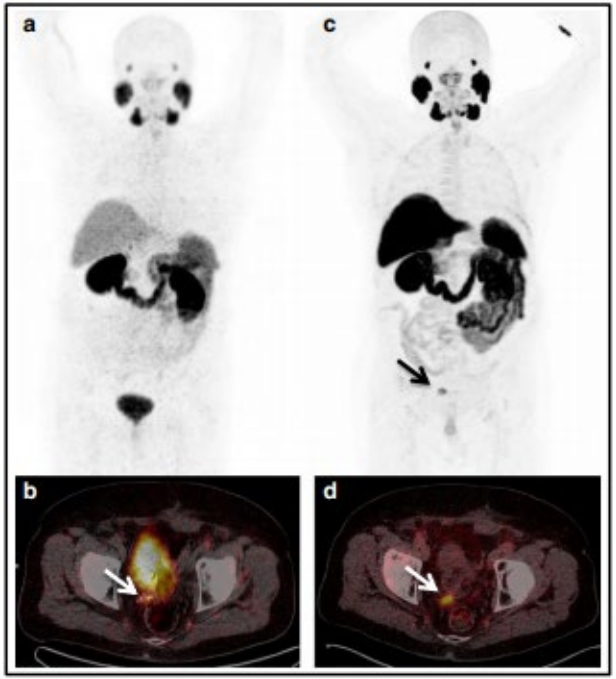

^{68}Ga-PSMA-11 ^{18}F-PSMA-1007

74-year-old prostate cancer patient
Radical prostatectomy (Gleason score 9)
Biochemical recurrence (PSA: 2.1 ng/dl)

Rahbar et al., EJNMMI 2018

But also challenges!

Biodistribution is different between tracers

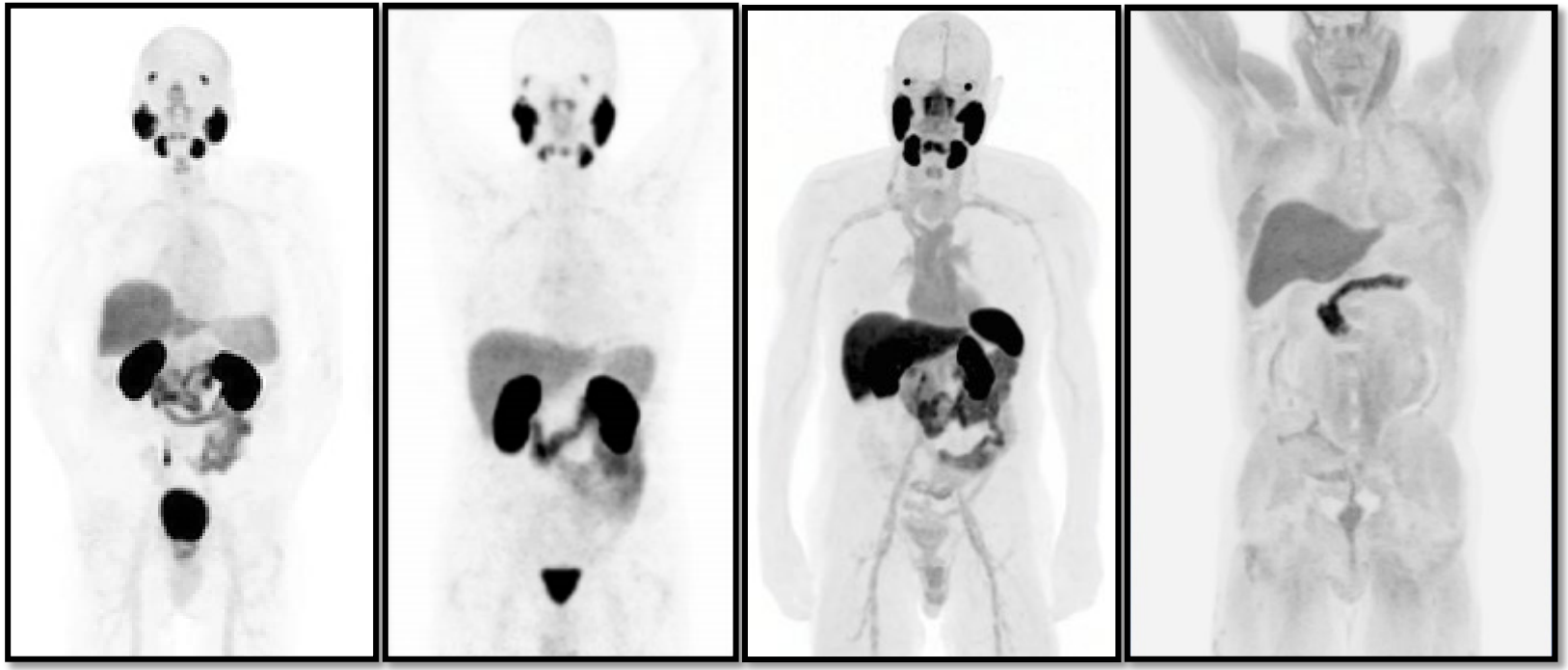

^{18}F-DCFPyL | ^{68}Ga-PSMA-11 | ^{18}F-PSMA-1007 | ^{18}F-FACBC (Axumin)

^{68}Ga-PMSA-11 vs ^{18}F-PSMA-1007

- 204 patients with biochemical recurrence
  - 102 patients ^{18}F-PSMA-1007
  - 102 matched patients (clinical variables) ^{68}Ga-PSMA-11
  - Methods: all PET positive lesions noted => suspicious for recurrent PC vs benigne, based on known pitfalls and information from CT

	^{18}F-PSMA-1007	^{68}Ga-PSMA-11
Positive lesions	369	178
Suspicious lesions	124 (34%)	126 (71%)
Benign lesions	**245 (66%)**	**52 (29%)**

	^{18}F-PSMA-1007	^{68}Ga-PSMA-11
Ganglia	43%	29%
Unspecific LNs	31%	42%
Bone lesions	24%	27%

Rausher et al., JNM 2019

Need for standardized reporting?



Category	Findings
PSMA-RADS-1 (benign)	
PSMA-RADS-1A	Benign lesion characterized by biopsy or pathognomonic finding on anatomic imaging and without abnormal uptake (Fig. 1).
PSMA-RADS-1B	Benign lesion characterized by biopsy or pathognomonic finding on anatomic imaging and with focal radiotracer uptake (Fig. 2).
PSMA-RADS-2 (likely benign)	Equivocal (focal, but low level such as blood pool) uptake in soft-tissue site atypical of PCa involvement (e.g., axillary or hilar lymph nodes) (Fig. 3); equivocal uptake in bone lesion atypical of PCa involvement (e.g., uptake fused to bone lesion and strongly suspected of being degenerative or another benign etiology) (Fig. 4).
PSMA-RADS-3 (equivocal*)	
PSMA-RADS-3A	Equivocal uptake in soft-tissue site typical of PCa involvement (e.g., pelvic or retroperitoneal lymph nodes). If targetable for biopsy (up to and including excision), biopsy may help confirm diagnosis. Alternatively, follow-up imaging (either anatomic or PSMA-targeted PET/CT) showing progression can confirm diagnosis. We recommend initial follow-up period of 3–6 mo (Fig. 5).
PSMA-RADS-3B	Equivocal uptake in bone lesion not definitive but also not atypical of PCa on anatomic imaging (i.e., pure marrow-based lesion with little if any surrounding bony reaction, lytic or infiltrative lesion, or classic osteoblastic lesion [Fig. 6]). Comparison to bone scan, $Na^{18}F$ PET, or tumor-protocol MR images may be helpful, and bone biopsy may have a role. Alternatively, follow-up imaging (either anatomic or PSMA-targeted PET/CT) with evidence of progression may confirm diagnosis. We recommend initial follow-up period of 3–6 mo.
PSMA-RADS-3C	Intense uptake in site highly atypical of all but advanced stages of PCa. Likelihood of nonprostatic malignancy or other benign tumor is high (Fig. 7). Biopsy to confirm diagnosis histologically is often preferred, although organ-specific follow-up imaging may be done (e.g., liver-protocol MRI to evaluate possible primary hepatocellular carcinoma).
PSMA-RADS-3D	Lesion suggestive of malignancy on anatomic imaging but lacking uptake (Fig. 8). Differential considerations include nonprostatic malignancy, neuroendocrine PCa, and an uncommon case of prostate adenocarcinoma that fails to express PSMA. Biopsy to confirm diagnosis histologically is often preferred, although organ-specific follow-up imaging may be done.
PSMA-RADS-4 (PCa highly likely)	Intense uptake in site typical of PCa but lacking definitive findings on conventional imaging (Fig. 9). Given the high specificity of PSMA agents in all reported series, it is unlikely that biopsy confirmation will be needed, although obtaining tissue for genomic analysis or other purposes may be useful.
PSMA-RADS-5 (PCa almost certainly present)	Intense uptake in site typical of PCa and having corresponding findings on conventional imaging (Fig. 10). Given the high specificity of PSMA agents in all reported series, it is unlikely that biopsy confirmation will be needed, although obtaining tissue for genomic analysis or other purposes may be useful.

*Further work-up can be considered.



Rowe et al., JNM 2018

Primary LN staging

Diagnostic Efficacy of ^{68}Gallium-PSMA Positron Emission Tomography Compared to Conventional Imaging for Lymph Node Staging of 130 Consecutive Patients with Intermediate to High Risk Prostate Cancer

Tobias Maurer,*,† Jürgen E. Gschwend,* Isabel Rauscher,* Michael Souvatzoglou,* Bernhard Haller,* Gregor Weirich,* Hans-Jürgen Wester,‡ Matthias Heck,* Hubert Kübler,* Ambros J. Beer,* Markus Schwaiger* and Matthias Eiber*

- 130 patients with primary intermediate or high risk PCa
- Imaging before RP + template pelvic LND
- LN mets in 41 of 130 patients (31.5%)
- Patient based analysis
  - PSMA PET (red): sens 66%, spec 99%
  - CT/MRI (blue): sens 44%, spec 85%
- False negative LNs
  - Primary Pca PSMA negative
  - Micrometastases

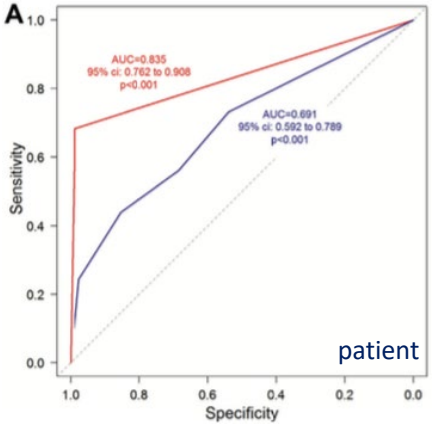



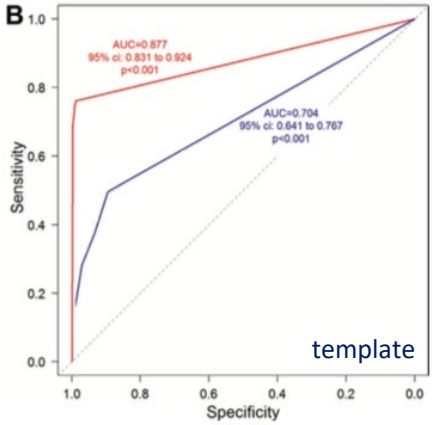



Maurer et al., J Urol 2016

Primary LN staging

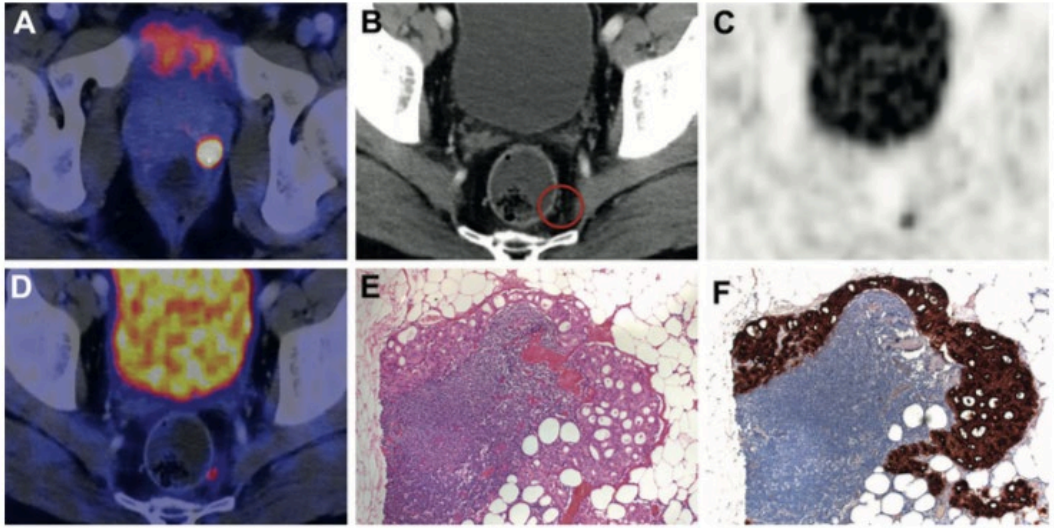

Figure 2. Example of LN metastasis correctly classified by ^{68}Ga-PSMA-PET in patient with PSMA expressing primary PCa (pT2a pN1 [1/32] cM0, Gleason score 4 + 4 = 8 and initial PSA 9.6 ng/ml). Primary tumor shows intense uptake in projection on left peripheral zone on ^{68}Ga-PSMA-PET/CT fusion image (*A*). Unsuspicious 3 mm LN (circle) is visible in left deep internal, pararectal LN template on CT alone (*B*). That lesion shows moderate but suspicious tracer uptake on ^{68}Ga-PSMA-PET (*C*) and PET/CT fusion (*D*). Histological evaluation revealed single 2 mm LN metastasis (*E* and *F*). H&E (*E*) and PSMA immunohistochemistry stain (*F*), reduced from ×100.

Maurer et al., J Urol 2016

proPMSA in primary staging

Prostate-specific membrane antigen PET-CT in patients with high-risk prostate cancer before curative-intent surgery or radiotherapy (proPSMA): a prospective, randomised, multicentre study

*Michael S Hofman, Nathan Lawrentschuk, Roslyn J Francis, Colin Tang, Ian Vela, Paul Thomas, Natalie Rutherford, Jarad M Martin, Mark Frydenberg, Ramdave Shakher, Lih-Ming Wong, Kim Taubman, Sze Ting Lee, Edward Hsiao, Paul Roach, Michelle Nottage, Ian Kirkwood, Dickon Hayne, Emma Link, Petra Marusic, Anetta Matera, Alan Herschtal, Amir Iravani, Rodney J Hicks, Scott Williams, Declan G Murphy, for the proPSMA Study Group Collaborators**

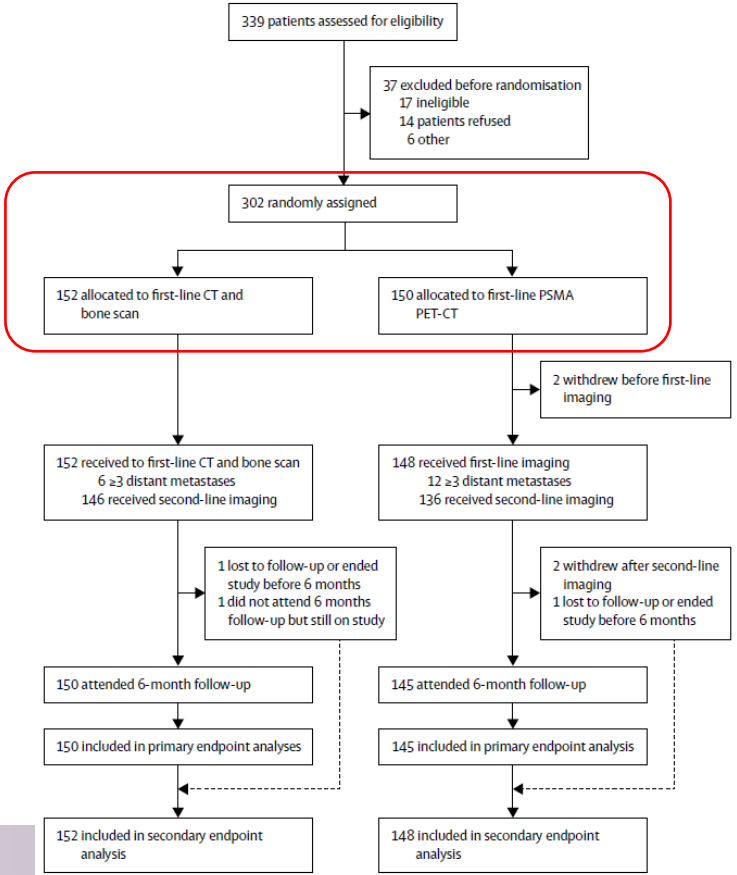

- CE-CT abdomen & bone scan with SPECT/CT of thorax/abdomen
- Predefined reference standard including histopathology, imaging and biochemistry at 6 months

Hofman et al., Lancet 2020

proPMSA in primary staging

	N	Positive True/False	Negative True/False	AUC (95% CI)	Specificity (95% CI)	Sensitivity (95% CI)
Primary analysis						
Any metastatic disease	150	18/9	94/29	65%	91%	38%
	145	34/2	103/6	92%	98%	85%
Pelvic nodal	150	9/4	106/31			
	145	29/1	109/6			
Distant metasases	150	13/9	117/11			
	145	22/1	120/2			
Sensitivity analysis: equivocal lesions treated as positive						
Any metastatic disease	150	26/35	68/21			
	145	35/11	94/5			
Pelvic nodal	150	11/11	99/29			
	145	29/2	108/6			
Distant metasases	150	16/37	89/8			
	145	22/11	110/2			

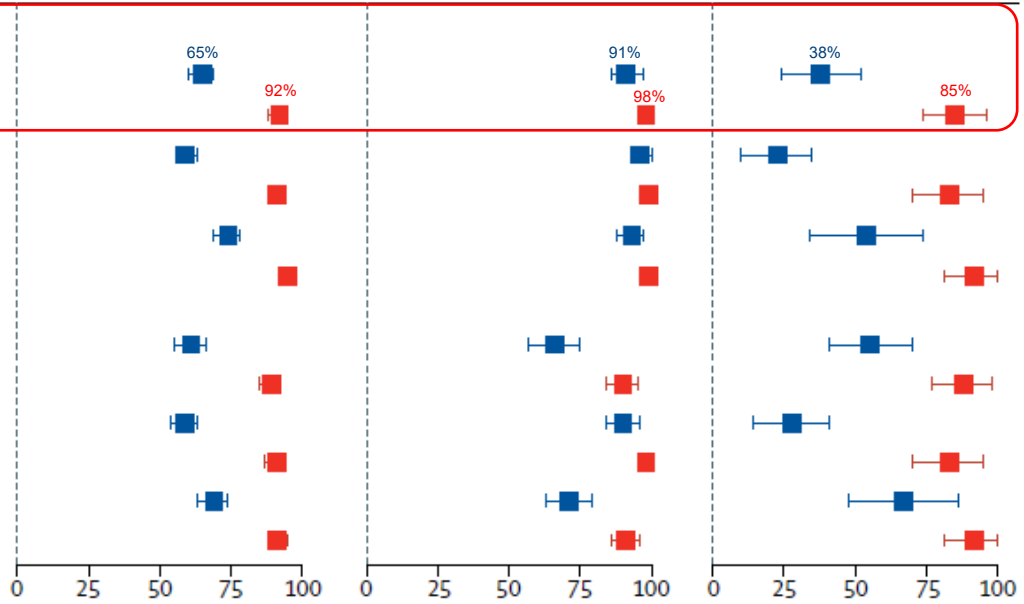

proPMSA in primary staging

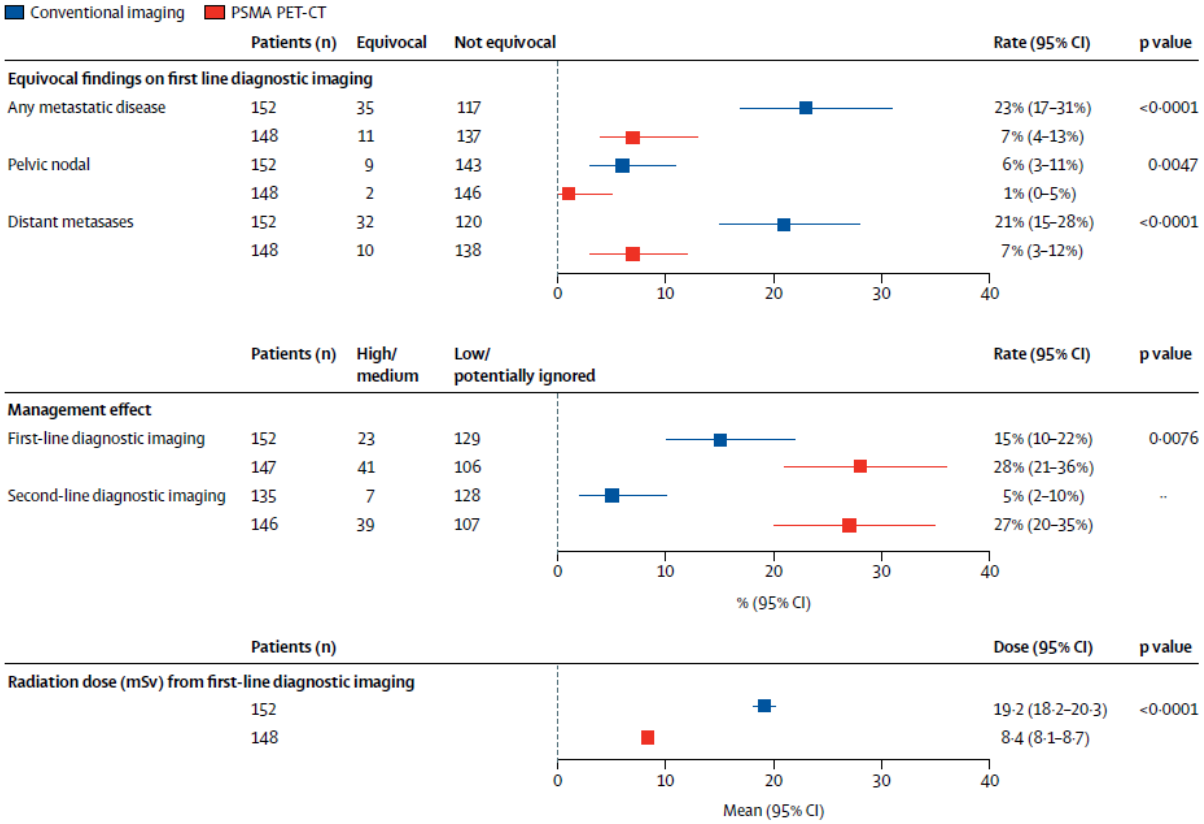

Response assessment: what can we use?



- Soft-tissue metastases => morphological imaging using RECIST criteria
- Bone metastases => bone scan
  - Bone Scan Index?
  - ! FP diagnosis of progressive disease due to ‘flare‘ phenomenon (within 8-12 weeks of treatment initiation)
  - PCWG3-criteria: at least two new lesions on follow-up bone scan with confirmatory bone scan at least 6 weeks later
- PSMA-PET/CT?

Response assessment: challenges

- Feb 2017: robot-geassisteerde RP; Gl 8
- Feb 2018: RT prostaatloge
- Sep 2018: PSA ↑, choline-PET: verdachte mediastinale LNs => ADT tot jan 2019
- Jan 2019: start abiraterone met response assessment met PSMA-PET

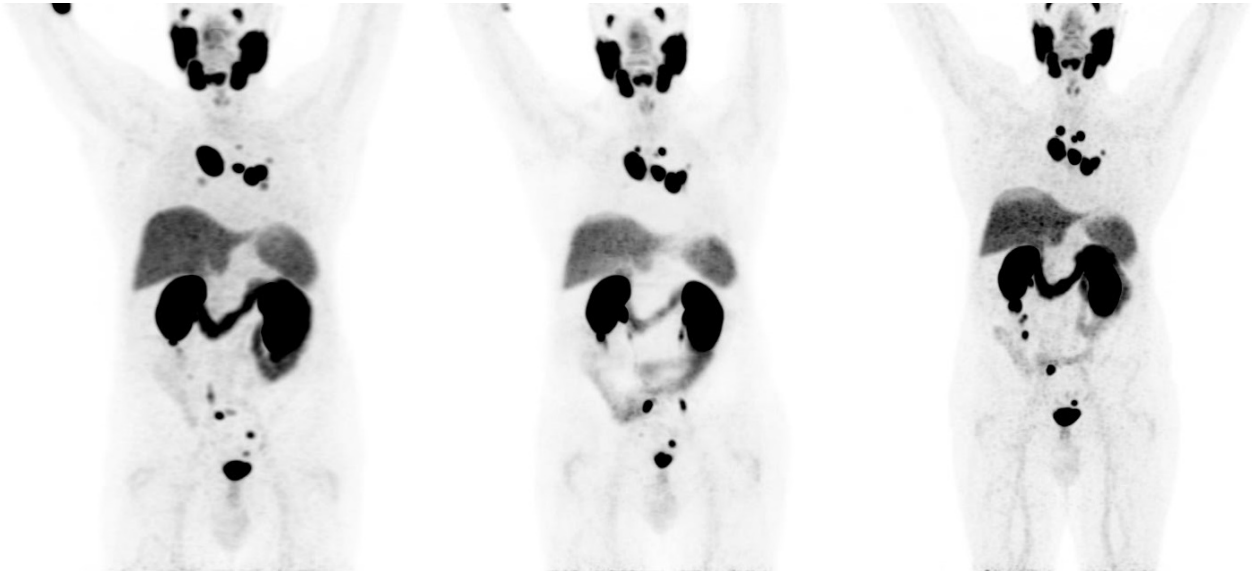

Jan 2019 Jun 2019 Sep 2019

Courtesy of prof. S. Fanti, Bologna

Response assessment: challenges

- ProstaatCa sinds 2012 met uitgebreid behandelingstraject

- Mar 2019: abiraterone, gezien progressief 3 cycli docetaxel, gevolgd door Ac-PSMA therapie in juli 2019 en sep 2019
- Oct 2019: response assessment met PSMA-PET

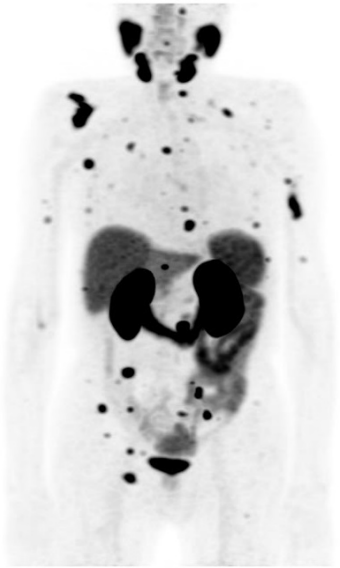

Mar 2019

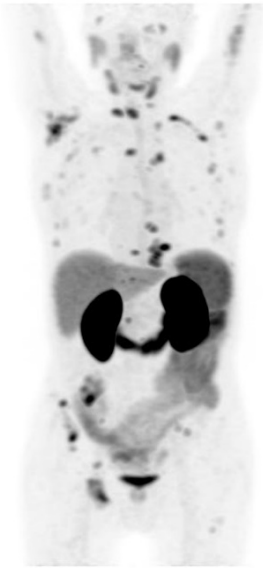

Oct 2019

Courtesy of prof. S. Fanti, Bologna

Response assessment using PSMA-PET

- PPP (PSMA PET progression) criteria

Progression criterion	Explanation
2 or more new PSMA-positive lesions	Appearance of 2 or more new PSMA-positive distant lesions
1 new PSMA-positive lesion	Appearance of 1 new PSMA-positive lesion plus consistent clinical or laboratory data and recommended confirmation by biopsy or correlative imaging within 3 mo of PSMA PET
No new lesions but size increase	Increase by ≥30% in size or uptake plus consistent clinical or laboratory data and confirmation by biopsy or correlative imaging within 3 mo of PSMA PET

- Applicable / clinically relevant in all patients?
- No definition of response

Fanti et al., JNM 2020

Response assessment using PSMA-PET

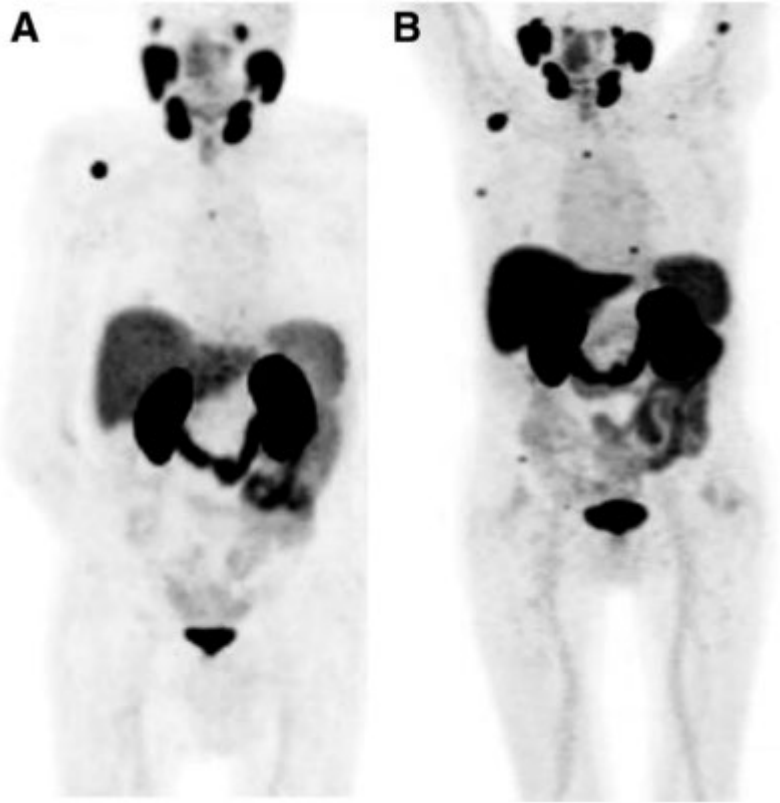

FIGURE 1. PPP for appearance of more than 2 new distant lesions in 77-y-old patient after radical prostatectomy (pT3bpN0 Mx; Gleason score, 4 + 4; initial prostate-specific antigen, 11 ng/mL), who received consecutive treatment with androgen deprivation therapy. At presentation of BCR, baseline PSMA PET showed some PSMA-avid lesions. (B) After additional treatment, scan revealed several new lesions. According to PPP, more than 2 new PSMA-avid lesions—and accordingly progression—are present.

Response assessment using PSMA-PET

Apr 2018: start abiraterone met response assessment met PSMA-PET

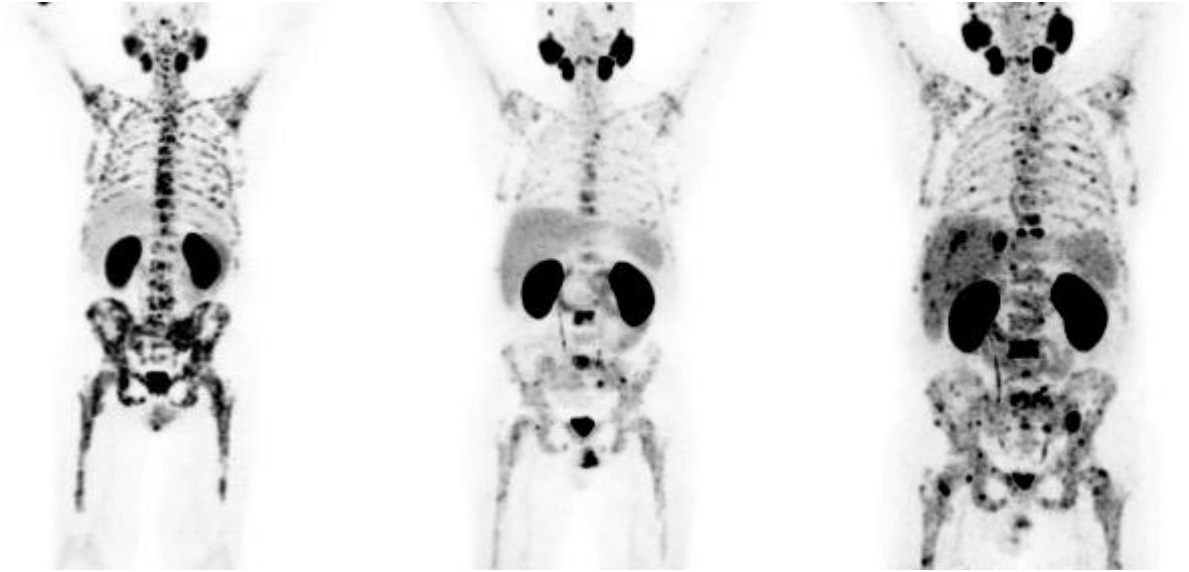

Apr 2018
PSA 18.7

Oct 2018
PSA 2.2

Jan 2019
PSA 5

Courtesy of prof. S. Fanti, Bologna

Response assessment using PSMA-PET



- Need for semi-quantitative measure including tumor volume
  - Modified PERCIST
  - wb PSMA-TV
  - wb TL-PSMA (PMSA-TV x SUV_{mean})

- EAU/EANM working group criteria
  - Define > test in research > use in clinic

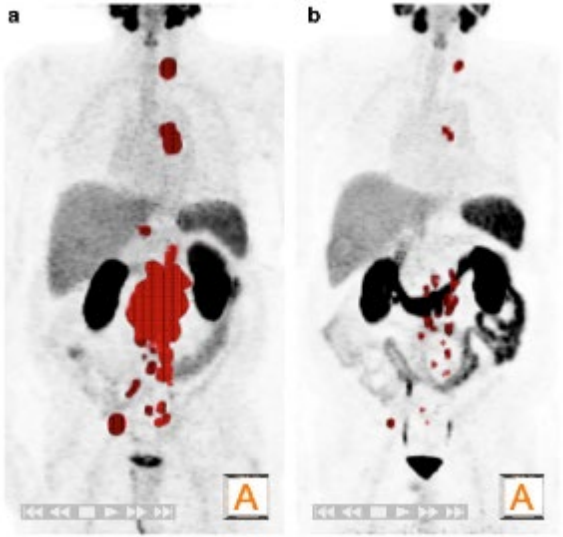

Take home messages



- Biochemisch herval
  - DR 80-90%, afhankelijk van PSA
  - ! Ken limitaties van de tracer
- Primaire staging
  - Accuraatheid PSMA PET > conventionele beeldvorming
  - ! Geen data over beleid / nood aan gestandaardiseerde rapportering
- Therapie-opvolging
  - Geen duidelijke criteria voor respons/progressie
  - ! Studies nodig vooraleer gebruik in klinische routine



Bedankt voor uw aandacht!