

Role of MR in prostate cancer

Dr. L. De Wever

Role of MR in prostate cancer?

MR in primary setting T (N and M)

MR in guiding prostate biopsies

MR in active surveillance of Pca

MR post therapy



Role of MR in prostate cancer?

MR in primary setting T (N and M)

MR in guiding prostate biopsies

MR in active surveillance of Pca

MR post therapy



Traditional pathway



Undersampling ⟶ underdiagnosis of clinically significant disease

Overdiagnosis of insignificant cancer ⟶ overtreatment

Traditional pathway is changing

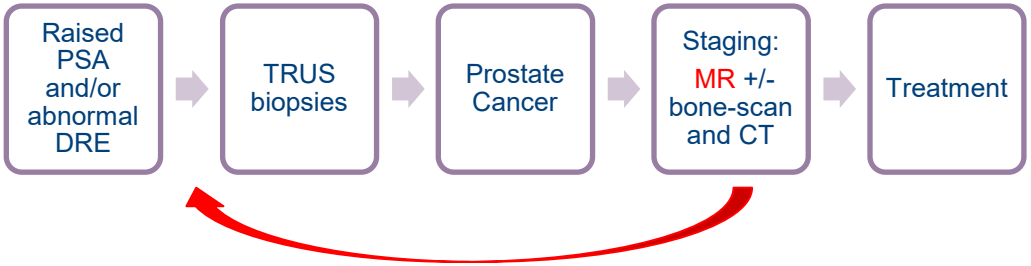

Undersampling ⟶ underdiagnosis of clinically significant disease

Overdiagnosis of insignificant cancer ⟶ overtreatment

Actual EAU guidelines place MR more upfront in the pathway

Supporting studies

PROMIS

THE LANCET
Volume 389, Issue 10071, 25 February–3 March 2017, Pages 815-822



Articles

Diagnostic accuracy of multi-parametric MRI and TRUS biopsy in prostate cancer (PROMIS): a paired validating confirmatory study

Hashim U Ahmed FRCS [a, b, *], Ahmed El-Shater Bosaily MBBCh [a, b, *], Louise C Brown PhD [d, *], Rhian Gabe PhD [e], Prof Richard Kaplan FRCP [d], Prof Mahesh K Parmar DPhil [d], Yolanda Collaco-Moraes PhD [d], Katie Ward BSc [d], Richard G Hindley FRCS [f], Alex Freeman FRCPath [g], Alex P Kirkham FRCR [h], Robert Oldroyd MA [i], Chris Parker FRCR [c], Prof Mark Emberton FRCS [a, b], PROMIS study group [†]

	MP-MRI, % (95% CI)	TRUS-biopsy, % [95% CI]	Test ratio*[95% CI]	p value
Primary definition (Gleason score ≥4+3 or cancer core length ≥6 mm), prevalence of clinically significant cancer 230 (40%, 36–44%)				
Sensitivity test	93 (88–96)	48 (42–55)	0·52 (0·45–0·60)	p<0·0001
Specificity test	41 (36–46)	96 (94–98)	2·34 (2·08–2·68)	p<0·0001
PPV	51 (46–56)	90 (83–94)	8·2 (4·7–14·3)	p<0·0001
NPV	89 (83–94)	74 (69–78)	0·34 (0·21–0·55)	p<0·0001

PRECISION

The NEW ENGLAND JOURNAL of MEDICINE

ORIGINAL ARTICLE

MRI-Targeted, Systematic, and Combined Biopsy for Prostate Cancer Diagnosis

M. Ahdoot, A.R. Wilbur, S.E. Reese, A.H. Lebastchi, S. Mehralivand, P.T. Gomella, J. Bloom, S. Gurram, M. Siddiqui, P. Pinsky, H. Parnes, W.M. Linehan, M. Merino, P.L. Choyke, J.H. Shih, B. Turkbey, B.J. Wood, and P.A. Pinto

MRI-FIRST

THE LANCET
Oncology
Volume 20, Issue 1, January 2019, Pages 100-109



Articles

Use of prostate systematic and targeted biopsy on the basis of multiparametric MRI in biopsy-naive patients (MRI-FIRST): a prospective, multicentre, paired diagnostic study

Prof Olivier Rouvière MD [a, h], Prof Philippe Puech MD [k, l], Prof Raphaële Renard-Penna MD [m], Prof Michel Claudon MD [n, o], Prof Catherine Roy MD [p], Florence Mège-Lechevallier MD [b], Myriam Decaussin-Petrucci MD [q, l], Marine Dubreuil-Chambardel PhD [a], Laurent Magaud PhD [r, s], Laurent Remontet MD [g, j, r], Prof Alain Ruffion MD [d, t], Prof Marc Colombel MD [c, h], Prof Sébastien Crouzet MD [c, h], Prof Anne-Marie Schott MD [f, q], Prof Laurent Lemaitre MD [k, l], Muriel Rabilloud MD [g, j, r], Prof Nicolas Grenier MD [t]
MRI-FIRST Investigators[†]

MRI-targeted biopsies resulted in

* fewer men needing biopsy
* more men with clinically significant cancer detected
* fewer men with clinically insignificant cancer detected

EUROPEAN UROLOGY 77 (2020) 78–94

available at www.sciencedirect.com
journal homepage: www.europeanurology.com

European Association of Urology



Review – Prostate Cancer

Prostate Magnetic Resonance Imaging, with or Without Magnetic Resonance Imaging-targeted Biopsy, and Systematic Biopsy for Detecting Prostate Cancer: A Cochrane Systematic Review and Meta-analysis

Frank-Jan H. Drost [a,b], Daniel Osses [a,b], Daan Nieboer [b,c], Chris H. Bangma [b], Ewout W. Steyerberg [c], Monique J. Roobol [b], Ivo G. Schoots [a,]*

EAU guidelines 2020

Recommendations in biopsy naïve patients	LE	Strength rating
Perform mpMRI before prostate biopsy.	1a	Strong
When mpMRI is positive (i.e. PI-RADS ≥ 3), combine targeted and systematic biopsy.	2a	Strong
When mpMRI is negative (i.e., PI-RADS ≤ 2), and clinical suspicion of prostate cancer is low, omit biopsy based on shared decision making with the patient.	2a	Weak

Recommendations in patients with prior negative biopsy	LE	Strength rating
Perform mpMRI before prostate biopsy.	1a	Strong
When mpMRI is positive (i.e. PI-RADS ≥ 3), perform targeted biopsy only.	2a	Weak
When mpMRI is negative (i.e., PI-RADS ≤ 2), and clinical suspicion of prostate cancer is high, perform systematic biopsy based on shared shared decision making with the patient.	2a	Strong

MRI pathway is better than systematic biopsies in making a correct diagnosis of clinically important prostate cancer and reducing redundant biopsies and the detection of unimportant cancers substantially.
However, MRI pathway still misses some men with important prostate cancer

PIRADS v2.1 (Prostate Imaging Reporting And Data System)

PI-RADS™ v2 Assessment Categories

PIRADS 1 – Very low (clinically significant cancer is highly unlikely to be present)

PIRADS 2 – Low (clinically significant cancer is unlikely to be present)

PIRADS 3 – Intermediate (the presence of clinically significant cancer is equivocal)

PIRADS 4 – High (clinically significant cancer is likely to be present)

PIRADS 5 – Very high (clinically significant cancer is highly likely to be present)

Mp-MRI with T2W, DWI and DCE

The scoring for T2W and DWI uses a 5-point scale, for DCE a 2-point scale is used

The scores of different sequences are not summated but there is a dominance of certain sequences according to zonal anatomy

For PZ, DWI is the primary determining sequence, for the TZ, T2w is the determining sequence

Role of DCE is limited

Table 1 – PI-RADS Assessment Category for the peripheral zone (PZ)

DWI	T2W	DCE	PI-RADS
1	Any*	Any	1
2	Any	Any	2
3	Any	–	3
		+	4
4	Any	Any	4
5	Any	Any	5

* "Any" indicates 1-5

Table 1 – PI-RADS v2.1 assessment for TZ

T2	DWI	DCE	Overall
1	Any	Any	1
2	<3	Any	2
	>4	Any	3
3	<4	Any	3
	5	Any	4
4	Any	Any	4
5	Any	Any	5

DCE = dynamic contrast enhanced; DWI = diffusion-weighted imaging; PI-RADS v2.1 = Prostate Imaging Reporting and Data System version 2.1; TZ = transition zone.

T2W

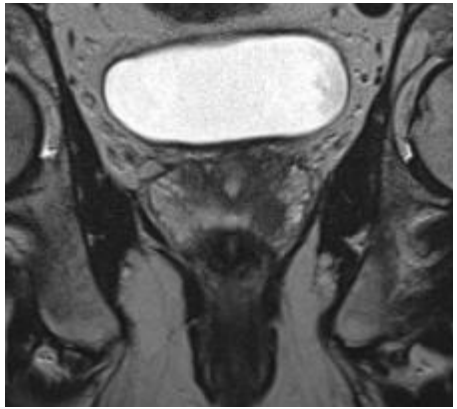

DWI

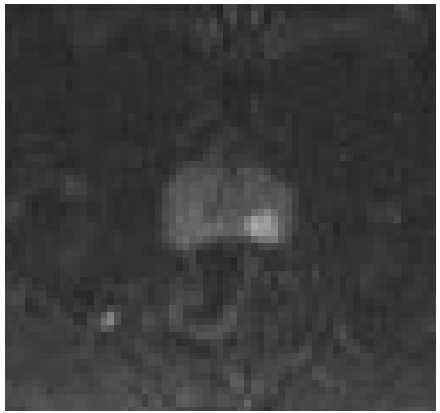

DCE

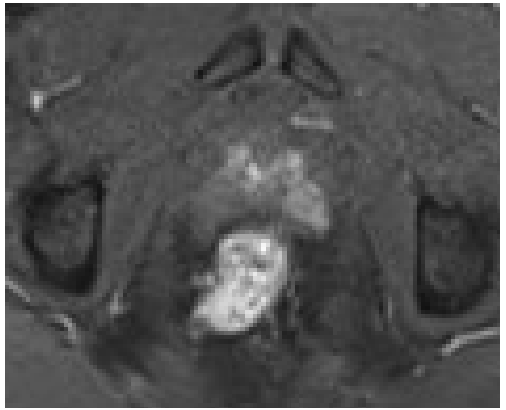

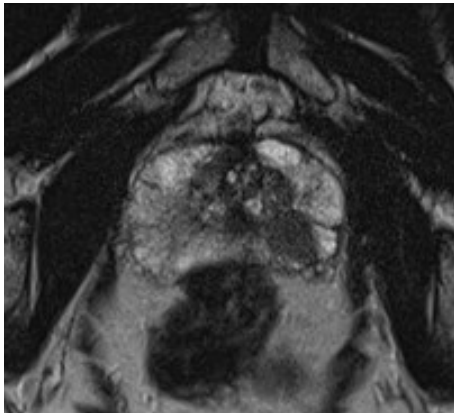



PIRADS 5
Gleason 4+3 tumor

T2W

DWI

DCE

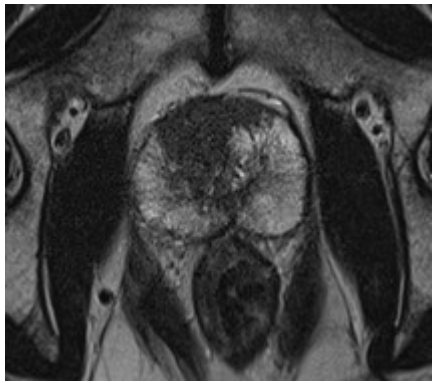

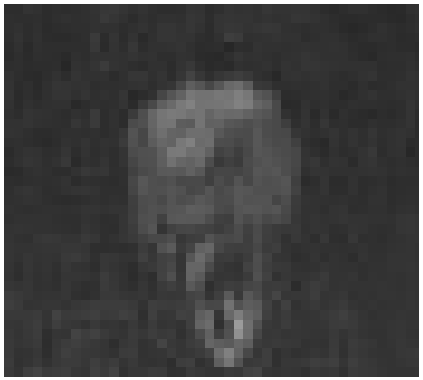

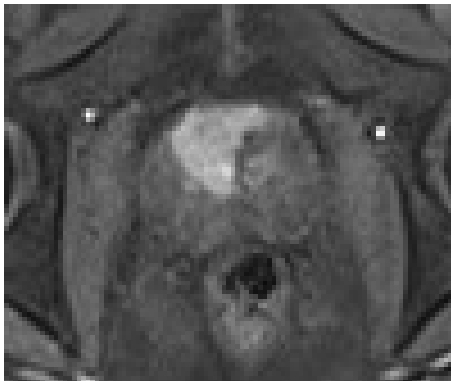

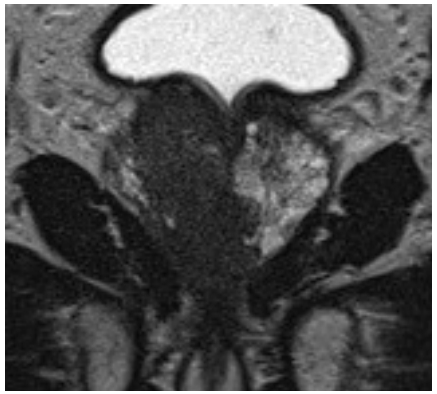



PIRADS 5
Gleason 4+5 tumor

T2W

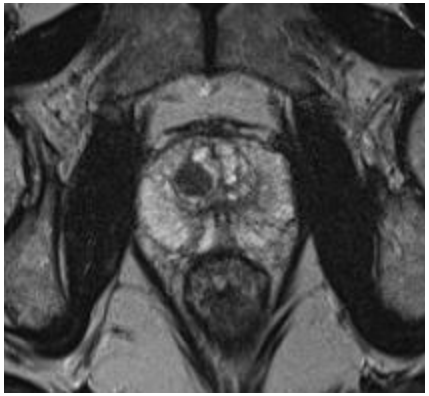

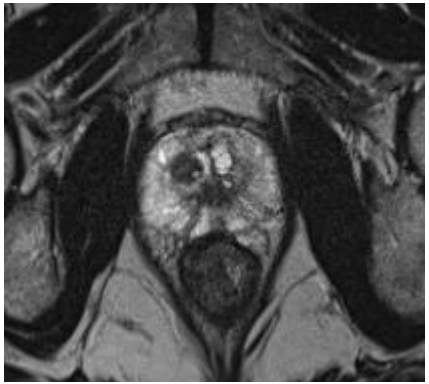

DWI

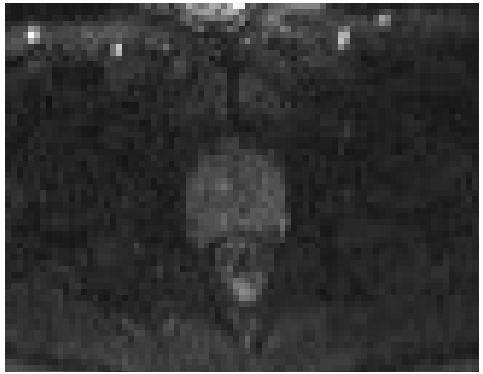

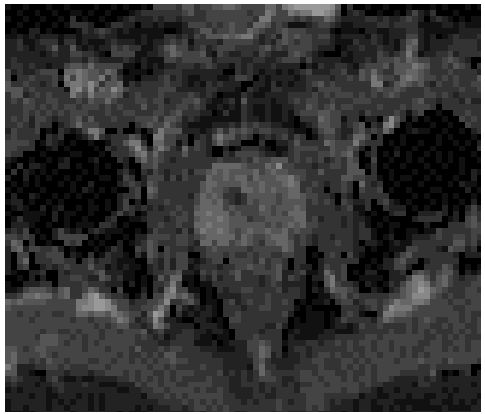

PIRADS 1
Stromal hyperplastic nodule TZ

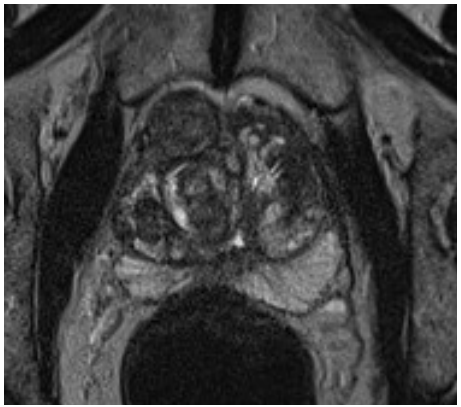

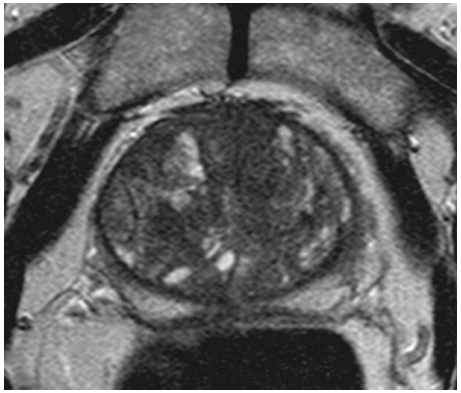







In PIRADS, dominant sequence for TZ is T2w but signal intensity on T2w depends on tissue composition

DWI



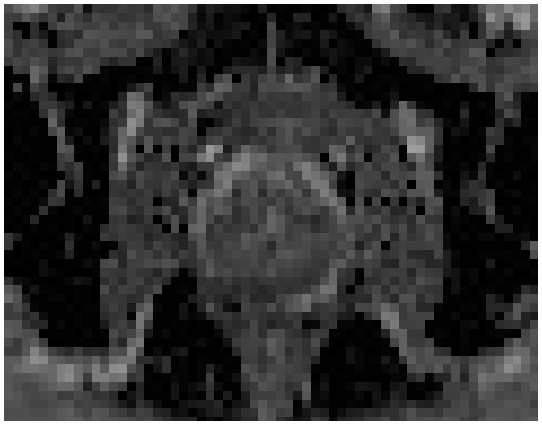

T2W

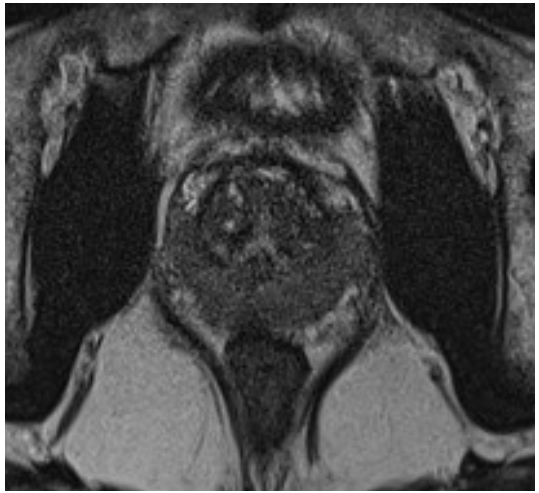

Chronic prostatitis
PIRADS 3 (4?)

T2W

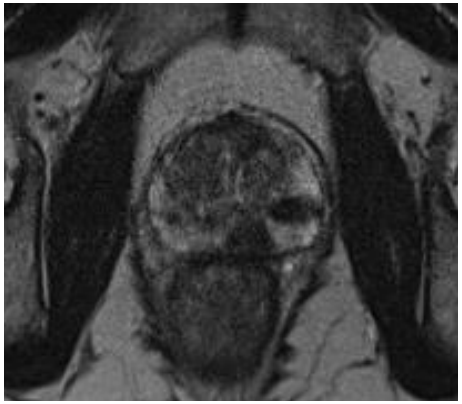

DWI

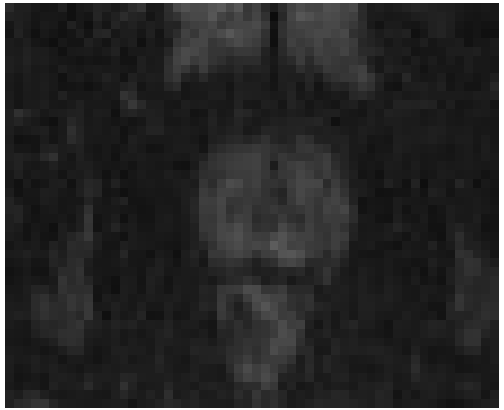

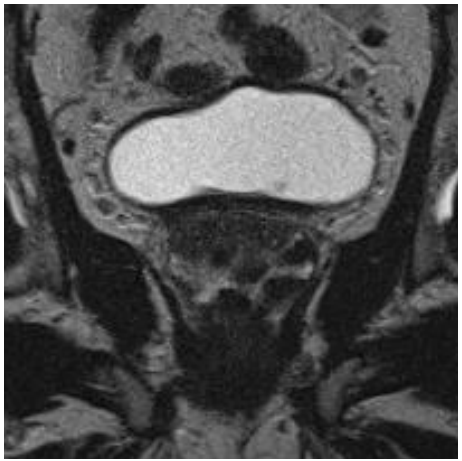

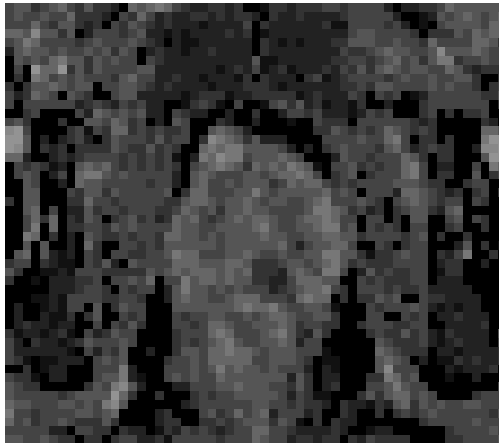

Granulomatous prostatitis post BCG
PIRADS (3?) 4

T2W

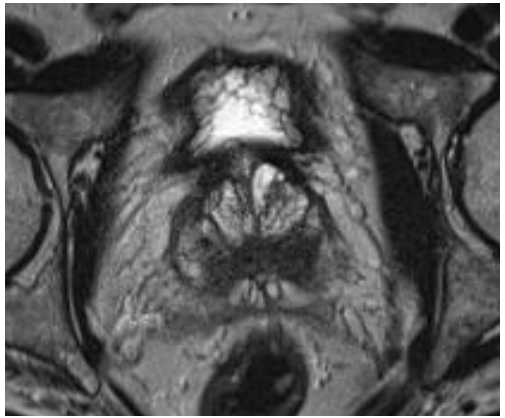

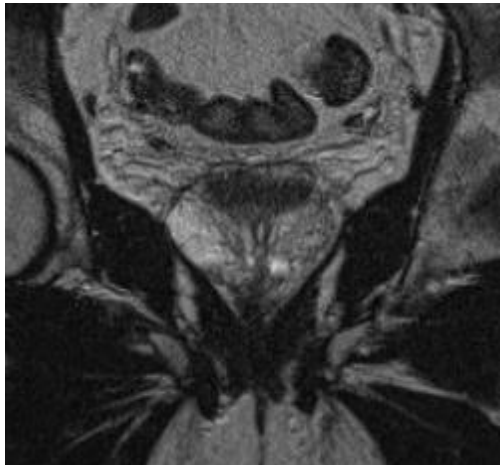

DWI





Central zone
PIRADS 1

T2W

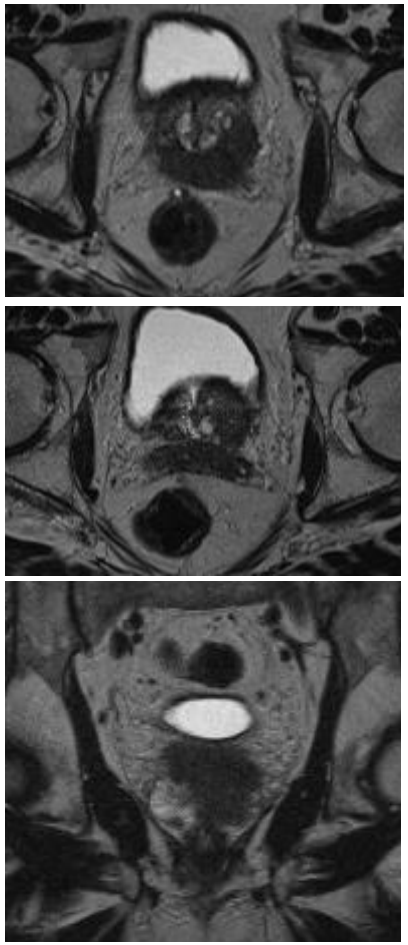

DWI

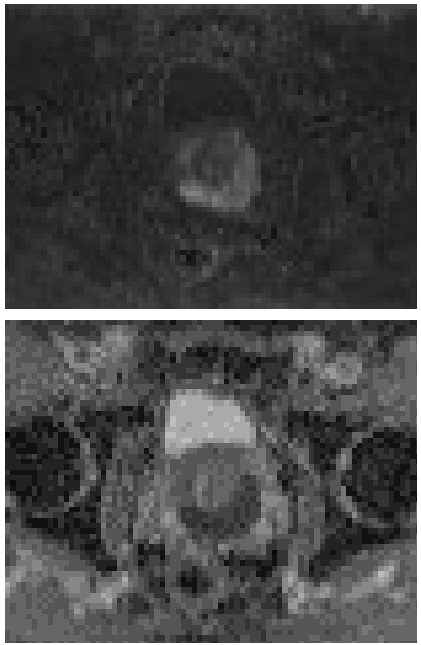

T3a+b tumor PIRADS 5
Gleason score 4+3 (and 5)

T-Staging of Pca on MR

EUROPEAN UROLOGY 70 (2016) 233–245

available at www.sciencedirect.com
journal homepage: www.europeanurology.com

European Association of Urology



Platinum Priority – Review – Prostate Cancer

Editorial by Anwar R. Padhani, Giuseppe Petralia and Francesco Sanguedolce on pp. 246–247 of this issue

Accuracy of Magnetic Resonance Imaging for Local Staging of Prostate Cancer: A Diagnostic Meta-analysis

*Maarten de Rooij *, Esther H.J. Hamoen, J. Alfred Witjes, Jelle O. Barentsz, Maroeska M. Rovers*

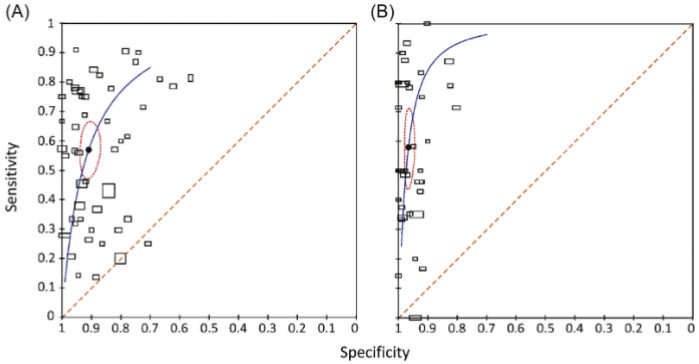

Fig. 3 – Hierarchic summary receiver operating characteristic plot (solid line) with summary point and 95% confidence interval area (circled area). The dashed line denotes the line of no discrimination (area under the curve of 0.5, meaning a worthless test). Squares denote data from individual studies included in meta-analysis for (A) extracapsular extension and (B) seminal vesicle invasion. The size of the squares corresponds to the relative size of the study population.

Conclusions: MRI has high specificity but poor and heterogeneous sensitivity for local PCa staging. An endorectal coil showed no additional benefit for ECE detection, but slightly improved sensitivity for SVI detection. Higher field strengths and the use of functional imaging techniques can slightly improve sensitivity.

N-Staging of Pca on MR

- Based on morphological criteria (size and shape)
- LN with a short axis > 8 mm in the pelvis and > 10 mm outside the pelvis are considered malignant
- MR (and CT) show a sensitivity of 40% and specificity of 80%
- DWI on MR? metastatic LN seem to have lower ADCvalues compared with benign LN but the overlap is substantial
- MR lymphography (USPIO)
- … (gadofosveset-enhanced MR)



M-staging of Pca on MR (bone)

- Bone metastasis ⟶ marrow infiltration/replacement
- Whole-body MRI superiority over bone scan has been widely demonstrated, cfr meta-analyse by Shen in which WB-MRI was found to be more sensitive (97%) than BS (79%) in the detection of skeletal metastasis

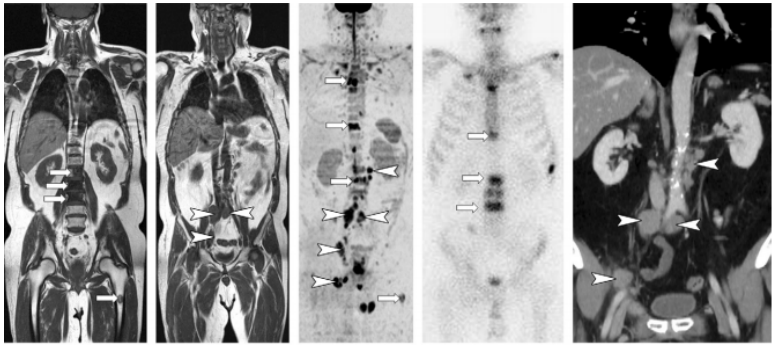

Whole-body MR imaging: musculoskeletal applications, Lecouvet, Radiology 2016

Skeletal Radiol (2014) 43:1503–1513
DOI 10.1007/s00256-014-1903-9

REVIEW ARTICLE

Comparison of choline-PET/CT, MRI, SPECT, and bone scintigraphy in the diagnosis of bone metastases in patients with prostate cancer: a meta-analysis

Guohua Shen · Houfu Deng · Shuang Hu · Zhiyun Jia

EAU guidelines 2020

5.3.4. Summary of evidence and practical considerations on initial N/M staging

The field of non-invasive nodal and metastatic staging of PCa is evolving very rapidly. Evidence shows that choline PET/CT, PSMA PET/CT and MRI provide a more sensitive detection of LN and bone metastases than the classical work-up with bone scan and abdominopelvic CT. It could be tempting to conclude that bone scan and abdominopelvic CT must be replaced by more sensitive tests in all patients undergoing initial PCa staging. Yet, the clinical benefit of detecting metastases at an earlier time-point remains unclear [325]. In addition the prognosis and ideal management of patients diagnosed as metastatic by these more sensitive tests is unknown. In particular, it is unclear whether patients with metastases, detectable only with PET/CT or MRI, should be managed using systemic therapies, or whether they should be subjected to aggressive local and metastases-directed therapies [345].

Results from RCTs evaluating the management and outcome of patients with (and without) metastases detected by choline PET/CT, PSMA PET/CT and MRI are awaited, before a decision can be made to treat patients based on the results of these tests [346].

5.3.5. Guidelines for staging of prostate cancer

Any risk group staging	**LE**	**Strength rating**
Use pre-biopsy mpMRI for local staging information.	2a	Weak
Low-risk localised disease		
Do not use additional imaging for staging purposes.	2a	Strong
Intermediate-risk disease		
In ISUP grade ≥ 3, include at least cross-sectional abdominopelvic imaging and a bone-scan for metastatic screening.	2a	Weak
High-risk localised disease/locally advanced disease		
Perform metastatic screening including at least cross-sectional abdominopelvic imaging and a bone-scan.	2a	Strong

Role of MR in prostate cancer?

MR in primary setting T (N and M)

MR in guiding prostate biopsies

MR in active surveillance of Pca

MR post therapy



MR in guiding biopsies

- In-bore MR-guided biopsies
- Cognitive fusion biopsies
- MR-TRUS (software based) fusion biopsies



Cognitive fusion biopsy

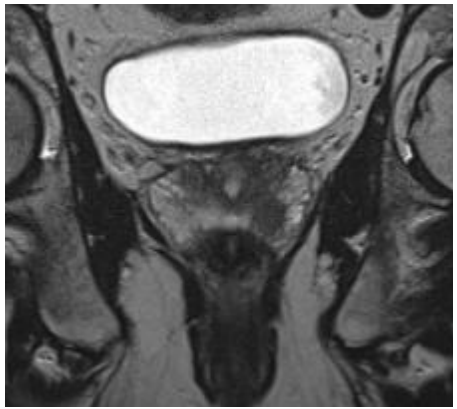
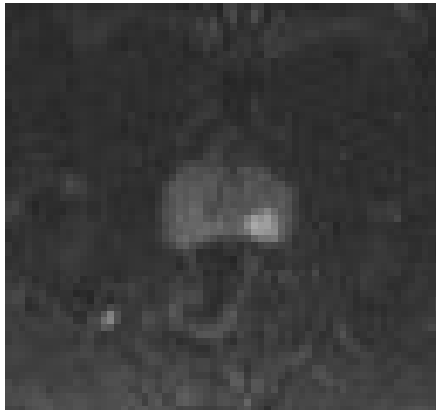
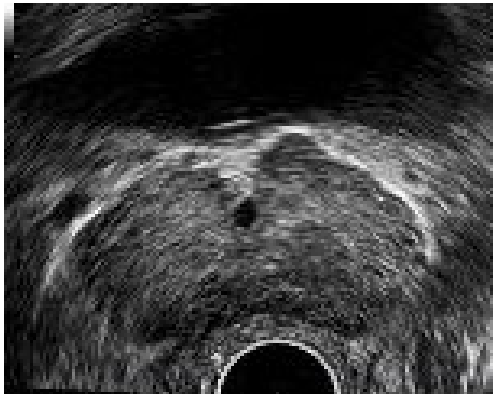
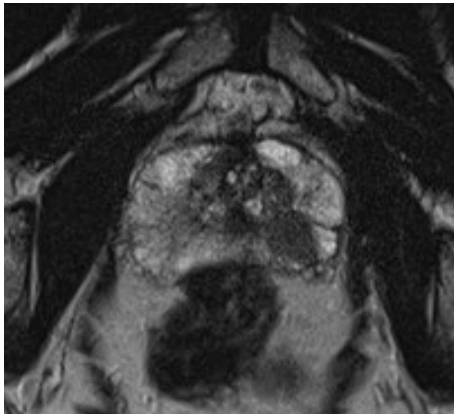

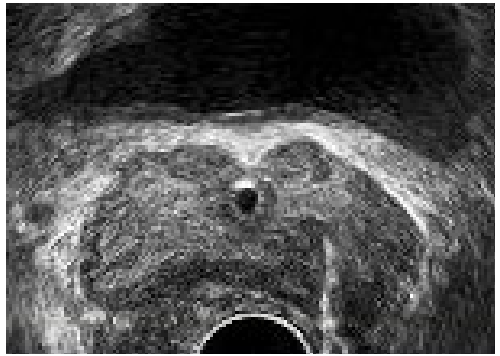

Cognitive fusion biopsy

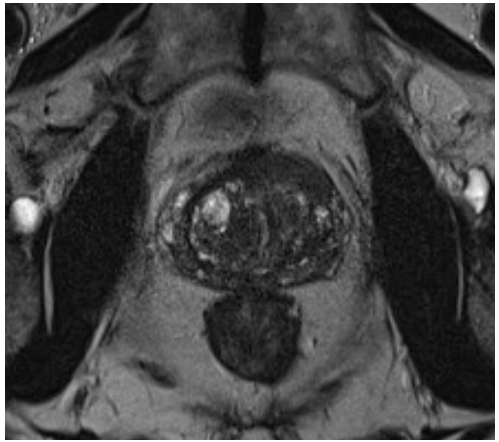

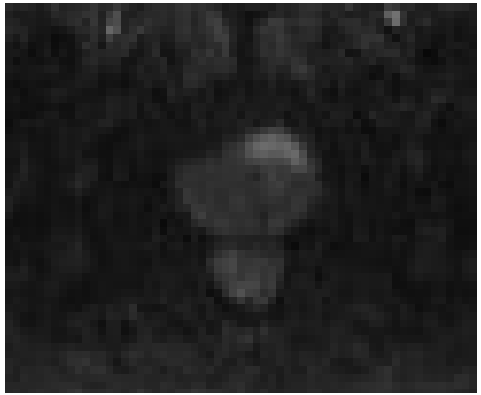



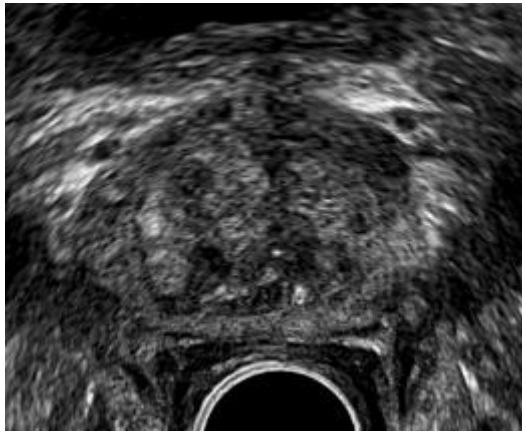

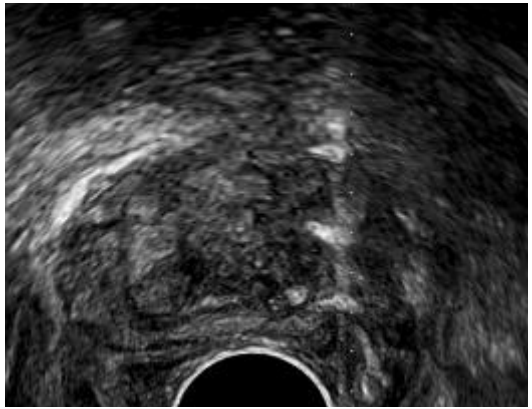

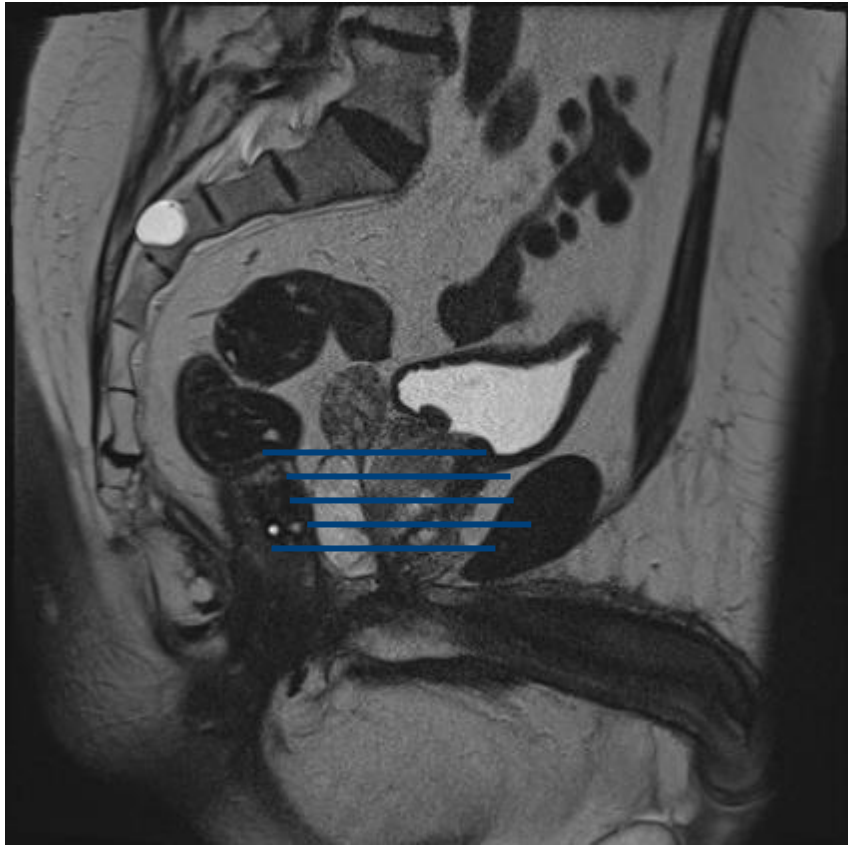

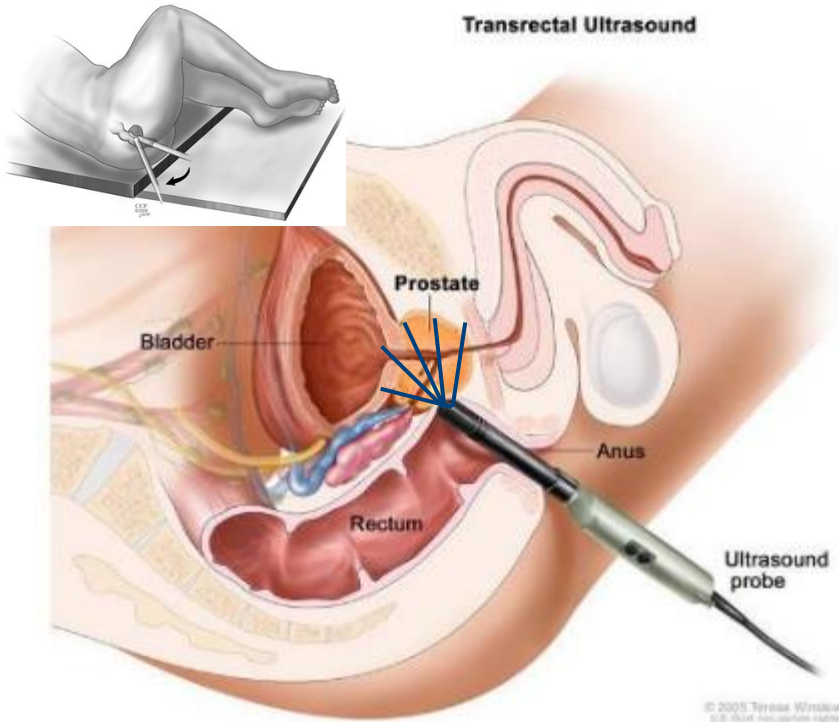
Transrectal Ultrasound
Prostate
Bladder
Anus
Rectum
Ultrasound probe

MR-TRUS (software based) fusion biopsies

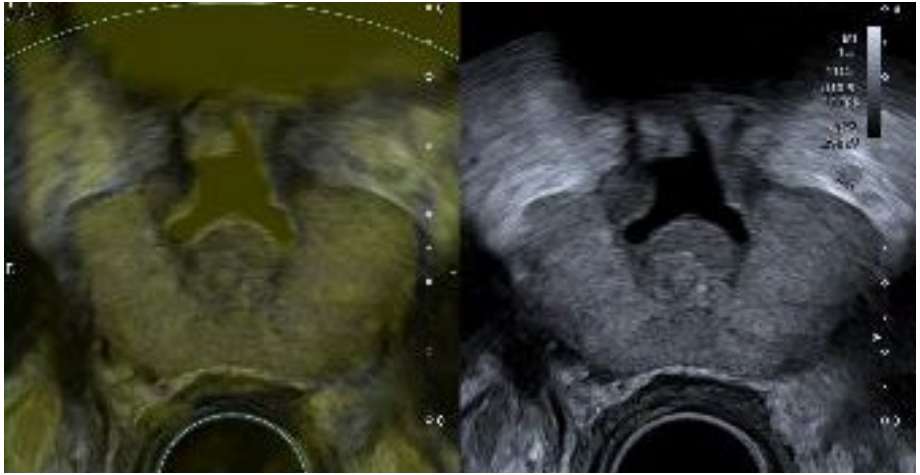

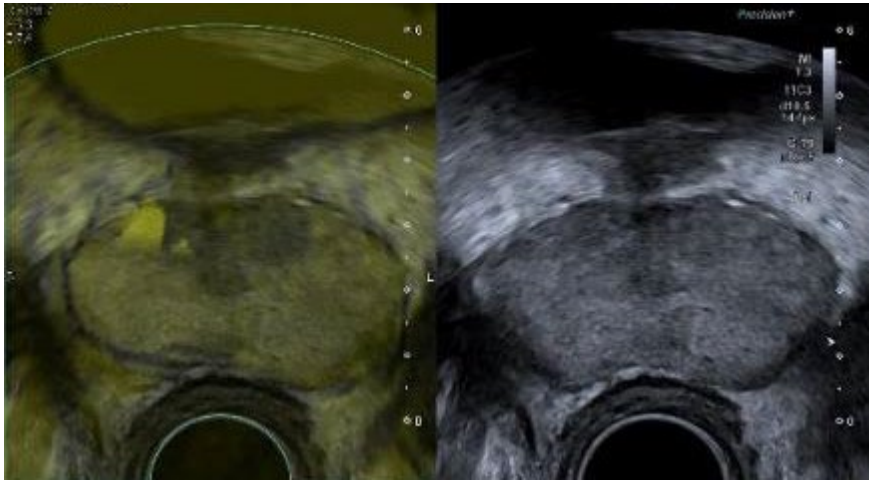

MR-TRUS (software based) fusion biopsies

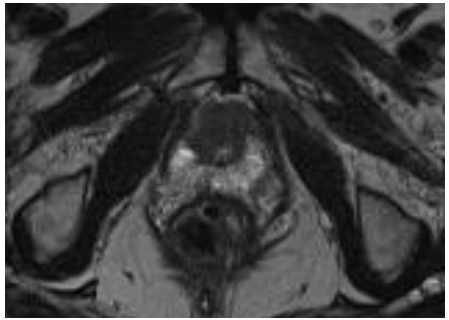



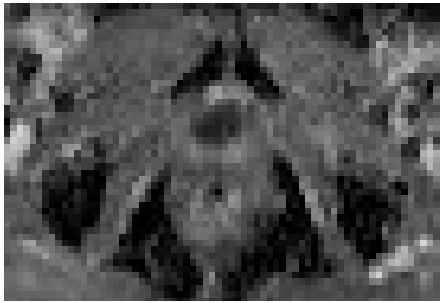

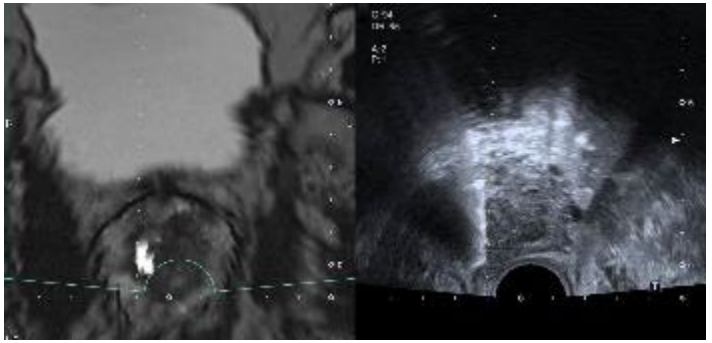

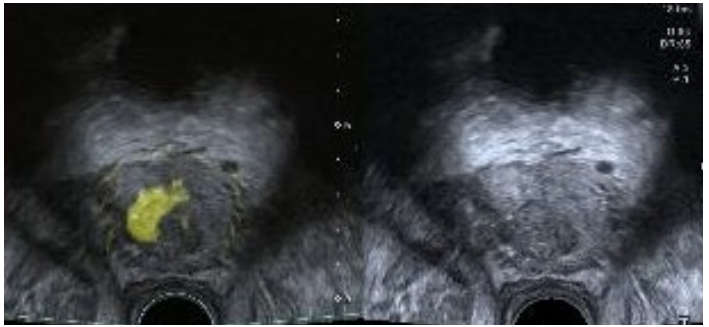

MR-TRUS (software based) fusion biopsies

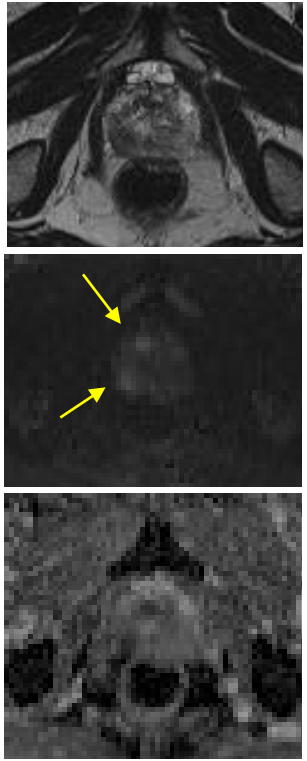





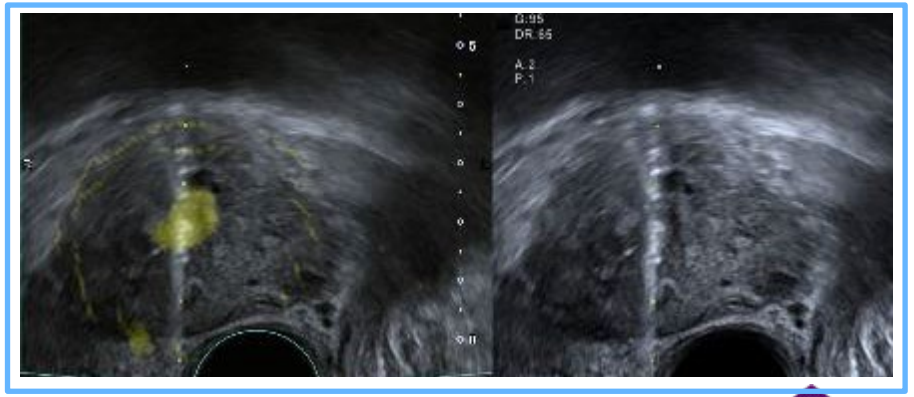

Role of MR in prostate cancer?

MR in primary setting T (N and M)

MR in guiding prostate biopsies

MR in active surveillance of Pca

MR post therapy



MR in active surveillance of Pca

- Is this man eligible for AS? Possibly upgrading?
- Follow up of AS patients and triggering or omitting?? of rebiopsies

Active surveillance (AS)	
Offer AS to patients with a life expectancy > 10 years and low-risk disease.	Strong
If a patient has had upfront multiparametric magnetic resonance imaging (mpMRI) followed by systematic and targeted biopsies there is no need for confirmatory biopsies.	Weak
Patients with intraductal and cribiform histology on biopsy should be excluded from AS.	Strong
If required perform mpMRI before a confirmatory biopsy.	Strong
Take both targeted biopsy (of any PI-RADS ≥ 3 lesion) and systematic biopsy if a confirmatory biopsy is performed.	Strong
Perform serum prostate-specific antigen (PSA) assessment every 6 months.	Strong
Perform digital rectal examination (DRE) every 12 months.	Strong
Repeat biopsy should be performed if there is evidence of PSA progression, clinical progression on DRE or radiological progression on mpMRI.	Strong
During follow-up, if mpMRI is negative (i.e., PI-RADS ≤ 2), and clinical suspicion of PCa progression is low (e.g. low PSA velocity, long PSA doubling time), omit biopsy based on shared decision making with the patient.	Weak
Counsel patients about the possibility of needing further treatment in the future.	Strong

Role of MR in prostate cancer?

MR in primary setting T (N and M)

MR in guiding prostate biopsies

MR in active surveillance of Pca

MR post therapy



MR after radical prostactomy

different anatomy
+/- surgical clips
+/- fibrosis
+/- granulation tissue
residual prostate tissue?

Impact on T2, DWI en DCE

Sensitivity of MR for the detection of local recurrence varies 80-92% and specificity 75%

DCE most useful sequence for detecting recurrence

Local recurrence after radical prostatectomy

Choline PETCT

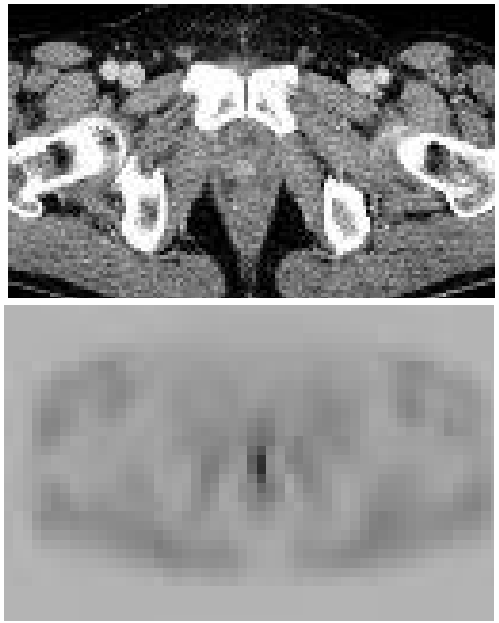

T2W

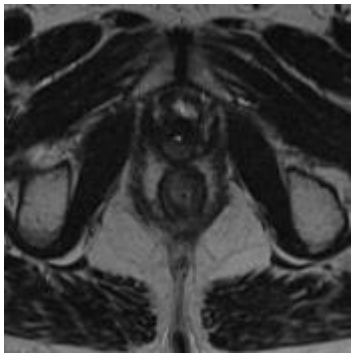

DWI

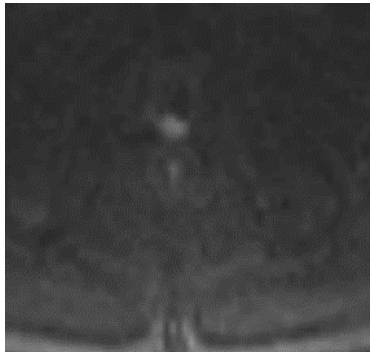

DCE

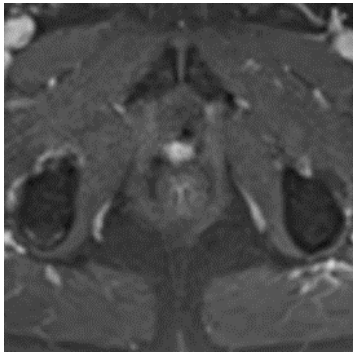

MR after radiotherapy

Irradiated prostate shrinks in size

Different signal pattern on T2W (diffuse hypointens)

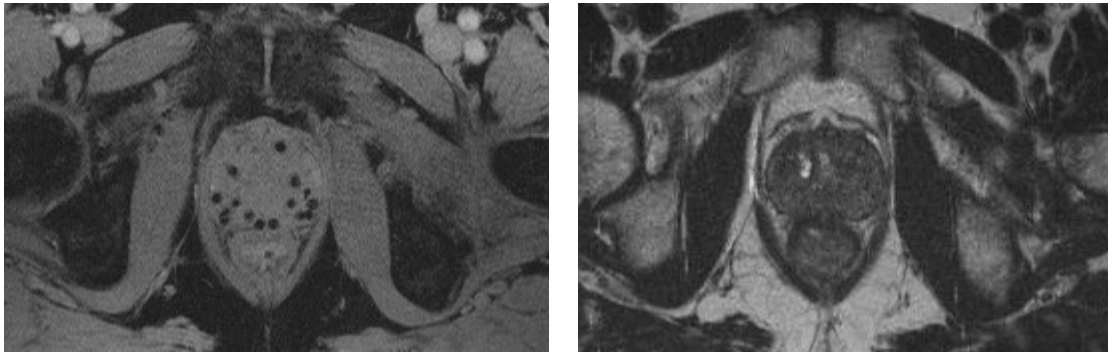

DWI and DCE appearance of the prostate is impacted as well, however, are not as drastic as on T2W

MR after radiotherapy

Irradiated prostate shrinks in size

Different signal pattern on T2W (diffuse hypointens)

DWI and DCE appearance of the prostate is impacted as well, however, are not as drastic as on T2W

! Also hormonal therapy can cause changes on T2W, DWI and DCE and reduces sensitivity for detection of recurrence

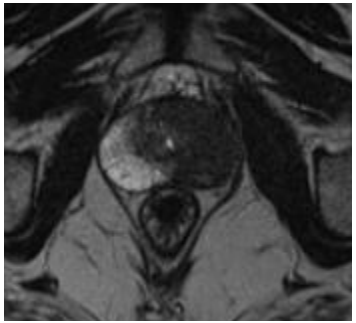

Tumor pre-HT

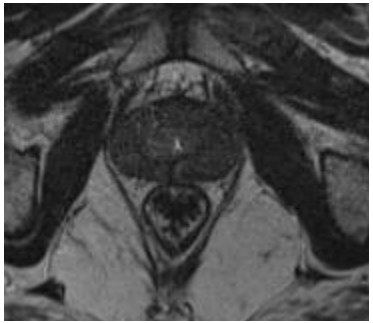

Tumor during HT

Local recurrence after brachytherapy

PSMA PETCT

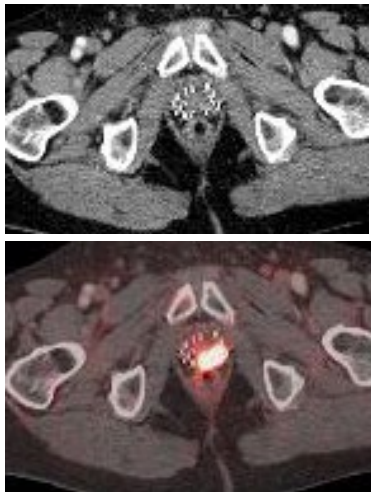

T2W

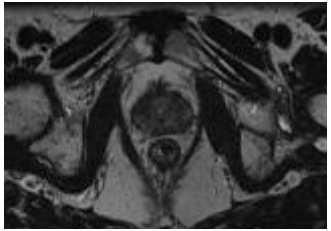

DWI



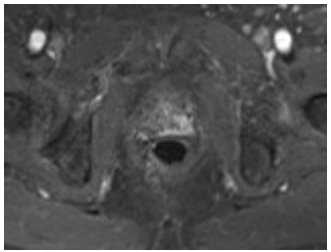

DCE

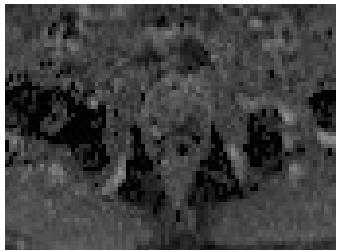

US

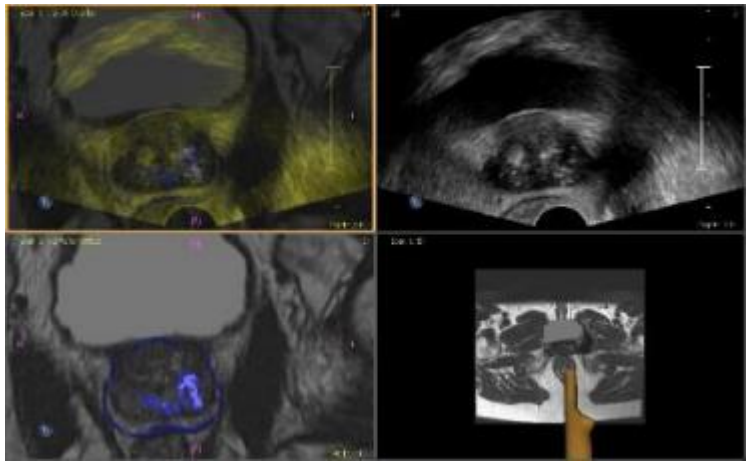

Role of MR in prostate cancer?

MR in primary setting T (N and M)

MR in guiding prostate biopsies

MR in active surveillance of Pca

MR post therapy

….



Thank you for your attention



PROMIS

Prospective multicenter study assessed MRI and systematic biopsy against template prostate mapping biopsy in biopsy-naïve men

	MP-MRI, % (95% CI)	TRUS-biopsy, % [95% CI]	Test ratio* [95% CI]	p value
Primary definition (Gleason score ≥4+3 or cancer core length ≥6 mm), prevalence of clinically significant cancer 230 (40%, 36–44%)				
Sensitivity test	93 (88–96)	48 (42–55)	0·52 (0·45–0·60)	p<0·0001
Specificity test	41 (36–46)	96 (94–98)	2·34 (2·08–2·68)	p<0·0001
PPV	51 (46–56)	90 (83–94)	8·2 (4·7–14·3)	p<0·0001
NPV	89 (83–94)	74 (69–78)	0·34 (0·21–0·55)	p<0·0001

MRI is superior to TRUS-biopsy in the detection of clinically significant cancer

Using MRI to triage men might allow 27% of patients avoid a primary biopsy

! No targeted biopsy

PRECISION

Prospective multicentre study randomly assigned biopsy-naïve men to

- systematic biopsy without MRI
- prebiopsy MRI with no biopsy when MR was negative
  only targeted biopsy when MR was positive

MRI-targeted biopsies resulted in

* fewer men needing biopsy
* more men with clinically significant cancer detected
* fewer men with clinically insignificant cancer detected

! Men with negative MR – no biopsy and omission of systematic biopsies

MRI-FIRST

Prospective multicenter study, every men had an MRI first and

- When MR was negative, systematic biopsy
- When MR was positive, systematic + targeted biopsy

	ISUP grade group ≥2 (csPCa-A)	ISUP grade group ≥2 or ISUP grade group 1 with MCCL ≥6 mm (csPCa-B)	ISUP grade group ≥3 (csPCa-C)
Systematic biopsy	29·9% (24·3–36·0)	32·7% (26·9–38·9)	15·1% (10·9–20·2)
Targeted biopsy	32·3% (26·5–38·4)	35·9% (29·9–42·1)	19·9% (15·2–25·4)
Systematic biopsy and targeted biopsy	37·5% (31·4–43·8)	41·8% (35·7–48·2)	21·1% (16·2–26·7)
Added value of systematic biopsy*	5·2% (2·8–8·7)	6·0% (3·4–9·7)	1·2% (0·2–3·5)
Added value of targeted biopsy†	7·6% (4·6–11·6)	9·2% (5·9–13·4)	6·0% (3·4–9·7)
p value‡	0·38	0·26	0·0095

Addition of MRI information does improve the detection of clinically significant Pca and systematic biopsy could be omitted only for detection of ISUP grade group ≥ 3