Leuven, 28 mei 2020

Bloedingsproblemen vóór de menopauze: ervaringen van de UZ-bloedingskliniek

Thierry Van den Bosch

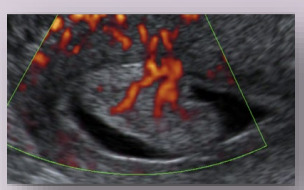

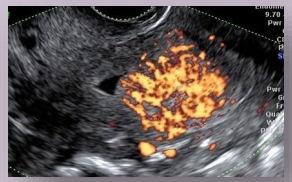
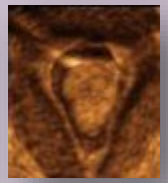

Abnormal uterine bleeding

Received: 18 May 2018 | Revised: 23 July 2018 | Accepted: 6 September 2018 | First published online: 10 October 2018
DOI: 10.1002/ijgo.12666

FIGO SPECIAL ARTICLE
Gynecology

WILEY

The two FIGO systems for normal and abnormal uterine bleeding symptoms and classification of causes of abnormal uterine bleeding in the reproductive years: 2018 revisions

Malcolm G. Munro[1,2,*] | Hilary O.D. Critchley[3] | Ian S. Fraser[4] | for the FIGO Menstrual Disorders Committee

Causes



Prof Johan Verhaeghe

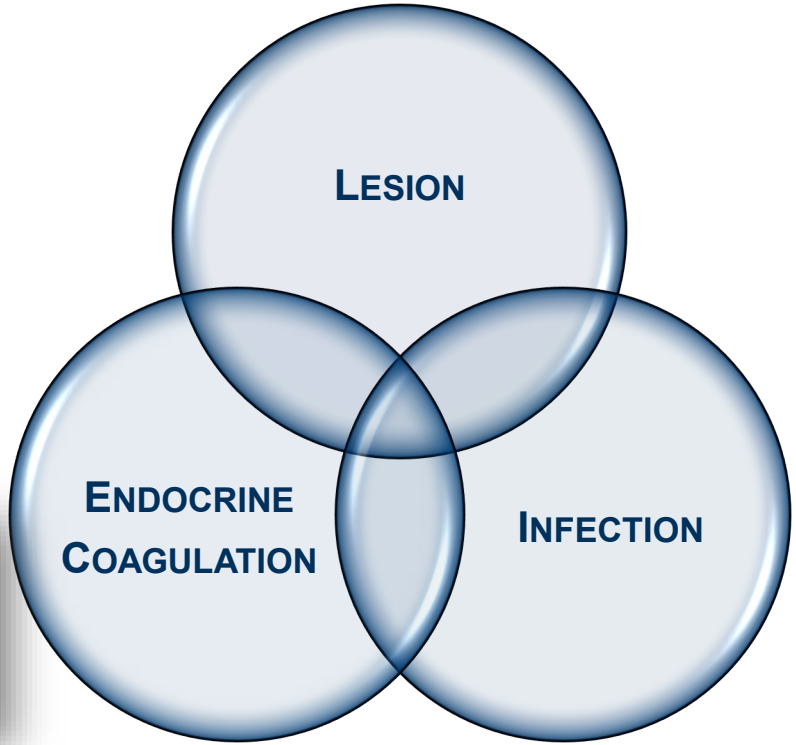



Diagnostic algorithm

ABNL BLEEDING

?

OVARIES | MYOMETRIUM | ENDOMETRIUM | BLADDER | RECTUM

UTERINE				EXTRA-uterine			
INTRA-cavitary		EXTRA- cavitary		GYNECOLOGICAL		NON-gynecological	
FOCAL	DIFFUSE	CERVIX	MYOMETRIUM	LOWER GEN TR	INTRA-ABDOM	URO	INTESTINAL

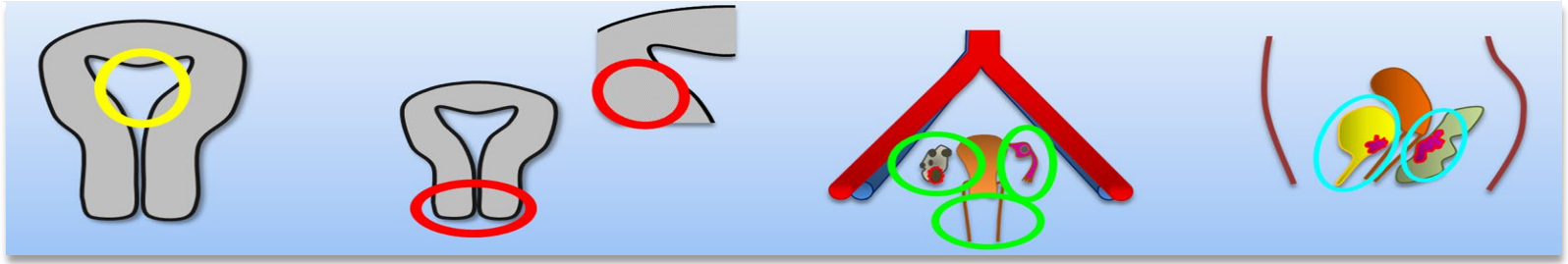



ABNL BLEEDING

?

Diagnostic algorithm

OVARIES

MYOMETRIUM

ENDOMETRIUM

BLADDER

RECTUM

MYOMA

ADENOMYOSIS

SARCOMA



dr Wouter Froyman

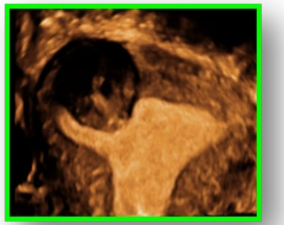

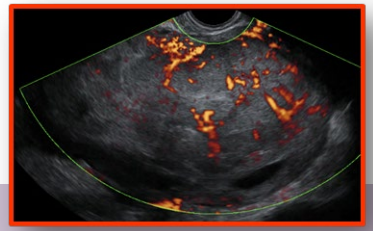



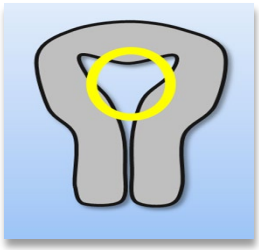

ABNL BLEEDING*

?

Diagnostic algorithm

OVARIES | MYOMETRIUM | ENDOMETRIUM | BLADDER | RECTUM

Proliferative | Secretory | Atrophy | Hyperplasia | Polyp | Myoma | Carcinoma



* NIET zwangerschapsgebonden

Abnormal uterine bleeding: Histology

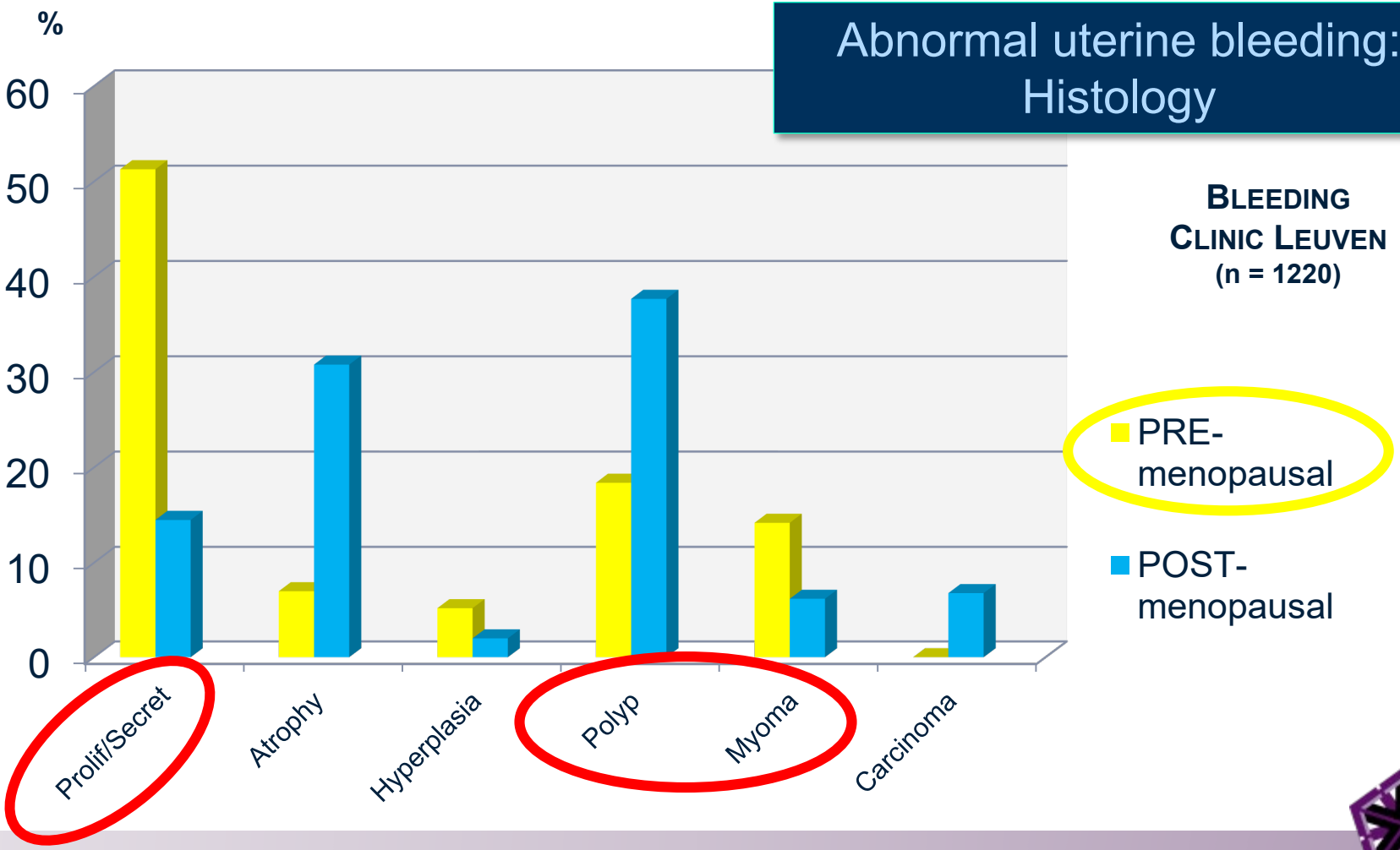

Van den Bosch T, et al. Facts Views Vis Obgyn. 2015;7(1):17-24

Historical perspective



The Fallacy of Simple Uterine Curettage

BUFORD WORD, M.D., L. CLARK GRAVLEE, M.D., and GILDER L. WIDEMAN, M.D.




I. CURETTAGE DE L'UTÉRUS

Instrumentation. — Elle doit, avant tout, être simple. Nous

Curette à tige droite de Volkmann. Curette à bords parallèles de Récamier-Pozzi.

Curette de Bouilly. Curette tranchante de Sims.

Fig. 95.

Proust R. Chirurgie de l'appareil génital de la femme. Masson et Cie Eds., Paris, 1918, p 83.

- Blind procedure
- General anesthesia
- Missed (focal) lesions

10 – 45%

Word et al. Obstet Gynecol 1958;12:642-8.

Epstein et al. Acta Obstet Gynecol Scand 2001;80:1131-6.

Office sampling





Meta-analysis

Failure rate n (%)	Inadequate rate n (%)	Cancer in inadequate samples n (%)	LR+ (95% CI) for cancer	LR- (95% CI) for cancer
68/1013 (7)	138/945 (15)	1 (0.7)	66.5 (30.0-147.1)	0.14 (0.1-0.3)

Clark et al. BJOG 2002;109:313-21

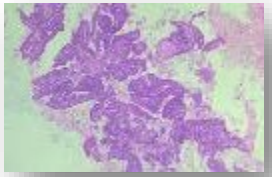

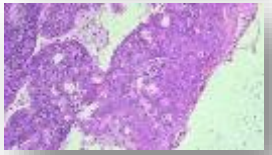

Meta-analysis



Pipelle	Postmenopausal	Premenopausal
Detection rate for endometrial carcinoma	99.6%	91.0%

Dijkhuizen FPHJ, et al. Cancer 2000;89:1765-72

Office sampling



	Sensitivity	Specificity	PPV	NPV
Disease*	44.6	98.5	96.1	69.0
Carcinoma	100.0	99.1	85.7	100.0

* disease = polyp, hyperplasia, cancer

Van den Bosch T, et al. Obstet Gynecol 1995;85:349-52

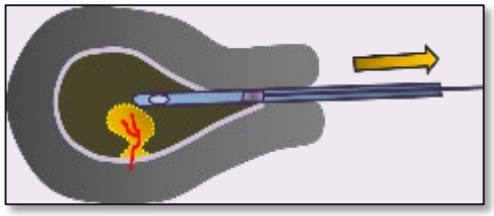

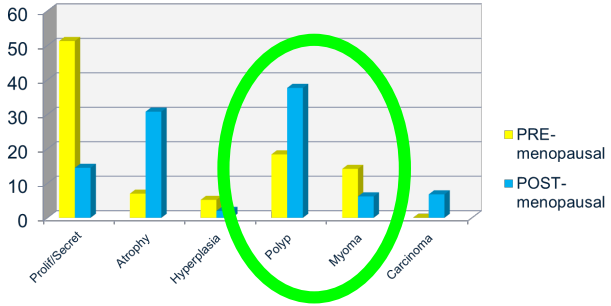

Van den Bosch T, et al. Facts Views Vis Obgyn. 2015;7(1):17-24

Hysteroscopy



Meta-analysis

	LR+ (95% CI)	LR- (95% CI)
for endometrial cancer	60.9 (51.2-72.5)	0.15 (0.13-1.18)
for endometrial "disease"*	10.4 (9.7-11.1)	0.24 (0.22-0.25)

Failure rate: 3.6% (3.3-3.8%)



* **Endometrial cancer or hyperplasia**

Clark et al. JAMA 2002;288:1610-21.



Office sampling

LR+ (95% CI) for cancer	LR- (95% CI) for cancer
66.5 (30.0-147.1)	0.14 (0.1-0.3)

Clark et al. BJOG 2002;109:313-21

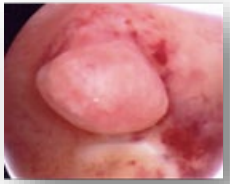

Ultrasonography





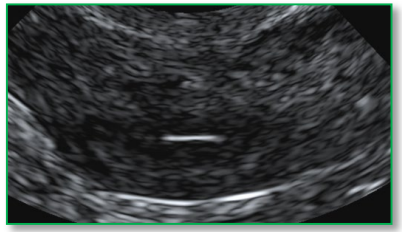



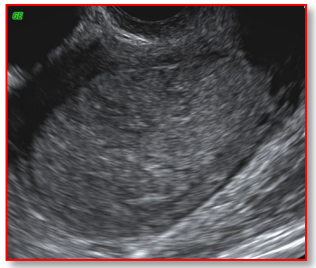

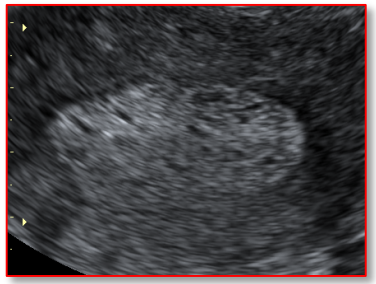



Endometrial thickness !

Meta-analysis

Endometrial thickness

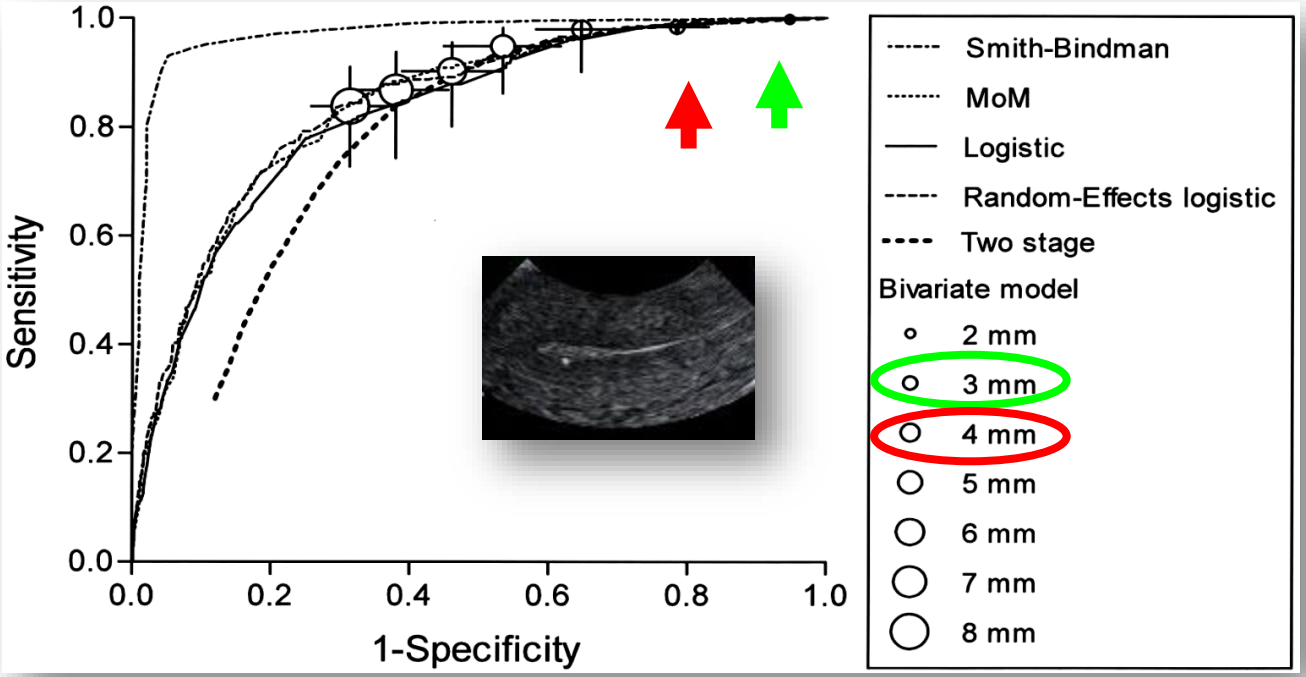

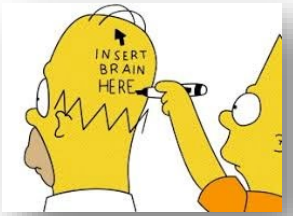

Endometrial Thickness Measurement for Detecting Endometrial Cancer in Women With Postmenopausal Bleeding: A Systematic Review and Meta-Analysis

Timmermans, Anne MD; Opmeer, Brent C. PhD; Khan, Khalid S. MD, PhD; Bachmann, Lucas M. PhD; Epstein, Elisabeth MD, PhD; Clark, T. Justin MD, PhD; Gupta, Janesh K. MD, PhD; Bakour, Shagaf H. MD, PhD; van den Bosch, Thierry MD, PhD; van Doorn, Helena C. MD, PhD; Cameron, Sharon T. MD; Giusa, M. Gabriella MD; Dessole, Stefano MD, PhD; Dijkhuizen, F. Paul H. L. J. MD, PhD; ter Riet, Gerben MD, PhD; Mol, Ben W. J. MD, PhD

Obstetrics & Gynecology: July 2010 - Volume 116 - Issue 1 - p 160-167

Ultrasound Obstet Gynecol 2010; 35: 103–112
Published online 15 December 2009 in Wiley InterScience (www.interscience.wiley.com). DOI: 10.1002/uog.7487

Terms, definitions and measurements to describe the sonographic features of the endometrium and intrauterine lesions: a consensus opinion from the International Endometrial Tumor Analysis (IETA) group

F. P. G. LEONE*, D. TIMMERMAN†, T. BOURNE‡, L. VALENTIN§, E. EPSTEIN¶, S. R. GOLDSTEIN**, H. MARRET††, A. K. PARSONS‡‡, B. GULL§§, O. ISTRE¶¶, W. SEPULVEDA***, E. FERRAZZI††† and T. VAN DEN BOSCH†



Qualitative assessment
‘**uniform**’ endometrial echogenicity

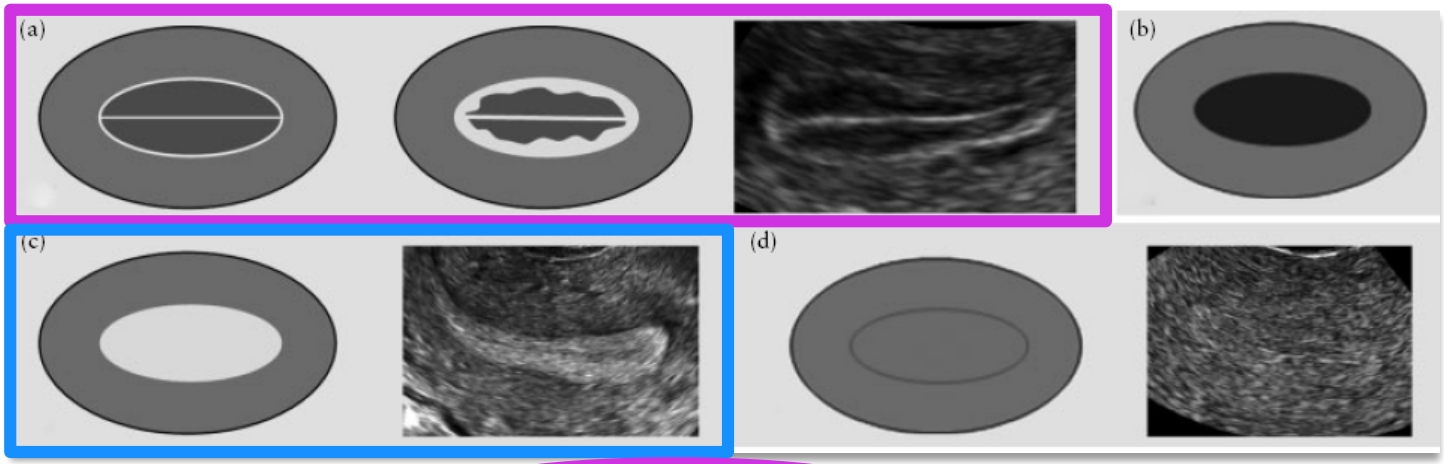

a. **Three-layer** pattern
b. **Hypo**echogenic
c. **Hyper**echogenic
d. **Iso**echogenic

Qualitative assessment
Endometrial midline

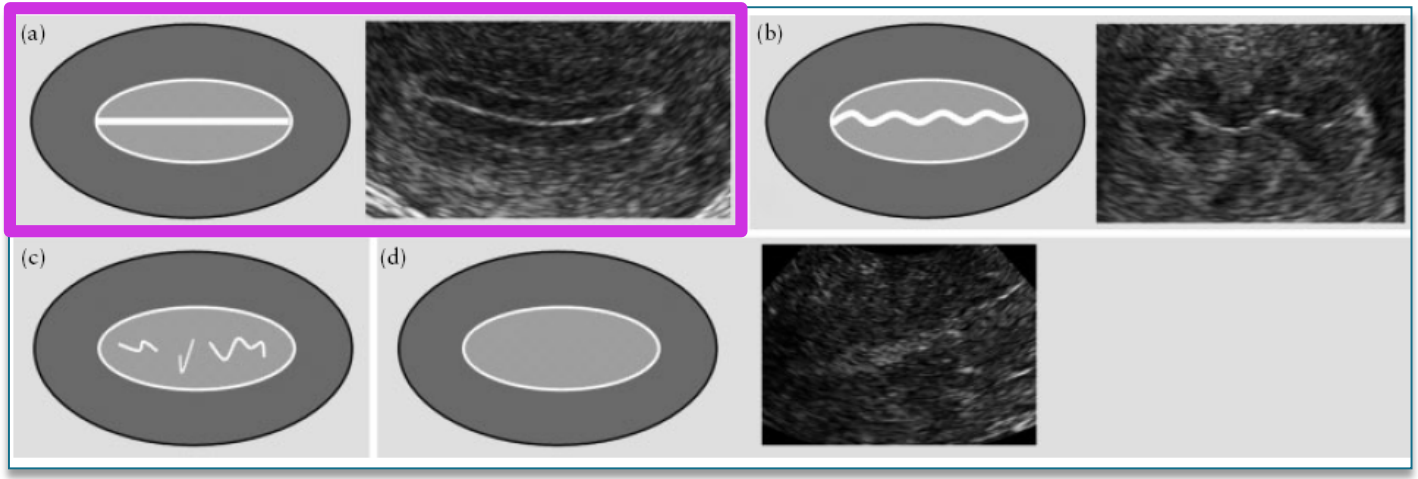

a. Linear
b. Non-linear
c. Irregular
d. Not defined

Color Doppler assessment of the endometrium
Color score

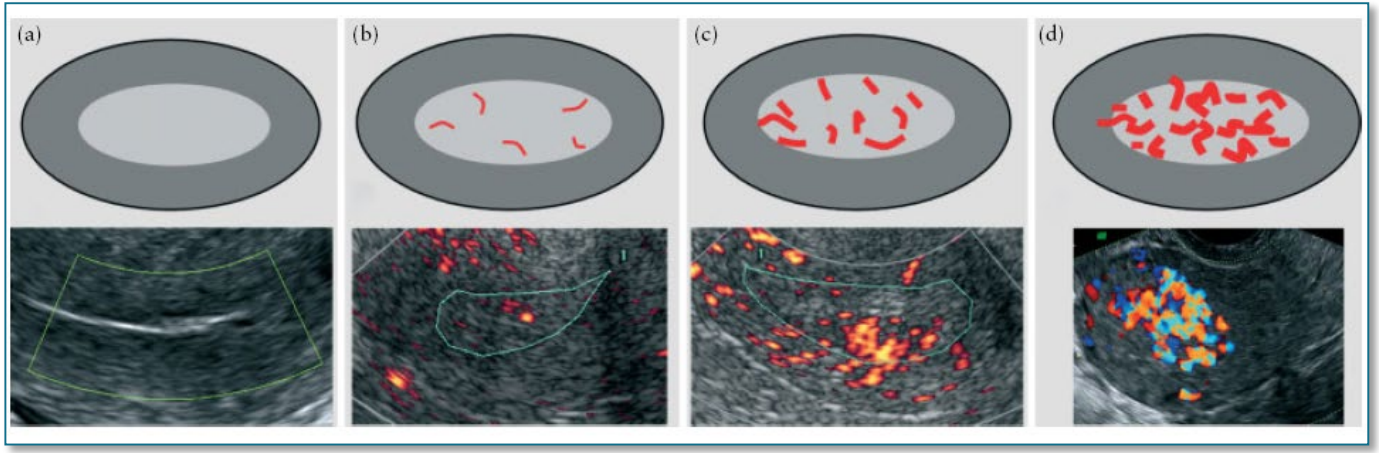

a. Color score of **1:** **no** color
b. Color score of **2:** **minimal** color (i.e. minimal flow)
c. Color score of **3:** **moderate** color (i.e. moderate flow)
d. Color score of **4:** **abundant** color (i.e. abundant flow)

Vascular pattern

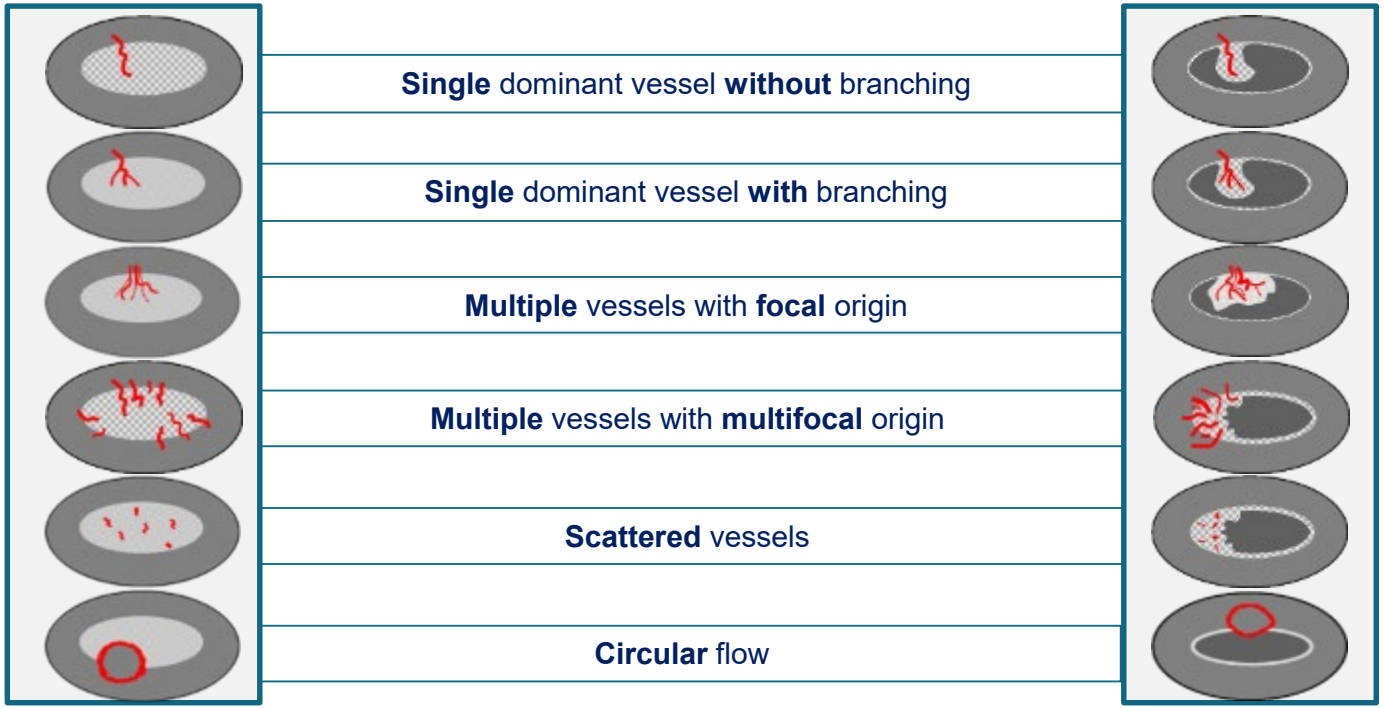

ATROPHY	
PROLIFERATIVE OR SECRETORY	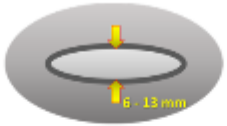
ENDOMETRIAL HYPERPLASIA	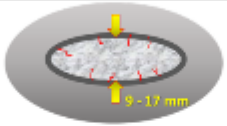
ENDOMETRIAL POLYP	
LEIOMYOMA	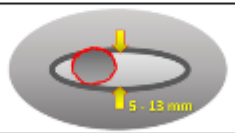
ATYPICAL HYPERPLASIA	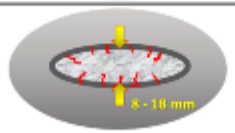
ENDOMETRIAL CANCER	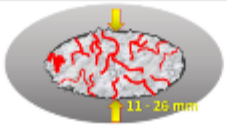

IETA 1

N = 2856

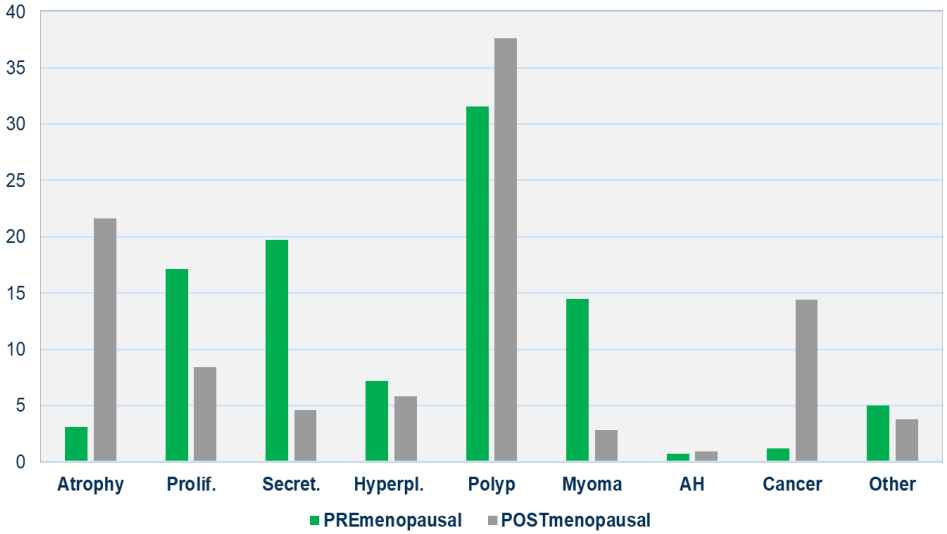

Van den Bosch T, et al.
Ultrasound Obstet Gynecol - *in press*

FEATURE		% (95% CI)
THIN ENDOMETRIUM < 3MM	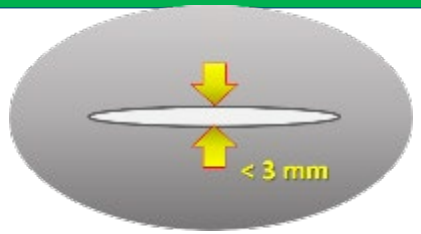	0% (0.0 – 5.5)
3-LAYER TYPE	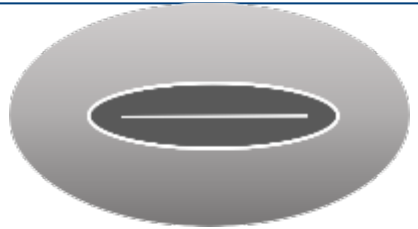	1.1% (0.4 – 3.1)
LINEAR MIDLINE		0.7% (0.2 – 1.3)
SINGLE VESSEL WITHOUT BRANCHING	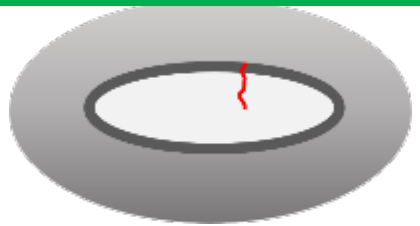	1.5% (0.6 – 3.4)





IETA 1

N = 2856

Van den Bosch T, et al.
Ultrasound Obstet Gynecol - *in press*

Endometrial cancer

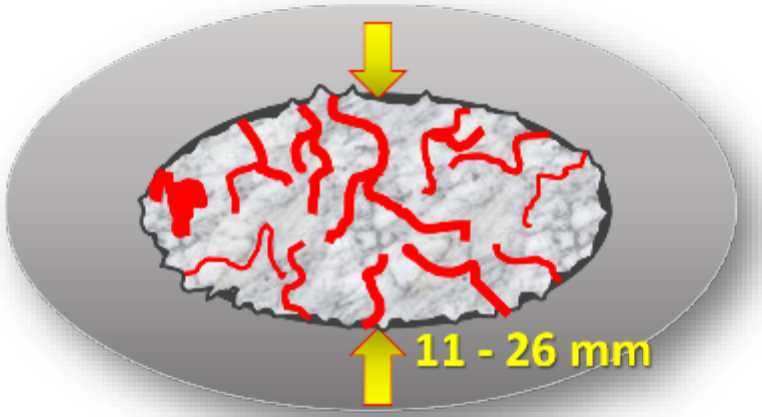



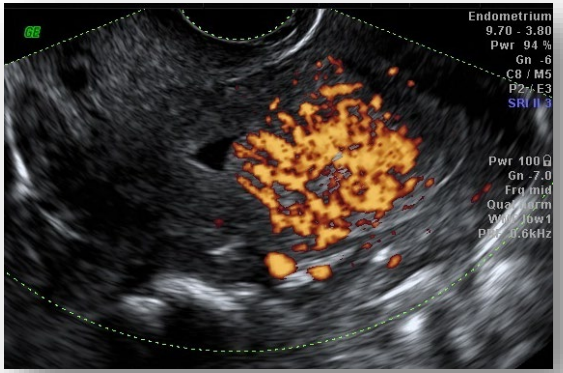

Van den Bosch T, et al.
Ultrasound Obstet Gynecol - *in press*



Diagnostic algorithm

ABNL BLEEDING

ULTRASONOGRAPHY

OVARIES

MYOMETRIUM[1]

ENDOMETRIUM[2]

BLADDER[3]

RECTUM

THIN & UNIFORM

NO SAMPLING



[1]Van den Bosch T, Dueholm M, et al. Ultrasound Obstet Gynecol 2015;46:284-98.
[2]Bignardi T, et al. Best Pract Res Clin Obstet Gynaecol 2009;23:595-607.
[3]Betsas G, et al. Ultrasound Obstet Gynecol 2008;32:959-60.



Diagnostic algorithm

ABNL BLEEDING

ULTRASONOGRAPHY

OVARIES

MYOMETRIUM

ENDOMETRIUM

BLADDER

RECTUM

DIFFUSE

THIN & UNIFORM

OFFICE SAMPLING

NO SAMPLING





Diagnostic algorithm

ABNL BLEEDING

ULTRASONOGRAPHY

OVARIES | MYOMETRIUM | ENDOMETRIUM | BLADDER | RECTUM

DIFFUSE | FOCAL | THIN & UNIFORM

OFFICE SAMPLING | HYSTEROSCOPY | NO SAMPLING

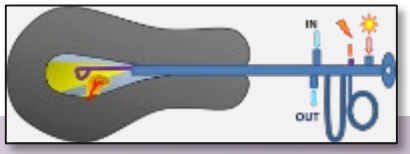

Polyp

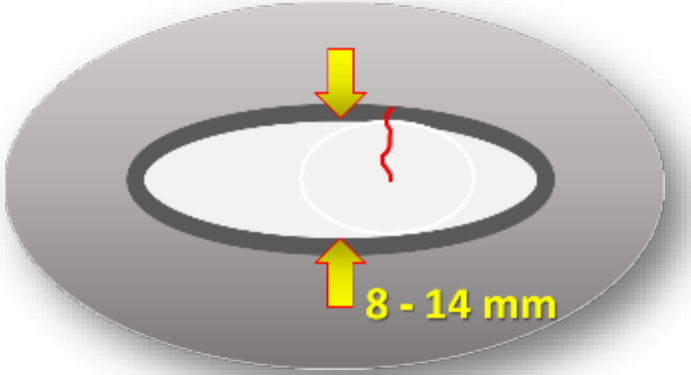

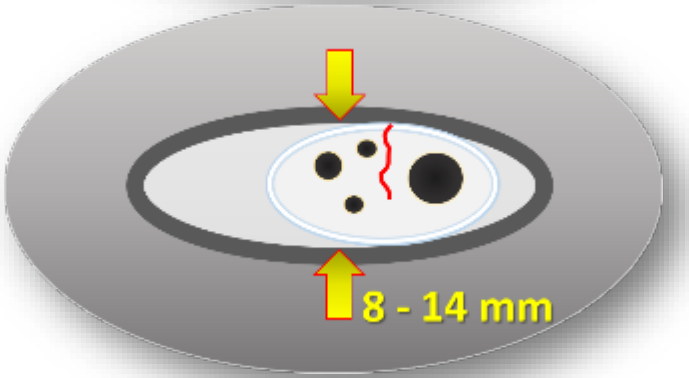

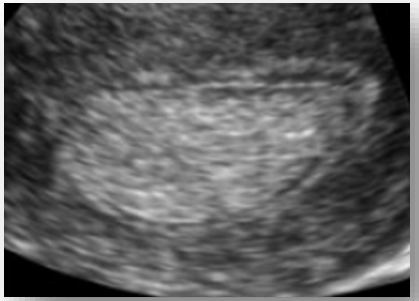

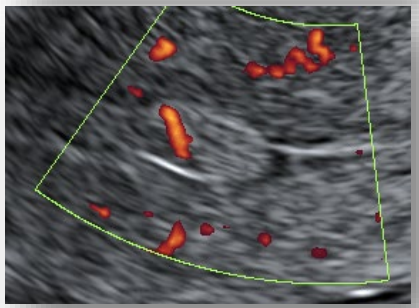

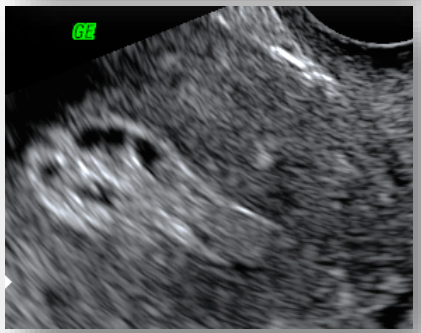

Van den Bosch T, et al.
Ultrasound Obstet Gynecol - *in press*

How to detect "FOCAL endometrial pathology" ?

- Fluid instillation
  - SalineIS
  - GelIS

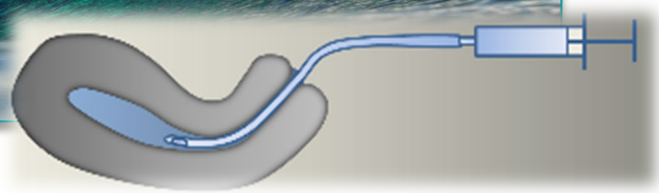

Fluid instillation sonography

POLYP



FIBROID



SYNECHIAE

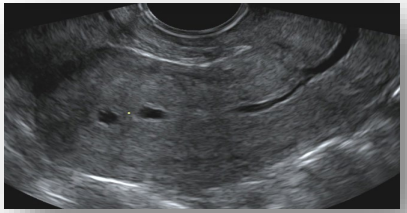

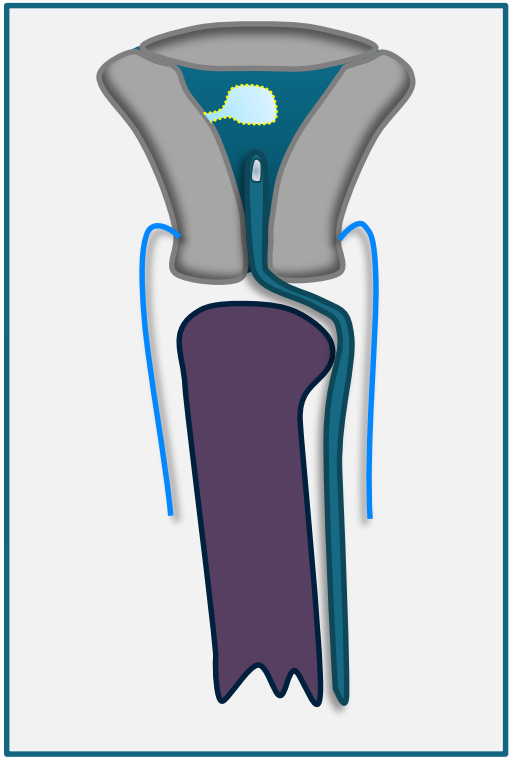



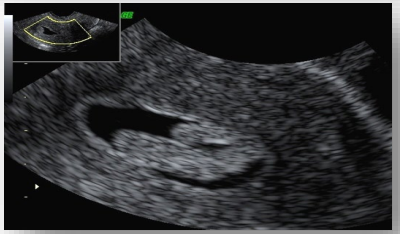



Werbrouck E, et al. Fertil Steril 2011;95:285-8

ENDOMETRIAL POLYP



LEIMYOMA



ENDOMETRIAL CANCER



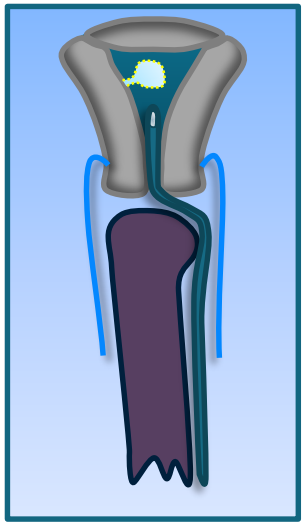

IETA 1

Van den Bosch T, et al.
Ultrasound Obstet Gynecol - *in press*

Hydrosonography



Meta-analysis†

	Sensitivity (95% CI)	Specificity (95% CI)	LR+ (95% CI)	LR- (95% CI)
Assessment of uterine cavity	95% (93-97)	88% (85-92)	8.23 (6.22-10.9)	0.06 (0.04-0.09)
For polyps	86% (81-91)	81% (72-88)	5.23 (3.98-6.9)	0.12 (0.08-0.17)
For fibroids	87% (79-92)	92% (86-95)	11.0 (6.86-17.6)	0.07 (0.03-011)

Failure rate
- for SIS: 4%* - 7%†
- for GIS: 2%*

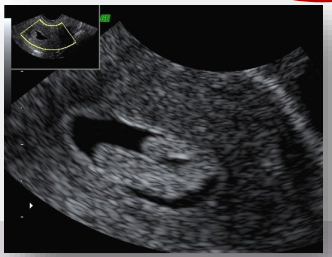



†de Kroon et al. BJOG 2003;110:938-47

*E. Werbrouck et al. Fertil Steril 2011;95:285-8

Gel instillation sonography: all you need …



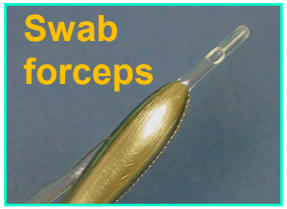

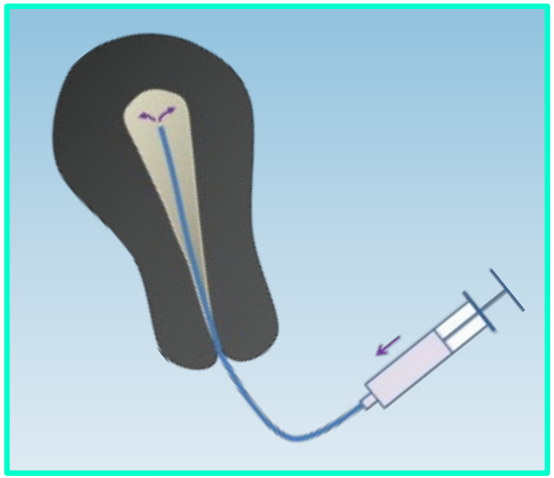





GEL



Water or gel ?

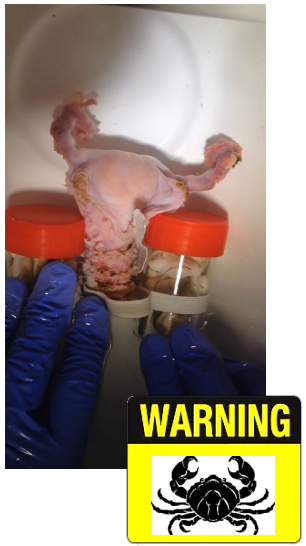

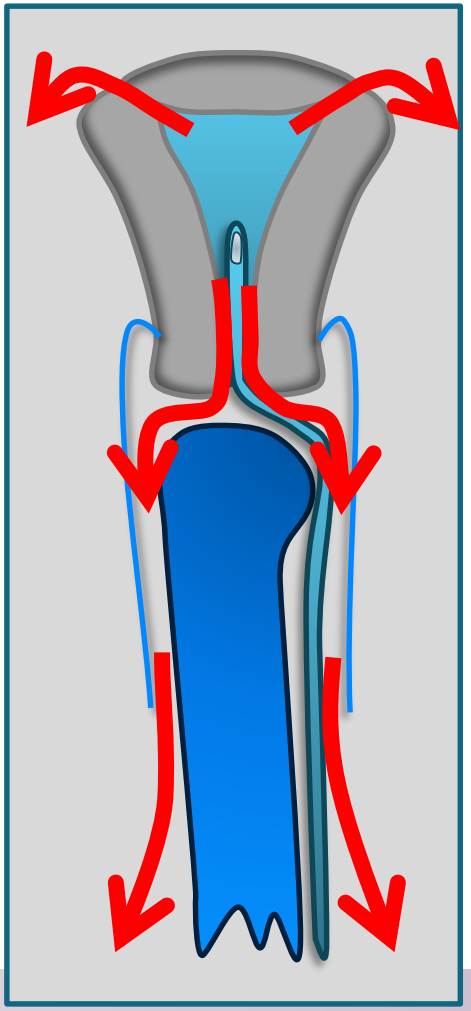

Gel I S

- cheap catheter
- less reflux
- less transtubal flow
- stable image (+ 3D)
- small volumes (2-5 ml)

(1) W erbrouck E, et al. Fertil Steril 2011;95:285-8
(2) Exalto N, et al. Fertil Steril 2007;87:152-5
(3) Van den Bosch T, et al. Ultrasound Obstet Gynecol 2009;34:711-4
(4) Van den Bosch T, et al. Ultrasound Obstet Gynecol 2011;38:355-9
(5) Van den Bosch T, et al. Ultasound Obstet Gynecol 2008;32:257
(6) Thijssen S, et al. J Med Ultrasound 2020; 28: 35-40

Why ?

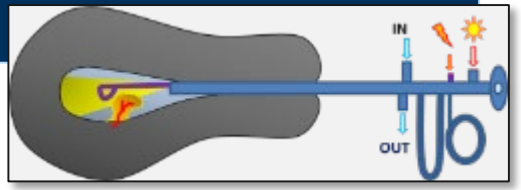

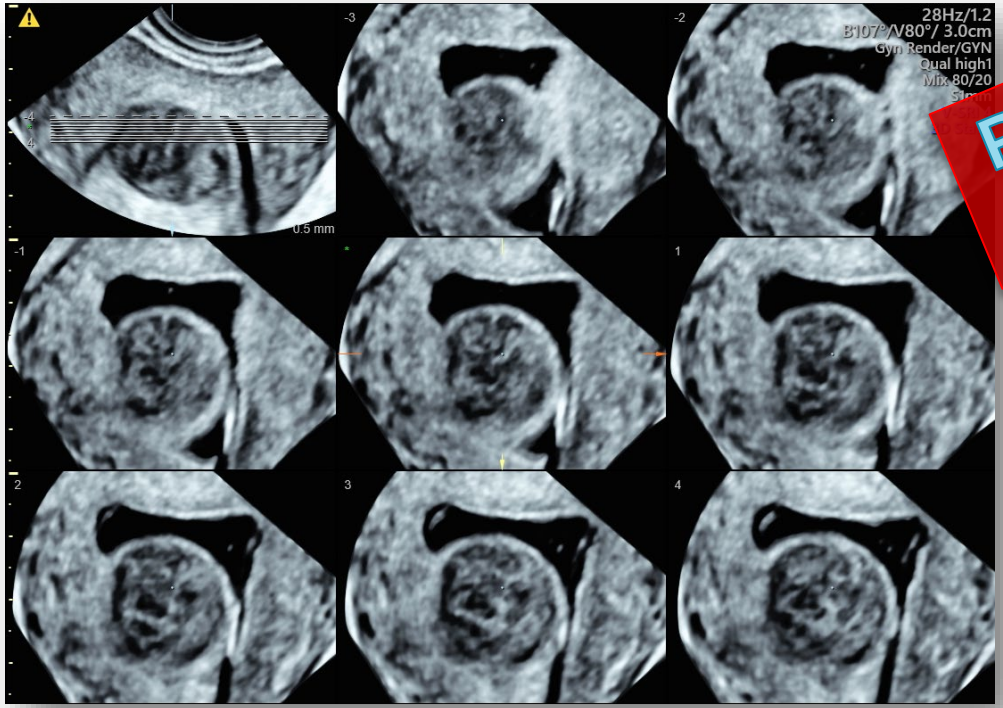

Preop. info!

Who?
Where?
When?
OR-time?

Volume

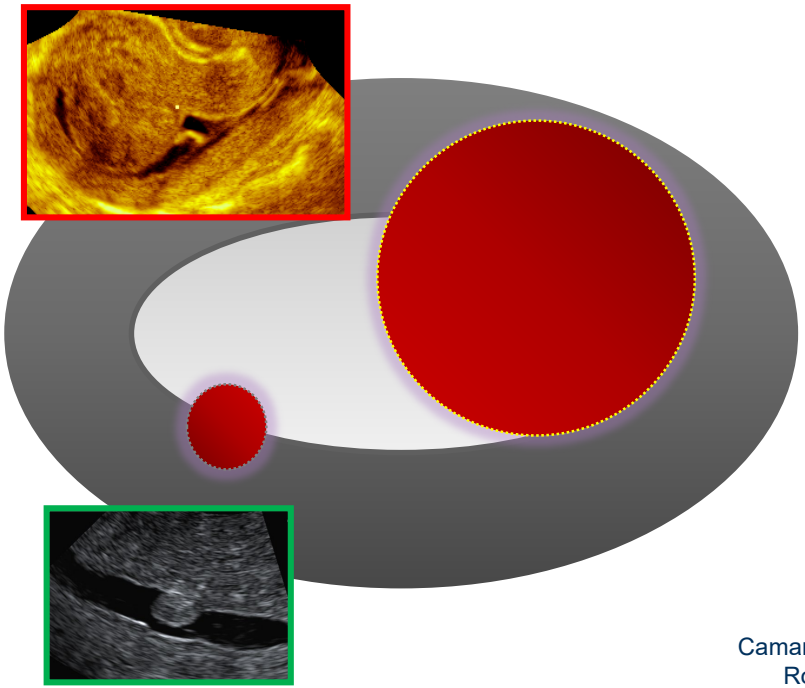

< 2 cm

2 – 5 cm

> 5 cm

Camanni M, et al. J Minim Invasive Gynecol 2010;17:59-65
Rovio PH, et al. Arch Gynecol Obstet 2009;279:159-63
Di Spiezio Sardo A, et al. Hum Reprod Update 2008;14:101-19
Marret H, et al. BJOG 2005;112:461-5
Cravello L, et al. Gynecol Obstet Fertil 2004;32:825-8
Emanuel MH, et al. Obstet Gynecol 1999;93:743-8

Grade



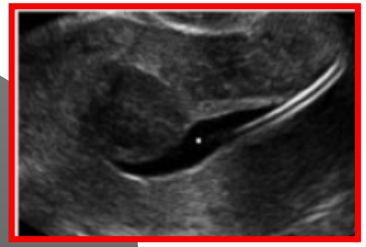



Lasmar RB, et al. Fertil Steril 2011;95:2073-7
Leone F, et al. Ultrasound Obstet Gynecol 2010;35:103-112
Rovio PH, et al. Arch Gynecol Obstet 2009;279:159-63
Cravello L, et al. Gynecol Obstet Fertil 2004;32:825-8
Wamsteker K, et al. Obstet Gynecol 1993;82:736-40

Number

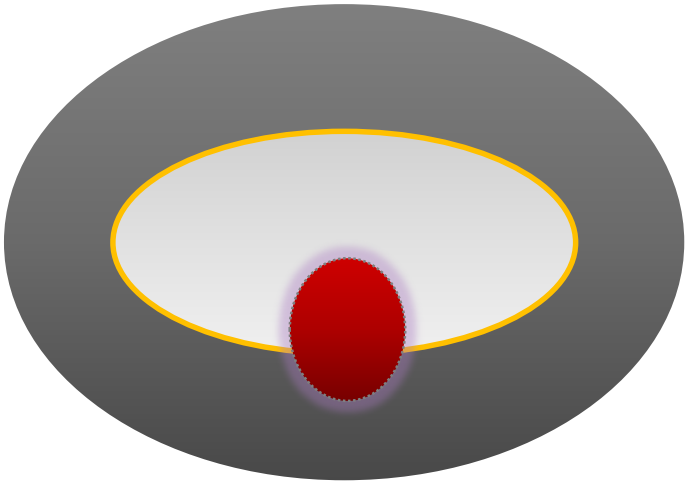

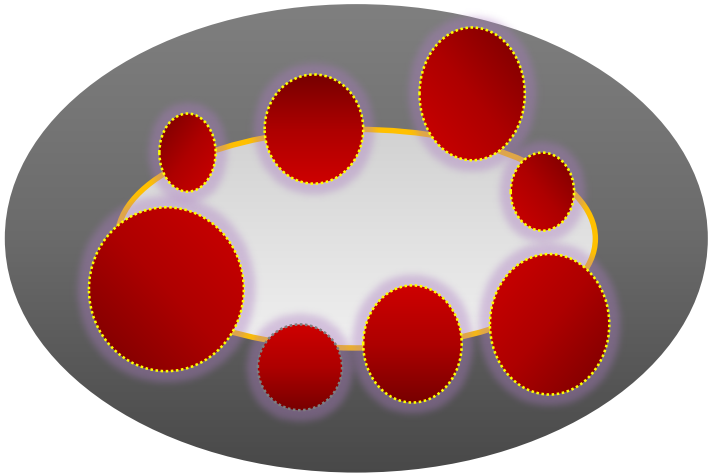





Marret H, et al. BJOG 2005;112:461-5
Emanuel MH, et al. Obstet Gynecol 1999;93:743-8



Diagnostic algorithm

[1]Van den Bosch T, Dueholm M, et al. Ultrasound Obstet Gynecol 2015;46:284-98.
[2]Bignardi T, et al. Best Pract Res Clin Obstet Gynaecol 2009;23:595-607.
[3]Betsas G, et al. Ultrasound Obstet Gynecol 2008;32:959-60.
[4]Van den Bosch T, et al. J Obstet Gynaecol 2012;32:173-6.

Office sampling

Tissue yield



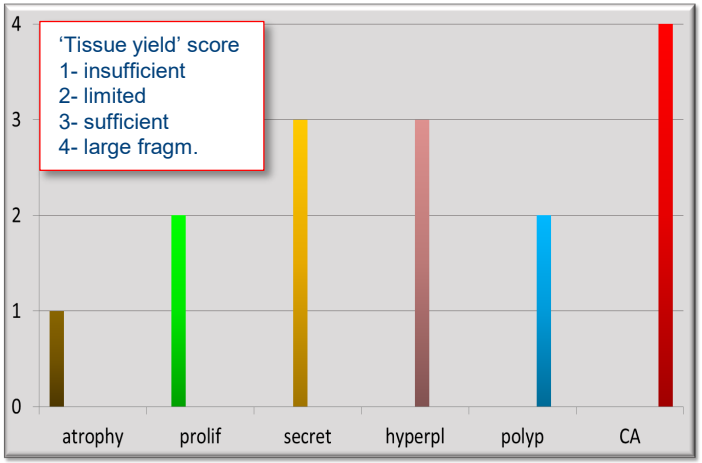

Research Article

Pre-sampling ultrasound evaluation and assessment of the tissue yield during sampling improves the diagnostic reliability of office endometrial biopsy

T. van den Bosch ✉ D. van Schoubroeck, B. van Calster, A. Cornelis & D. Timmerman

J Obstet Gynaecol 2012;32:173-6

First, perform an ultrasound !

Ultrasound Obstet Gynecol 2005; **26**: 283–286
Published online 5 August 2005 in Wiley InterScience (www.interscience.wiley.com). **DOI:** 10.1002/uog.1967

Ultrasound examination of the endometrium before and after Pipelle endometrial sampling

T. VAN DEN BOSCH*†, D. VAN SCHOUBROECK†, L. AMEYE‡, S. VAN HUFFEL‡ and D. TIMMERMAN†

Ultrasound feature	Before Pipelle	After Pipelle	p-value
Endometrial thickness	9.0 mm	8.6 mm	< 0.0001
RegularOutline	41%	34%	0.031
3-layer pattern	18%	3%	0.0003
Echogenic spots	17%	36%	0.0001
Intracavity fluid	13%	17%	0.39



Diagnostic algorithm

ABNL BLEEDING

ULTRASONOGRAPHY

OVARIES

MYOMETRIUM

ENDOMETRIUM

BLADDER

RECTUM

MYOMA

ADENOMYOSIS

SARCOMA

THIN

FOCAL

DIFFUSE

HOME

HYSTEROSCOPY

SAMPLING



Two stop ?



First stop

One stop

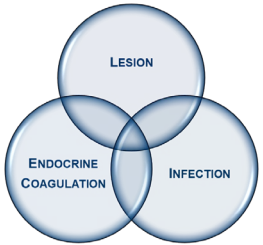

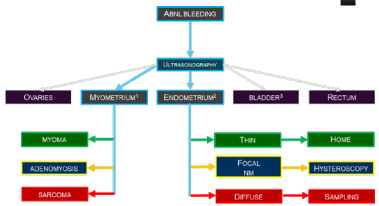


Dank u