Ziekte van Rendu-Osler-Weber
Oplossingen op Maat?

Pentalfa 23 November 2023

Ziekte van Rendu-Osler-Weber (ROW)
Hereditaire Hemorrhagische Teleangiectasieën (HHT)

- Erfelijke, systemische, progressieve bloedingsziekte door aberrante bloedvatvorming
  - Epistaxis en gastro-intestinale bloedingen
  - Ferriprieve anemie
  - Arterioveneuze malformaties in
    - Longen – Lever – Hersenen
- Geen (goede) behandeling



https://doi.org/10.1016/B978-0-12-812532-8.00003-3

Ziekte van Rendu-Osler-Weber: Oplossingen op Maat?

Genetische diagnostiek en screening	Prof. dr. Jeroen Breckpot Prof. dr. Veerle Labarque	Centrum Medische Erfelijkheid Pediatrie
Arterio-veneuze malformaties	Prof. dr. Catharina Belge Prof. dr. Geert Maleux	Pneumologie Radiologie
Epistaxis: oude en nieuwe therapieën Multidisciplinaire aanpak	Prof. dr. Peter Hellings Prof. dr. Peter Verhamme	Neus-, keel- en oorziekten Bloedings- en Vaatziekten

Hereditaire Hemorragische Teleangiëctasieën

Genetische diagnostiek en Screening

Jeroen Breckpot & Veerle Labarque

Pentalfa 23 November 2023

Hereditaire Hemorragische Teleangiëctasieën

Genetische diagnostiek

Jeroen Breckpot
Centrum voor Menselijke Erfelijkheid
UZ Leuven

Jeroen.Breckpot@uzleuven.be

Hereditaire Hemorragische Teleangiëctasieën (HHT)



Hereditaire Hemorragische Teleangiëctasieën (HHT)

Moleculaire Pathogenese

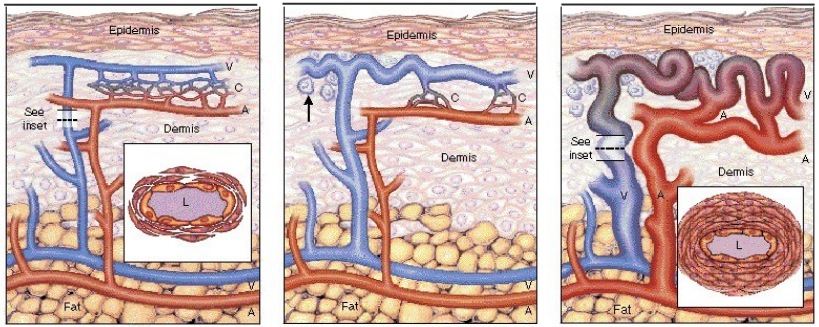

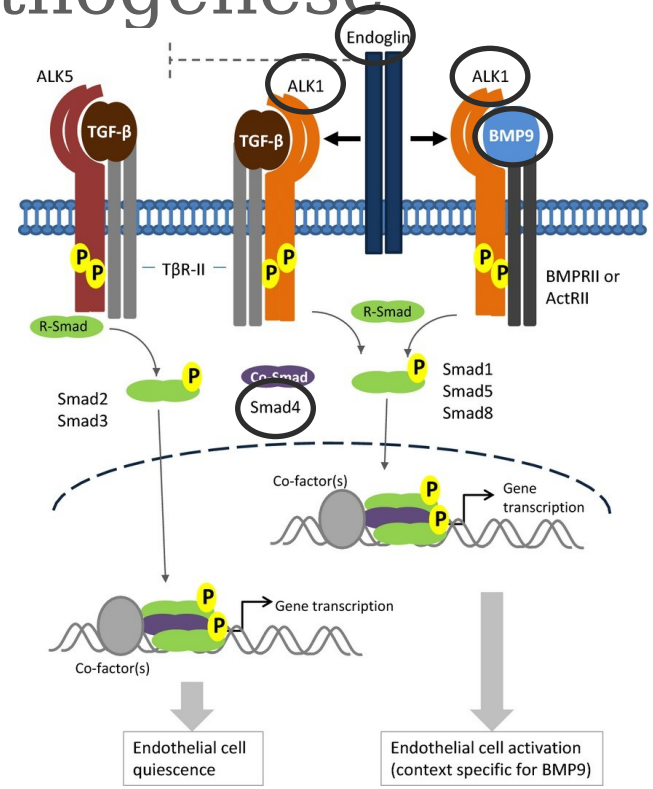

ed from Guttmacher *et al. NEJM 1995*

Hereditaire Hemorragische Teleangiëctasieën (HHT)

Genetische diagnostiek

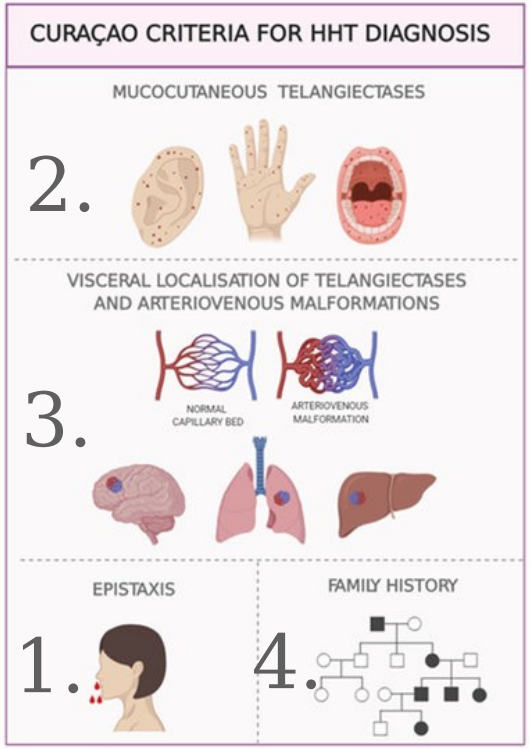

3 of meer = definite HHT
2 = suspected HHT
1 = unlikely HHT



Hereditaire Hemorragische Teleangiëctasieën (HHT)

Genetische diagnostiek

Exome sequencing + MLPA voor ENG en ALK1



Gene	HHT type	Yield*
ENG	HHT1	35-40%
ACVRL1 (ALK1)	HHT2	40-50%
SMAD4	JP + HHT	1-2%
GDF2 (BMP9)	PAH + HHT5	<1%
RASA1	CM+AVM	
EPHB4	CM+AVM	

Exome sequencing voor PAH/HHT genanalyse

Hereditaire Hemorragische Teleangiëctasieën (HHT)

Genetische diagnostiek

Exome sequencing + MLPA voor ENG en

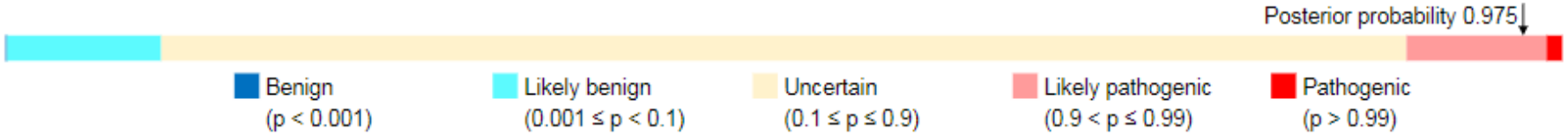

- ✓ Class 1: no functional effect — <1%
- ✓ Class 2: likely benign — 1- 4.9%
- ✓ Class 3: variant of unknown significance — 5 - [illegible] ?
- ✓ Class 4: likely pathogenic — 95 - 99% — **reported**
- ✓ Class 5: pathogenic — > 99%

CMG guidelines for variant classification Richards *et al.* Genet

Hereditaire Hemorragische Teleangiëctasieën (HHT)

Genetische diagnostiek



- ✓ phenotyping
- ✓ pre-test counseling

NGS request

- ✓ Kinderarts
- ✓ Inwendige specialist
- ✓ Neuroloog
- ✓ Klinisch Geneticus

Variant classification



Variant interpretation

✓ 

✓ 

✓ 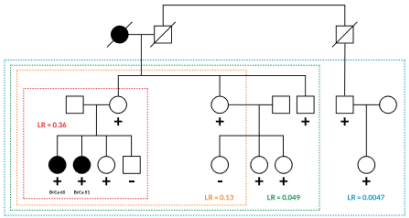

✓ 

Hereditaire Hemorragische Teleangiëctasieën (HHT)

Genotype-fenotype correlatie

90% <30j

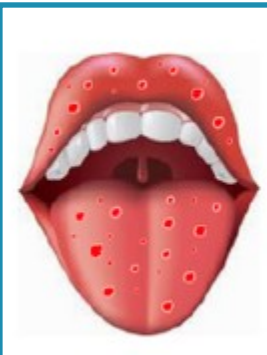



50%





10%



40-70%



intrafamilial variability: genetic modifiers?!

ENG > ACVRL1

ACVRL1 > ENG

Lesca *et al.* Genet Med 2007

Hereditaire Hemorragische Teleangiëctasieën (HHT)

Negatief genetisch onderzoek

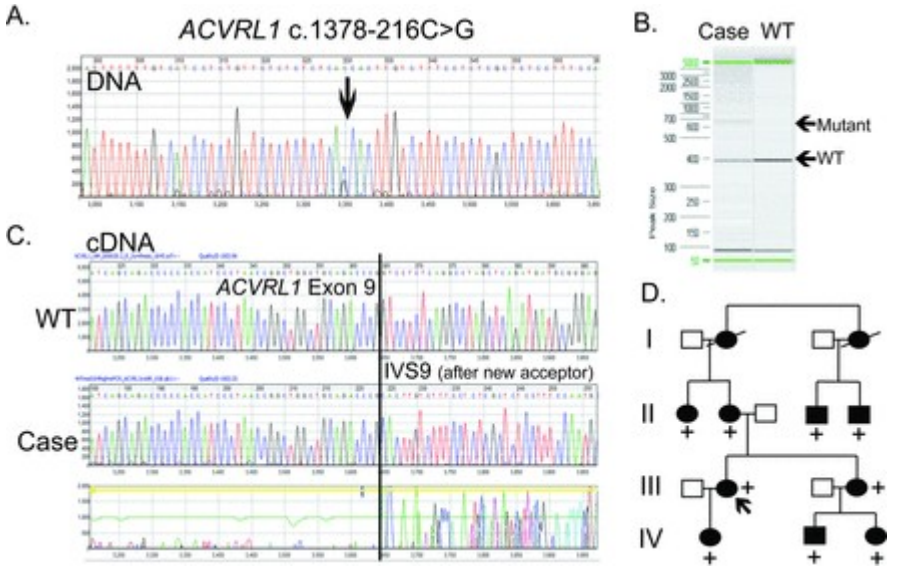

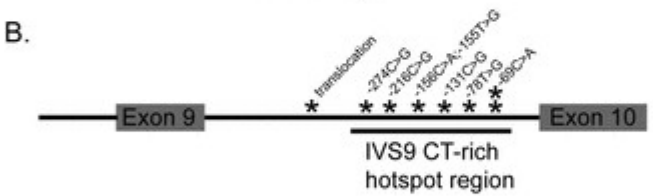

Non-coding variants (≠ WES):
Vb. diep intronische varianten!

Hereditaire Hemorragische Teleangiëctasieën (HHT)

Predictief genetisch onderzoek



Pathogene variant in ACVRL1

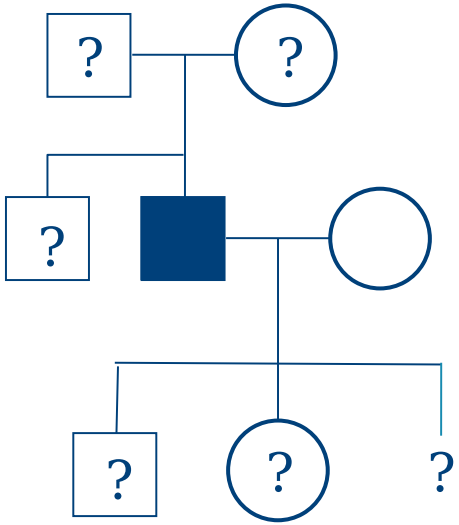

Pre-test en post-test counseling:

- ✓ Counseling ivm risico's & overerving
- ✓ Counseling ivm screening
- ✓ Doorverwijzing specialist/HHT tea
- ✓ Preconceptionele counseling
  - IVF-PGT
  - Zwangerschapscomplicaties
- ✓ Psychologische aspecten
- ✓ Juridische aspecten

Genetics of Internal Medicine



lead
NWZ
nniek
Corveleyn



TEV
Karen
Rosier



a
villen



Cyr
K



Master
Evelien Van Hoof



ster
Van Loo



Sa
aert



Ma
Sa
Wille

6 MLT's

Cuno Kuiperi, Ann Bamps, Katrien Weckx, Kelly Verstraete, Steffi Van Loo, Nasibe Karakaya













Hereditaire Hemorragische Teleangiëctasieën

Screening

Veerle Labarque
Pediatrische hemato-oncologie

Pentalfa 23 November 2023

Diagnose HHT

- Diagnostische criteria
- Genetische bevestiging
- Genetische testing van (asymptomatische) kinderen

  (strong recommendation; 94% agreement)

Initiële evaluatie

- Goede anamnese: epistaxis, symptomen van viscerale AVMs (e.g. dyspnea, hemoptoë, migraine,…)

- Gericht klinisch onderzoek: teleangiëctasieën, tekenen van viscerale AVMs (e.g. clubbing, saturatie, hepatomegalie…)

- Labo-onderzoek: hemoglobine, ijzerstatus

Teleangiëctasieën bij klinisch onderzoek





Nut van screenen = risk-benefit evaluatie

Geeft detectie en behandeling van **asymptomatische** afwijking een gezondheidsvoordeel aan de patient?

- gevaar van silentieus AVM (tov symptomatisch AVM)
- veiligheid van onderzoek
- voordeel voor behandeling en opvolging
- veiligheid van effectieve behandeling

Viscerale AVMs bij kinderen?

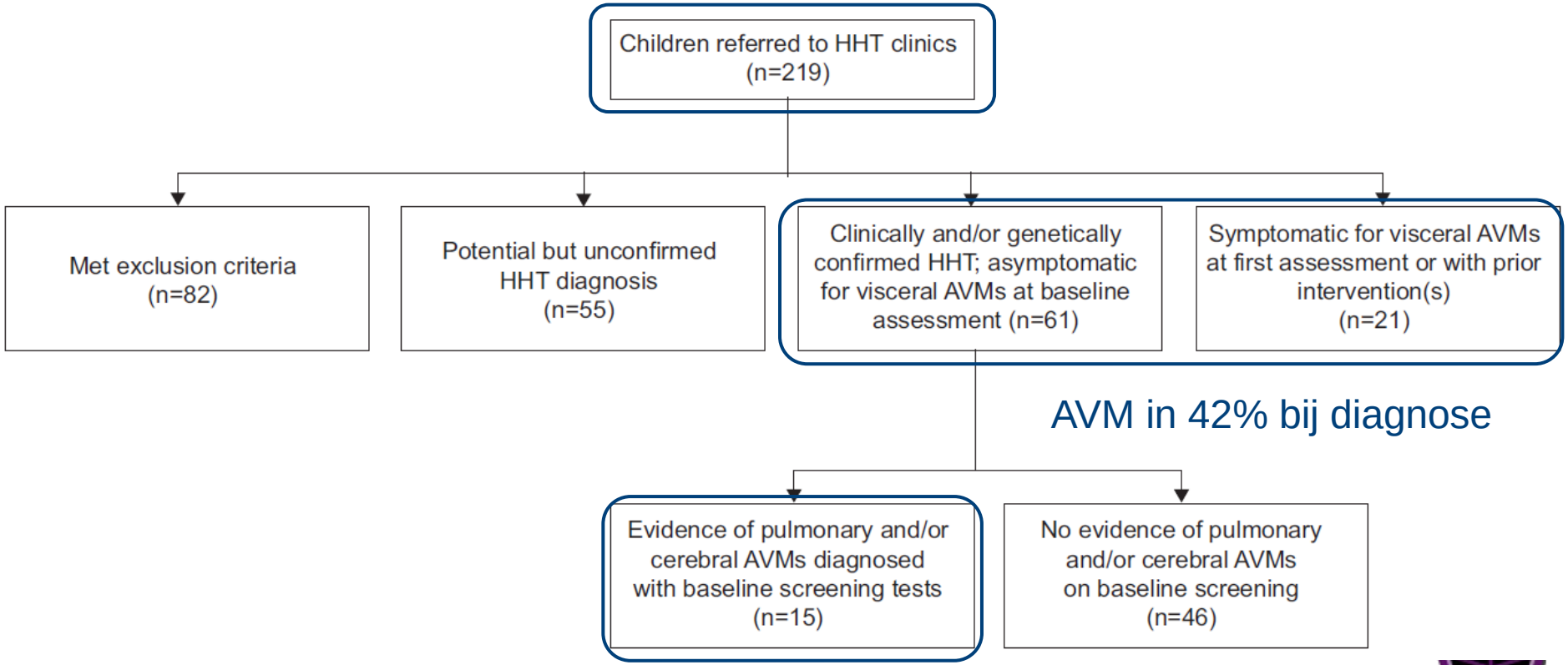

Al-Saleh et al. Eur Respir J 2009;34:875

Screening voor Pulmonale AVM

- Kan gepaard gaan met ernstige complicaties zoals CVA en hersenabces

- Kan makkelijk gediagnosticeerd worden

- Effectieve en veilige therapie dmv embolisatie mogelijk

⏶ Screening aanbevolen bij **alle volwassenen**



Pulmonale AVM bij kinderen?

Clinical manifestation	Focal group	Diffuse group	Total group
Exercise intolerance*	16/30 (53%)	8/12 (67%)	24/42 (57%)
Cyanosis	13/30 (43%)	12/12 (100%)‡	25/42 (60%)
Clubbing	10/30 (33%)	9/12 (75%)‡	19/42 (45%)
Hemoptysis	1/30 (3%)	2/12 (17%)	3/42 (7%)
TIA	0/30 (0%)	1/12 (8%)	1/42 (2%)
Stroke†	4/30 (13%)	2/12 (17%)	6/42 (14%)
Cerebral abscess	0/30 (0%)	2/12 (17%)‡	2/42 (5%)

- Screening aanbevolen bij **alle patiënten**

(strong recommendation; 94% agreement)

Faughnan et al. J Pediatr 2004;145:826

Screening voor Pulmonale AVM

- “bubble”- echocardiografie (volwassenen, oudere kinderen, symptomatische kinderen)
- CT thorax
- saturatiemeting + RX thorax
- Interval 5 jaar of bij symptomen?

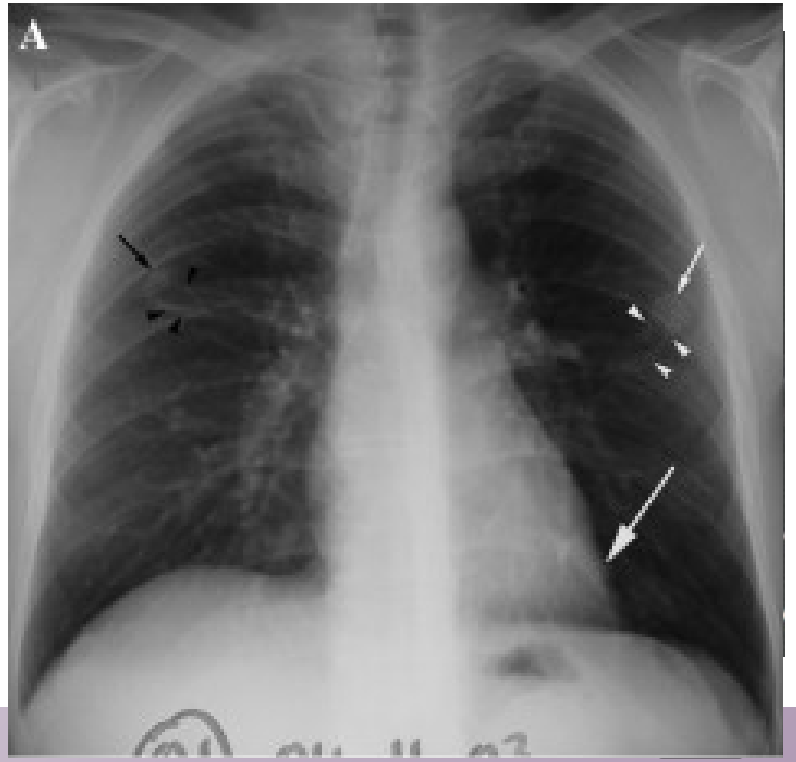

Screening PAVM: positionele saturatie?

Patient group	n	Age mean (SD)	Gender female (male)	O_2 saturation upright mean (SD)	O_2 saturation supine mean (SD)	p (Wilcoxon test) supine versus upright
PAVMs (feeding vessel > 2 mm)	14	7.6 (4.6)	6 (8)	93.1 (8.4)*	93.9 (6.0)*	0.94
PAVMs (feeding vessel <2 mm)	19	7.7 (4.8)	8 (11)	99.0 (1.2)	98.9 (1.4)	0.98
All PAVMs	33	7.7 (4.6)	14 (19)	96.5 (6.2)	96.7 (4.7)	0.64
Genetically confirmed HHT, no PAVM	60	6.6 (5.1)	28 (32)	98.7 (1.0)	98.7 (1.1)	0.56
HHT not genetically confirmed, no AVM	116	6.99 (4.6)	50 (66)	98.6 (1.4)	99.0 (1.1)	0.27

*($p<0.01$; ANOVA).
HHT, hereditary haemorrhagic telangiectasia; PAVMs, pulmonary arteriovenous malformations.



Carpenter et al. Thorax 2014;69:1045

Screening voor Cerebrale AVM

- Bloeding gaat gepaard met invaliderende sequelen en kan fataal zijn.
- Meeste HHT-gerelateerde CAVM bloeden niet. CAVM met hoogste kans op bloeding komen bij neonaten voor (AVF en giant aneursymata).
- Behandeling houdt risico in.

⇒ Screening aanbevolen **bij diagnose en na puberteit**
(strong recommendation; 86% agreement)



Kroon et al. Curr Opin Pulm Med 2018;24:260

Screening voor Cerebrale AVM

- MRI

- Transfontanellaire echografie

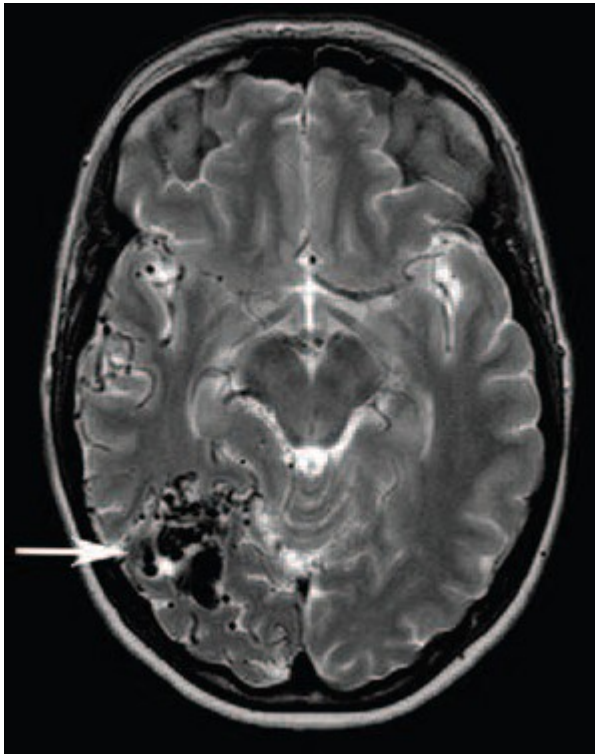

Screening voor Hepatische AVM

screening is overbodig, gezien geen therapie nodig indien asymptomatisch
(weak recommendation voor screening)

- Echo doppler
- (Contrast CT)
- MRI
- levertesten

Opsporen van GI bloeding

- Screening obv hemoglobine en ijzerstatus jaarlijks

- Gastroscopie
- Capsule endoscopie
- Colonoscopie om de 3 jaar vanaf 15 jaar bij SMAD4 variant (of jaarlijks bij vaststellen poliep)

Take home

- Genetische diagnostiek bij (asymptomatische) kinderen
- Klinische screening op symptomen
- Opvolgen hemoglobine en ijzerstatus
- Screening voor PAVM **bij alle patiënten**
- Screening voor CAVM **bij diagnose en na puberteit**
- Screening voor HAVM?



AVM bij HHT

Catherine Belge MD, PhD
Pneumologie UZ – KU Leuven

Geert Maleux MD, PhD
Interventionele Radiologie UZ – KU Leuven

Een stukje geschiedenis













"19th century" HHT	The current view of HHT	
Telangiectasia	90%+	Nose bleeds
	80%	Skin, lips, mouth telangiectasia
Nose bleeds	30%	Pulmonary AVMs
Gastrointestinal bleeding	<30%	Hepatic AVMs
↓	15%	Gastrointestinal bleeds
Iron deficiency and anaemia	10%	Cerebral AVMs
	1%	Spinal AVMs

Pulmonale arterioveneuze malformaties

Eerste vermelding

HEMORRHAGIC TELANGIECTASIA WITH PULMONARY ARTERY ANEURYSM: CASE REPORT

By R. Wayne Rundles, Ph.D., M.D.
Instructor in Internal Medicine, Ann Arbor, Mich.

(From the Thomas Henry Simpson Memorial Institute, University of Michigan)

Hereditary hemorrhagic telangiectasia (Rendu,[2] Osler,[17] Weber[23]) is an uncommon disease characterized by the familial occurrence of anomalous groups of capillary and venous dilatations which are subject to repeated hemorrhage. The following case illustrates many typical aspects of this disease and shows, in addition, some unusual features.

Rundles R
The American Journal of the Medical Sciences 1945-07:
Volume 210, Issue 1.

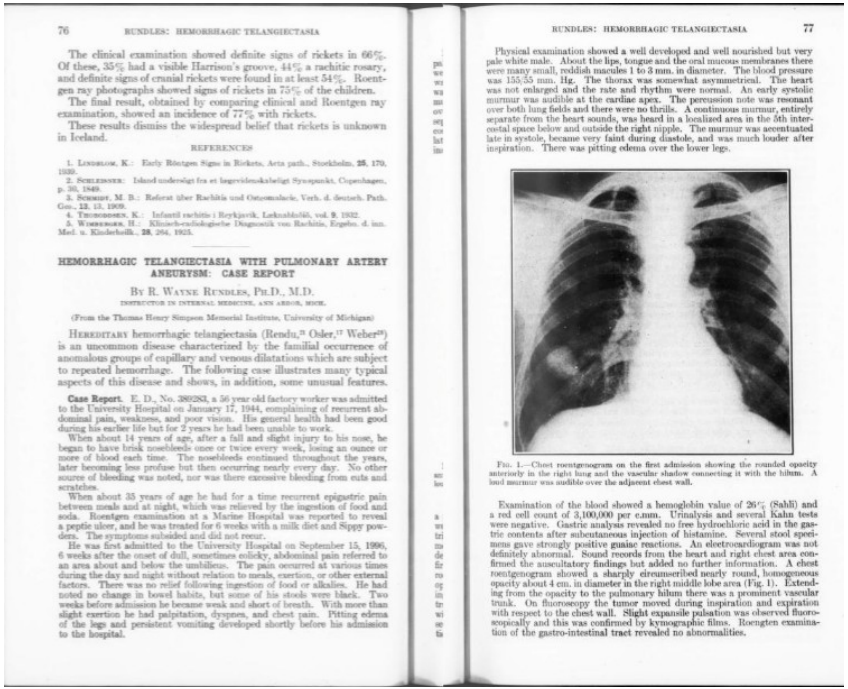

76 RUNDLES: HEMORRHAGIC TELANGIECTASIA

The clinical examination showed definite signs of rickets in 66%. Of these, 35% had a visible Harrison's groove, 44% a rachitic rosary, and definite signs of cranial rickets were found in at least 54%. Roentgen ray photographs showed signs of rickets in 75% of the children.

The final result, obtained by comparing clinical and Roentgen ray examination, showed an incidence of 77% with rickets.

These results dismiss the widespread belief that rickets is unknown in Iceland.

REFERENCES

1. Lindblom, K.: Early Röntgen Signs in Rickets. Acta path., Stockholm. **25**, 170. 1938.
2. Schleisner: Island undersøgt fra et lægevidenskabeligt Synspunkt, Copenhagen, p. 30, 1849.
3. Schmorl, M. B.: Referat über Rachitis und Osteomalacie, Verh. d. deutsch. Path. Ges., **13**, 12, 1909.
4. Thorgensen, K.: Infantil rachitis i Reykjavik. Læknablaðið, vol. 9. 1932.
5. Wimberger, H.: Klinisch-radiologische Diagnostik von Rachitis. Ergebn. d. ges. Med. u. Kinderheilk., **28**, 264, 1925.

HEMORRHAGIC TELANGIECTASIA WITH PULMONARY ARTERY ANEURYSM: CASE REPORT

By R. Wayne Rundles, Ph.D., M.D.
Instructor in Internal Medicine, Ann Arbor, Mich.

(From the Thomas Henry Simpson Memorial Institute, University of Michigan)

Hereditary hemorrhagic telangiectasia (Rendu,[2] Osler,[17] Weber[23]) is an uncommon disease characterized by the familial occurrence of anomalous groups of capillary and venous dilatations which are subject to repeated hemorrhage. The following case illustrates many typical aspects of this disease and shows, in addition, some unusual features.

Case Report. E. D., No. 389283, a 56 year old factory worker was admitted to the University Hospital on January 17, 1944, complaining of recurrent abdominal pain, weakness, and poor vision. His general health had been good during his earlier life but for 2 years he had been unable to work.

When about 14 years of age, after a fall and slight injury to his nose, he began to have brisk nosebleeds once or twice every week, losing an ounce or more of blood each time. The nosebleeds continued throughout the years, later becoming less profuse but then occurring nearly every day. No other source of bleeding was noted, nor was there excessive bleeding from cuts and scratches.

When about 35 years of age he had for a time recurrent epigastric pain between meals and at night, which was relieved by the ingestion of food and soda. Roentgen examination at a Marine Hospital was reported to reveal a peptic ulcer, and he was treated for 6 weeks with a milk diet and Sippy powders. The symptoms subsided and did not recur.

He was first admitted to the University Hospital on September 15, 1996, 6 weeks after the onset of dull, sometimes colicky, abdominal pain referred to an area about and below the umbilicus. The pain occurred at various times during the day and night without relation to meals, exertion, or other external factors. There was no relief following ingestion of food or alkalies. He had noted no change in bowel habits, but some of his stools were black. Two weeks before admission he became weak and short of breath. With more than slight exertion he had palpitation, dyspnea, and chest pain. Pitting edema of the legs and persistent vomiting developed shortly before his admission to the hospital.

RUNDLES: HEMORRHAGIC TELANGIECTASIA 77

Physical examination showed a well developed and well nourished but very pale white male. About the lips, tongue and the oral mucous membranes there were many small, reddish macules 1 to 3 mm. in diameter. The blood pressure was 155/55 mm. Hg. The thorax was somewhat asymmetrical. The heart was not enlarged and the rate and rhythm were normal. An early systolic murmur was audible at the cardiac apex. The percussion note was resonant over both lung fields and there were no thrills. A continuous murmur, entirely separate from the heart sounds, was heard in a localized area in the 5th intercostal space below and outside the right nipple. The murmur was accentuated late in systole, became very faint during diastole, and was much louder after inspiration. There was pitting edema over the lower legs.

Fig. 1.—Chest roentgenogram on the first admission showing the rounded opacity anteriorly in the right lung and the vascular shadow connecting it with the hilum. A loud murmur was audible over the adjacent chest wall.

Examination of the blood showed a hemoglobin value of 26% (Sahli) and a red cell count of 3,100,000 per c.mm. Urinalysis and several Kahn tests were negative. Gastric analysis revealed no free hydrochloric acid in the gastric contents after subcutaneous injection of histamine. Several stool specimens gave strongly positive guaiac reactions. An electrocardiogram was not definitely abnormal. Sound records from the heart and right chest area confirmed the auscultatory findings but added no further information. A chest roentgenogram showed a sharply circumscribed nearly round, homogeneous opacity about 4 cm. in diameter in the right middle lobe area (Fig. 1). Extending from the opacity to the pulmonary hilum there was a prominent vascular trunk. On fluoroscopy the tumor moved during inspiration and expiration with respect to the chest wall. Slight expansile pulsation was observed fluoroscopically and this was confirmed by kymographic films. Roentgen examination of the gastro-intestinal tract revealed no abnormalities.

Definitie

Een aberrante communicatie tussen één of meerdere longslagaders en één of meerdere longaders met een anatomische intrapulmonale rechts-links shunt tot gevolg.

Leeftijd

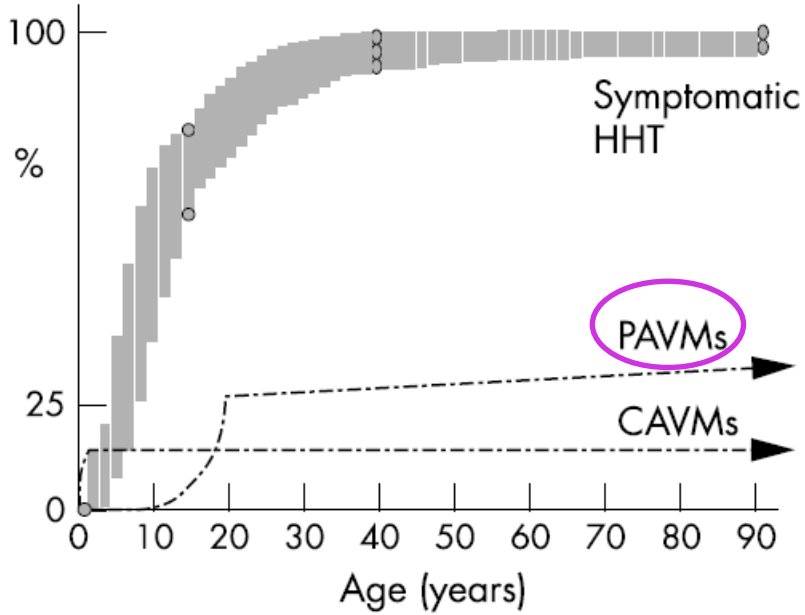
100
%
25
0
Symptomatic
HHT
PAVMs
CAVMs
0
10
20
30
40
50
60
70
80
90
Age (years)

Complicaties

Table 2 Complications of untreated pulmonary AVMs

Feature	Mean (%)	Range (%)	No of cases*
Respiratory			
Asymptomatic	49	25–58	260
Dyspnoea	49	27–71	483
Chest pain	14	6–18	198
Haemoptysis	11	4–18	479
Haemothorax	<1	0–2	192
Cyanosis	30	9–73	275
Clubbing	32	6–68	267
Bruit	49	25–58	263
Embolic phenomena			
Cerebral abscess	9	0–25	368
CVA or TIA	27	11–55	401

*Number of published cases in which frequency of feature assessed.
CVA, cerebrovascular accident; TIA, transient ischaemic attack.



Begbie M Postgrad Med 2003

Complicaties

Embolic myocardial infarction

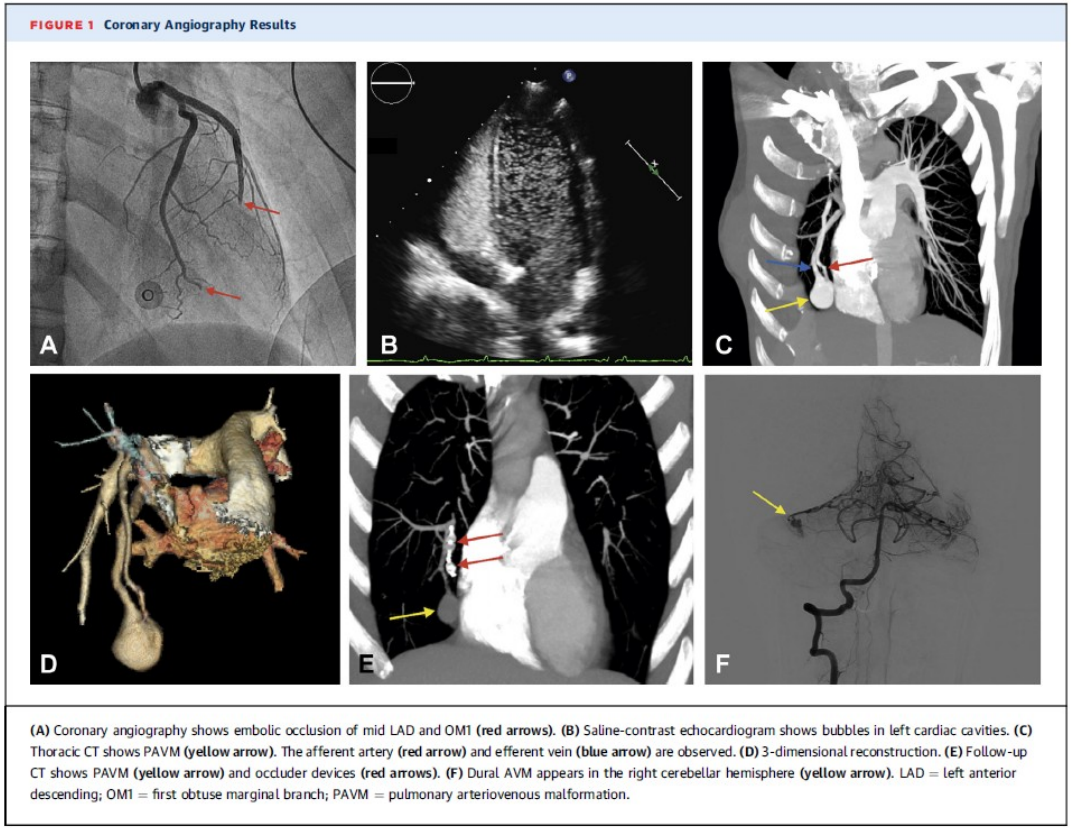



Sánchez-Fernández G J AmColl Cardiol Case Rep 2020

Screening : TTCE

No shunt

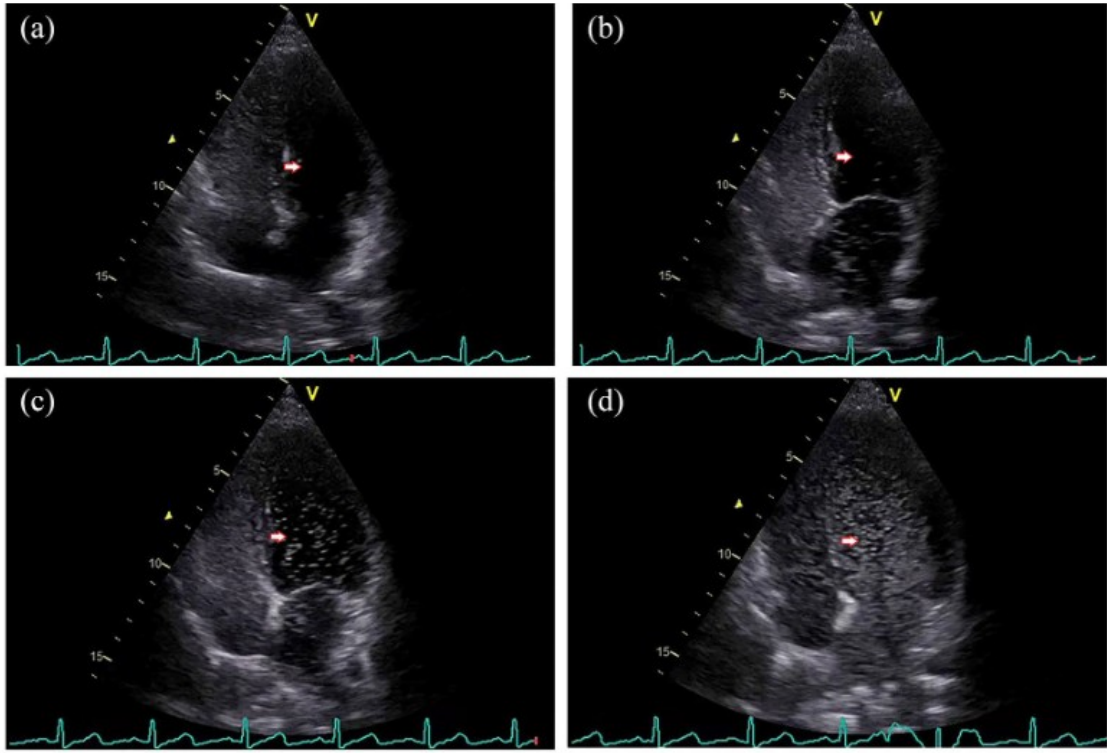

Grade 1

Grade 2

Grade 3

Screening: TTCE

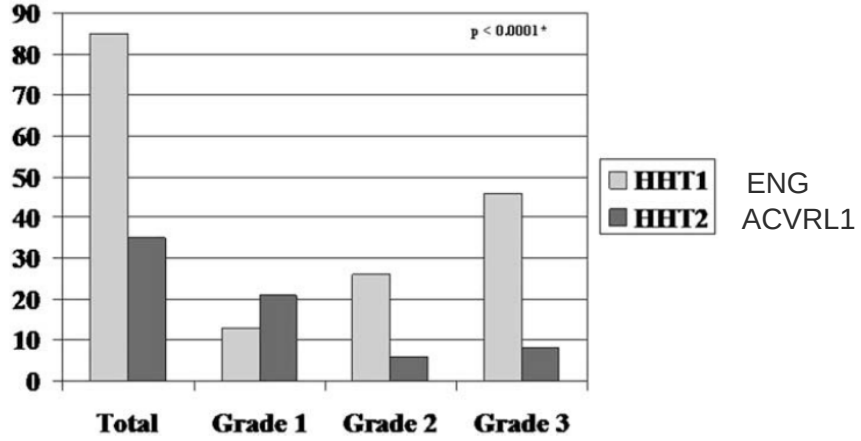

ENG
ACVRL1

FIGURE 2. Prevalence of pulmonary shunting on contrast echocardiography according to HHT genotype. Y-axis shows the % positive TTCE. X-axis shows the distribution of positive TTCE studies and shunt grades according to HHT genotype. Shaded bars = HHT1; solid bars = HHT2. $P < .0001$ for distribution of different shunt grades. See Figure 1 legend for expansion of abbreviations.

Van Gent M Chest 2010

TTCE with quantification

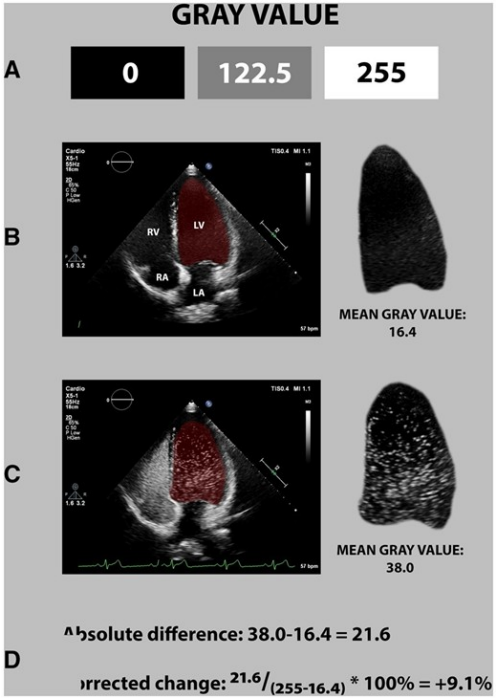

Figure 1 (A) Example of the mean grey value corresponding to three different hues: black (0), grey (122.5), and white (255). (B) Baseline measurement of the LV with a mean grey value of 16.4. (C) Measurement of LV with maximum number of echo bubbles present: a mean grey value of 38.0. (D) Absolute difference and corrected change in echo density.

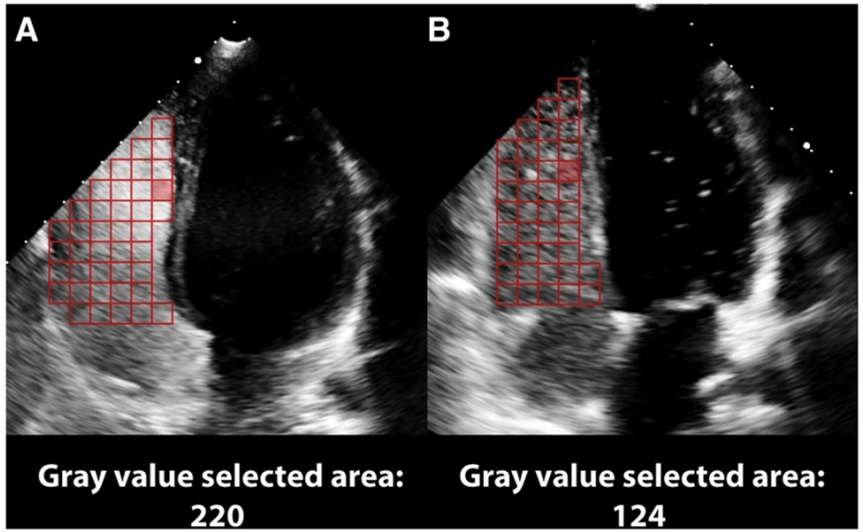

Figure 2 Analysis of the maximum contrast in the RV. (A) Good contrast availability with a grey value of 220 (almost completely white). (B) Moderate amount of contrast availability with a grey value of 124.

TTCE with quantification

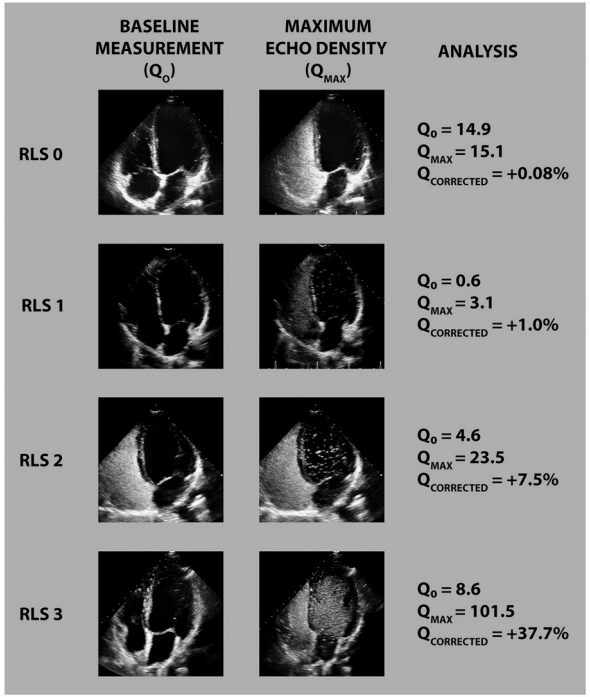

Figure 3 Examples of shunt grades with corresponding change in echo density. (A) RLS Grade 0 corresponds to an increase in ED of +0.08%. (B) RLS Grade 1 with an increase in ED of +1.0%. (C) RLS Grade 2 with an ED of +7.5%. (D) RLS Grade 3 with an increase of +37.7% in echo density.

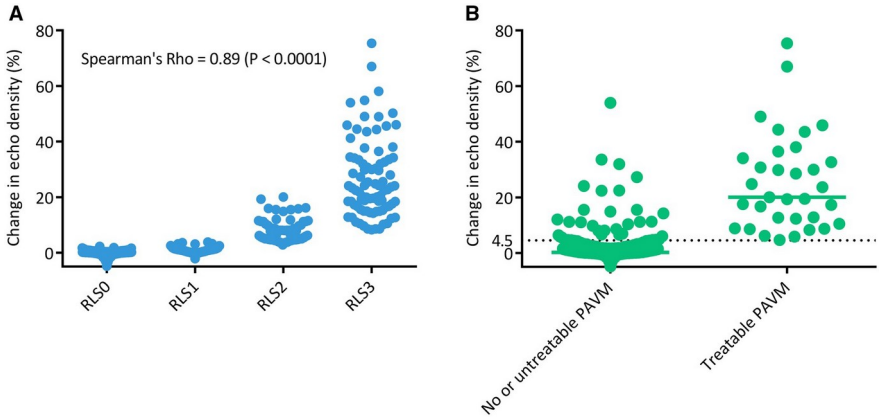

Figure 4 (A) Correlation between currently used grading method and the novel method. (B) Change in ED for individuals with treatable PAVMs and those without treatable PAVMs.

Screening

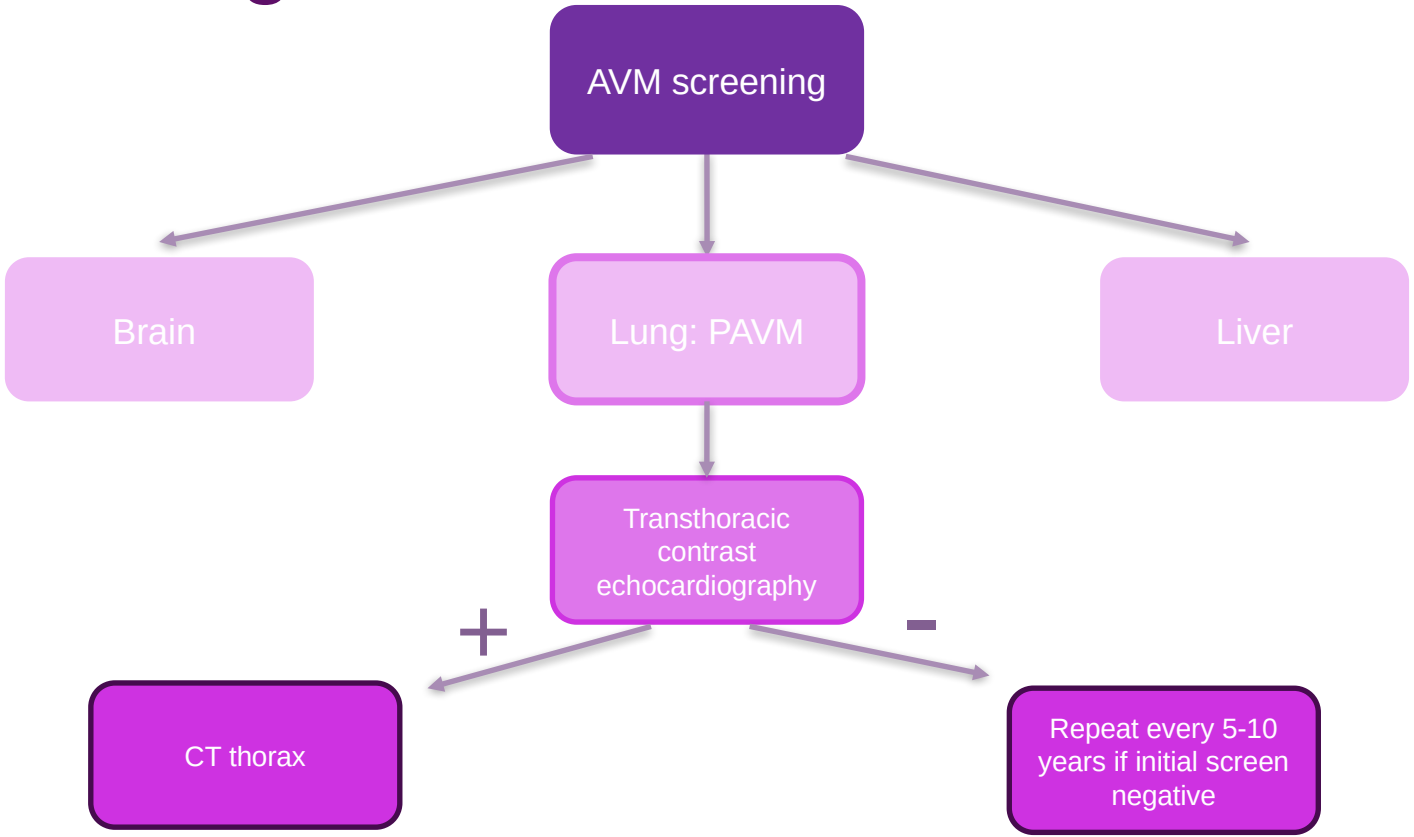

Based on Faughnan M, Ann Intern Med. 2020

Aanpak

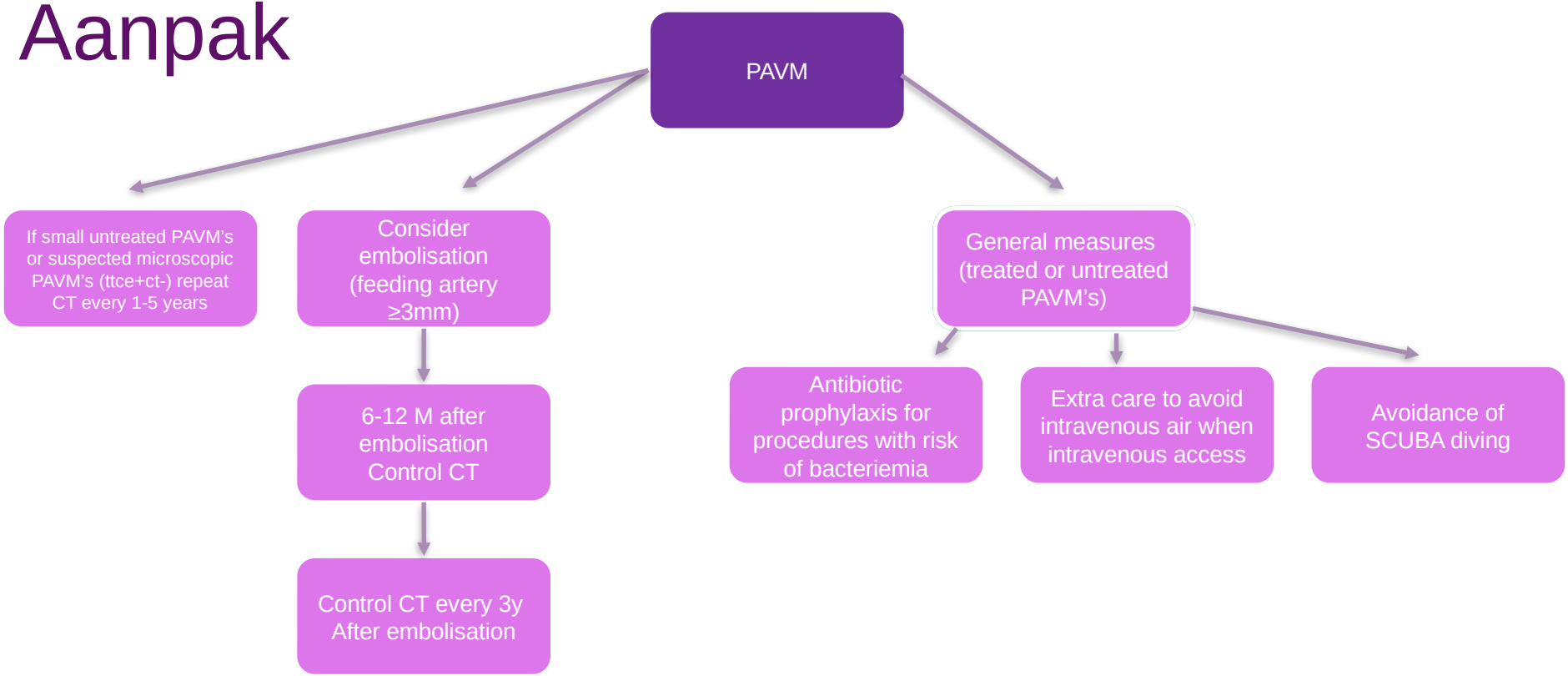

TTE with contrast (ttce) has been shown to be NOT useful after embolisation , it remains positive in ~ 90% of patients after embolisation

Behandeling : embolisatie

TABLE 1 Overall patient characteristics by pulmonary shunt grade on transthoracic contrast echocardiography

	No shunt	Grade 1	Grade 2	Grade 3	Total
Persons	262 (33.9)	201 (26.1)	150 (19.4)	159 (20.6)	772
Age years mean ± SD	47.3 ± 15.1	44.9 ± 16.1	43.7 ± 16.0	44.8 ± 14.2	45.5 ± 15.4
Sex					
Females	146 (32.5)	113 (25.2)	79 (17.6)	111 (24.7)	449 (58.2)
Males	116 (35.9)	88 (27.2)	71 (22.0)	48 (14.9)	323 (41.8)
HHT					
Definite	204 (29.7)	186 (27.0)	145 (21.1)	153 (22.2)	688 (89.1)
Possible	58 (69.0)	15 (17.9)	5 (6.0)	6 (7.1)	84 (10.9)
Genetic testing					
HHT1	21 (9.4)	39 (17.4)	57 (25.4)	107 (47.8)	224 (29.0)
HHT2	145 (47.5)	104 (34.1)	38 (12.5)	18 (5.9)	305 (39.5)
SMAD4	1 (10.0)	4 (40.0)	2 (20.0)	3 (30.0)	10 (1.3)
Unknown[#]	95 (40.8)	54 (23.2)	53 (22.7)	31 (13.3)	233 (30.2)

Data are presented as n (%), unless otherwise stated. HHT: hereditary haemorrhagic telangiectasia. [#]: unknown family mutation or genetic testing not performed.

TABLE 3 Distribution of pulmonary arteriovenous malformation (PAVM) feeding artery diameter on chest computed tomography (CT) of embolised PAVMs

PAVM feeding artery diameter on chest CT mm	Patients n (%)
2.0–2.9	18 (12.0)
3.0–3.9	51 (34.0)
4.0–4.9	40 (26.7)
5.0–5.9	17 (11.3)
6.0–6.9	10 (6.7)
7.0–7.9	7 (4.7)
8.0–8.9	4 (2.6)
9.0–9.9	1 (0.7)
>10.0	2 (1.3)

Measurement of PAVM feeding artery diameters on chest CT was available in 150 (93.2%) out of 161 embolised patients. Largest diameter used in case of multiple PAVMs or feeders in one patient.



Velthuis S. Eur Resp J 2014

Behandeling : embolisatie

TABLE 4 Number of patients who underwent transcatheter embolotherapy of pulmonary arteriovenous malformations (PAVMs) by pulmonary shunt grade on transthoracic contrast echocardiography (TTCE)

Pulmonary shunt on TTCE	Persons n	PAVM on chest CT n (%)	Transcatheter embolotherapy performed n (% of positive chest CT)	PPV % (95% CI)
No shunt	262	6 (2.3)	0 (0)	0 (0)
Grade 1	201	27 (13.4)	0 (0)	0 (0)
Grade 2	150	68 (45.3)	38 (55.9)	25.3 (19.1–32.9)
Grade 3	159	147 (92.5)	123 (83.7)	77.4 (70.3–83.2)
Total	772	248 (32.1)	161 (64.9)	

CT: computed tomography; PPV: positive predictive value.

Velthuis S. Eur Resp J 2014

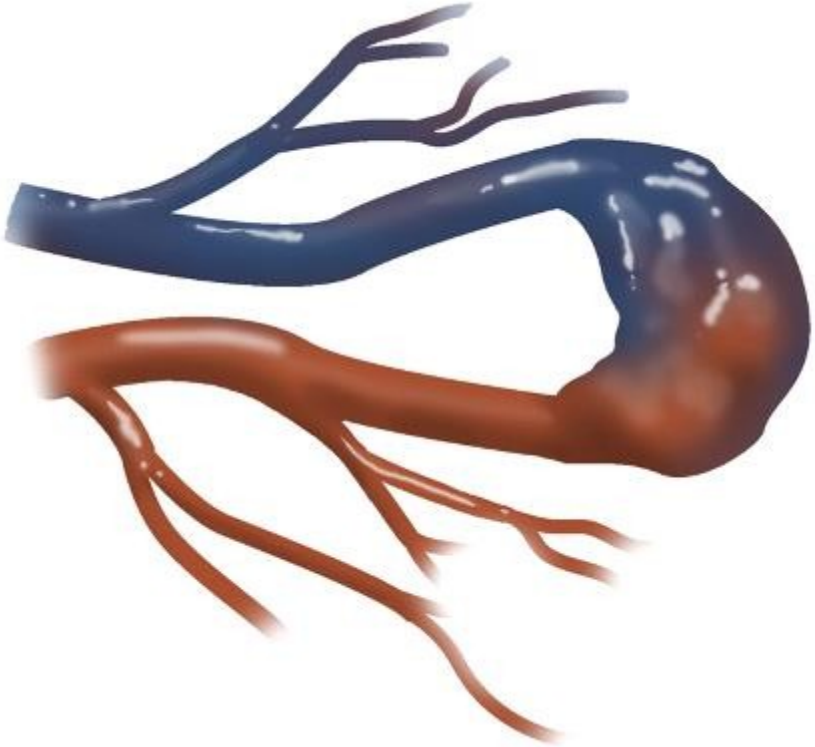



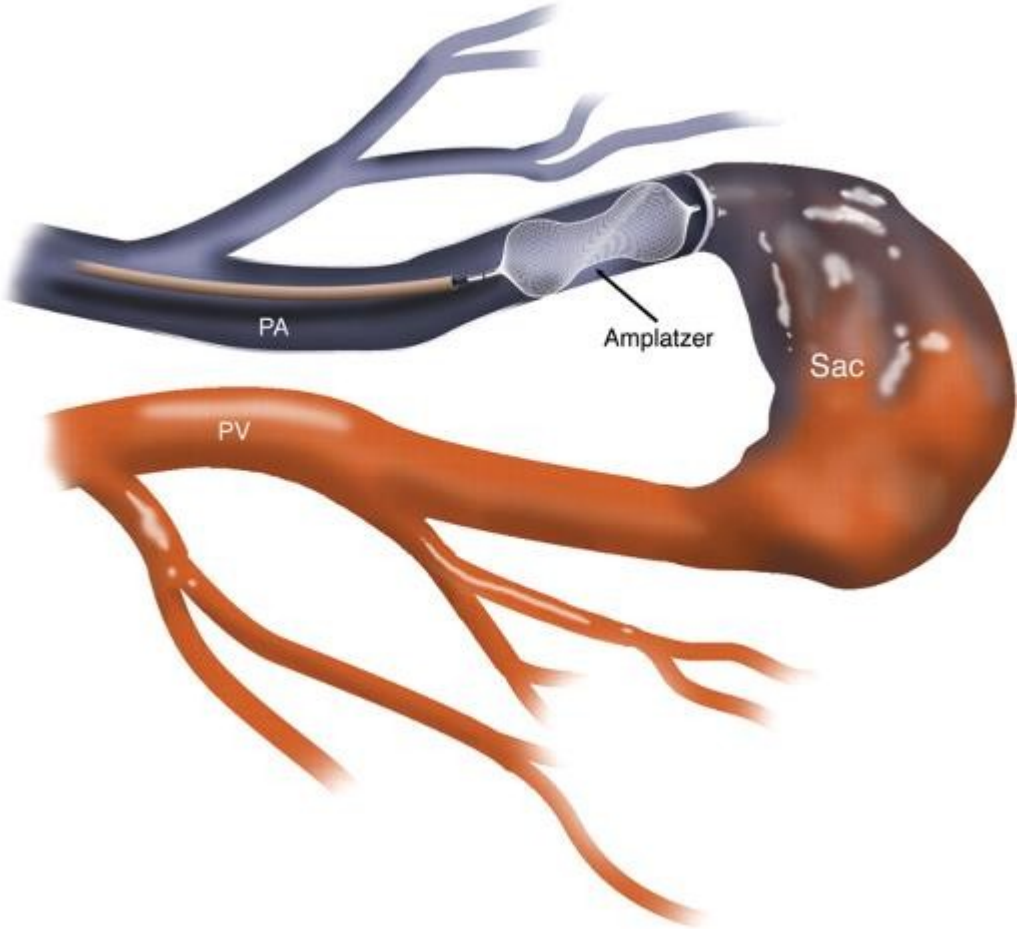
PA
Amplatzer
Sac
PV





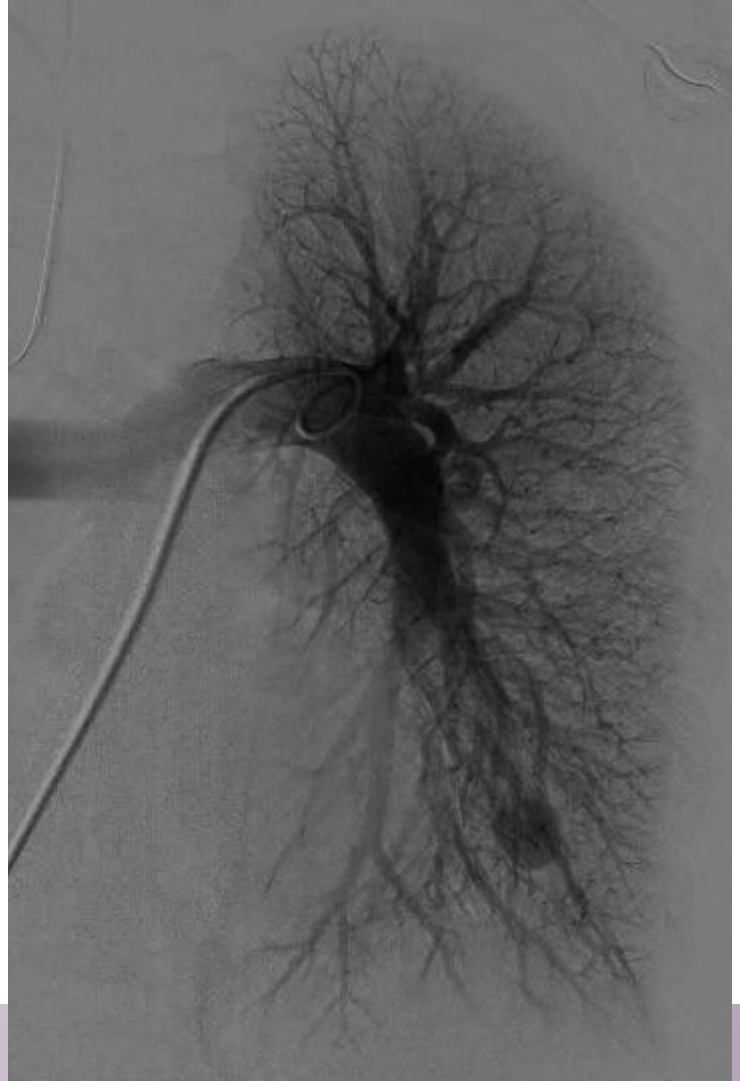

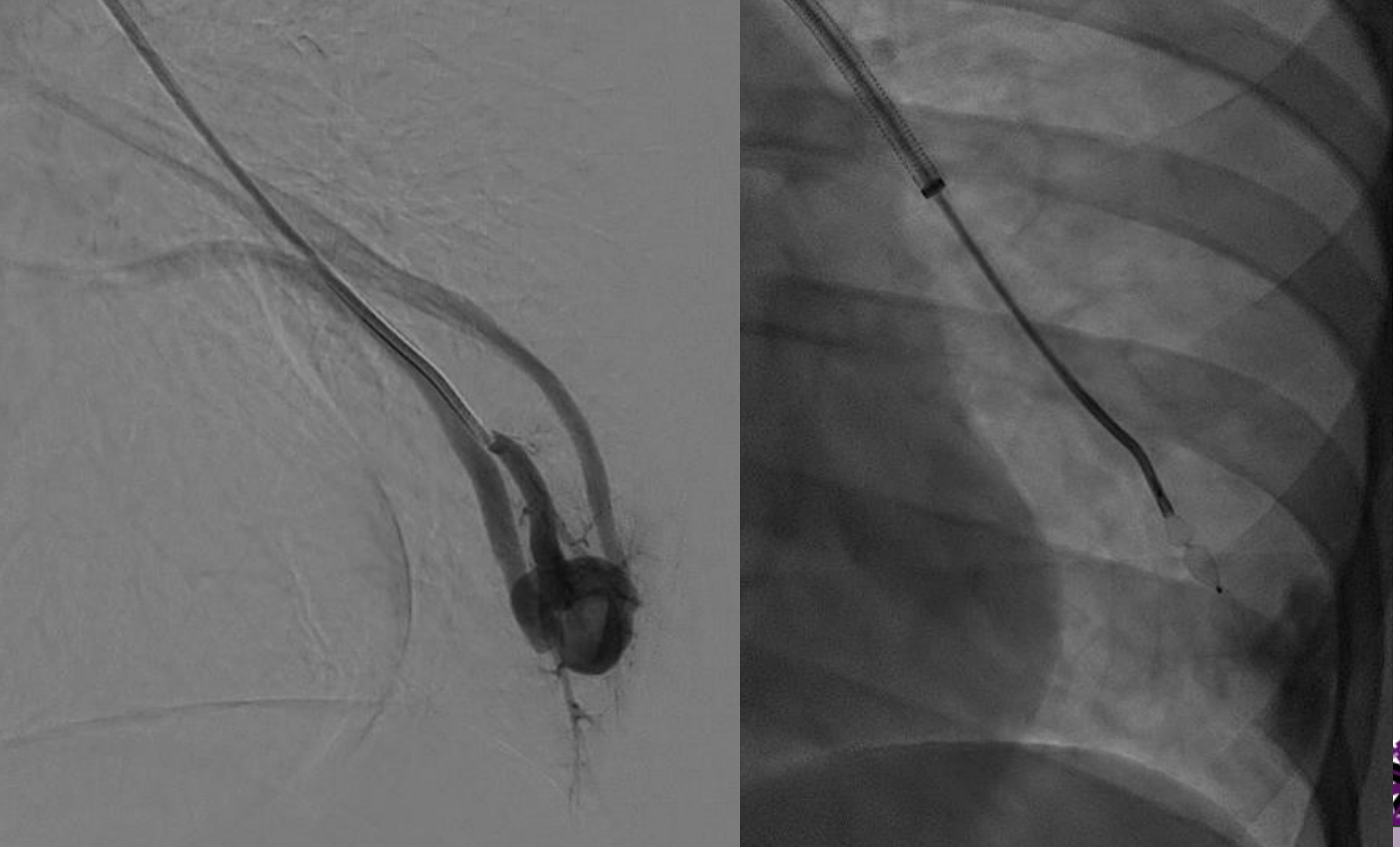


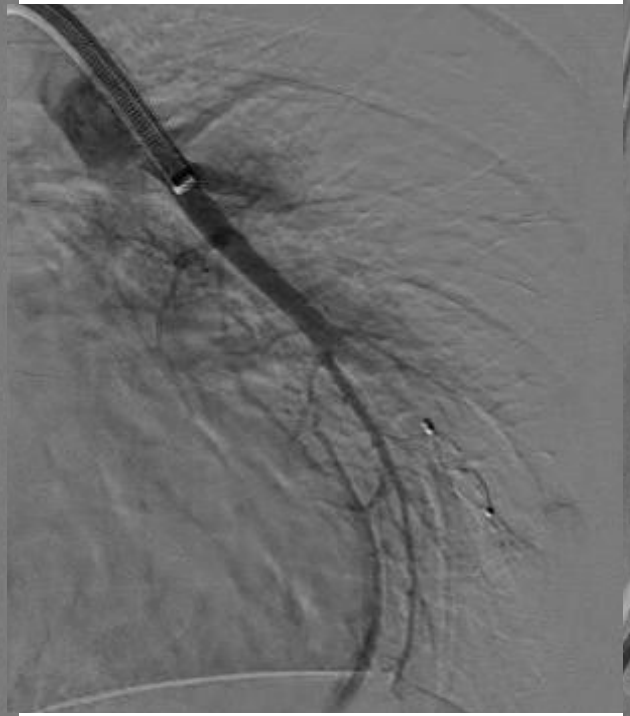


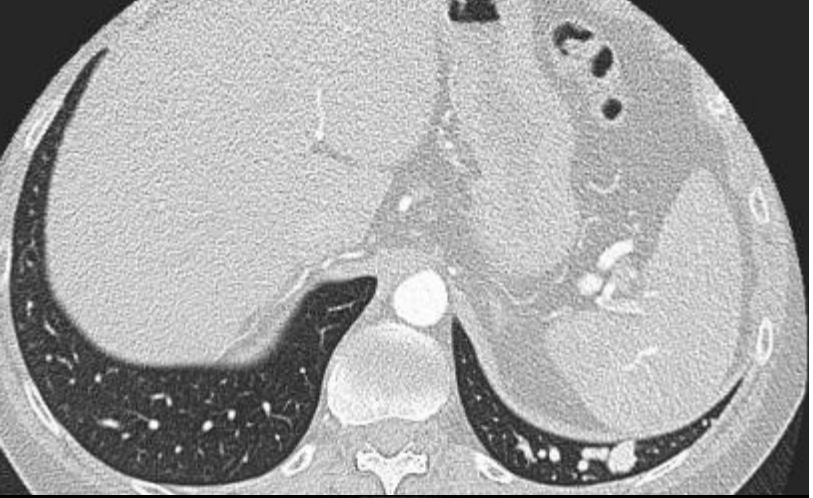





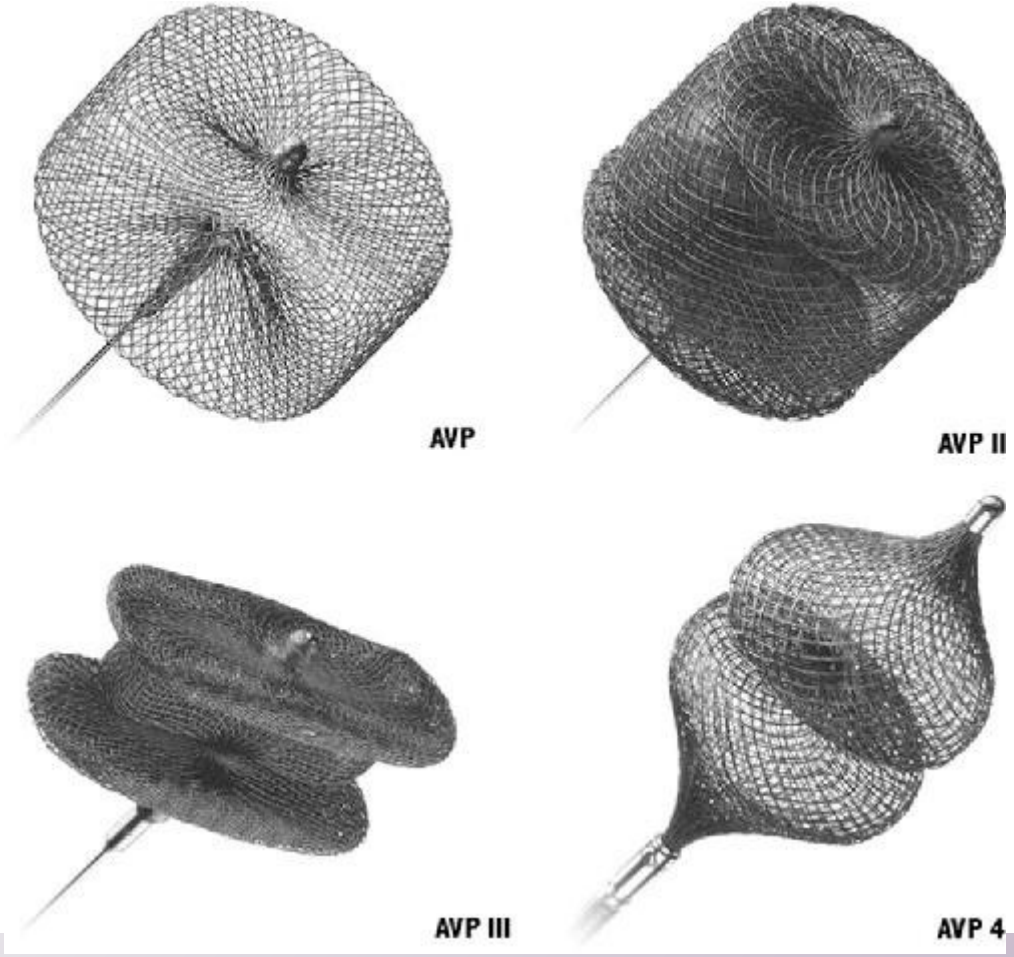
AVP
AVP II
AVP III
AVP 4



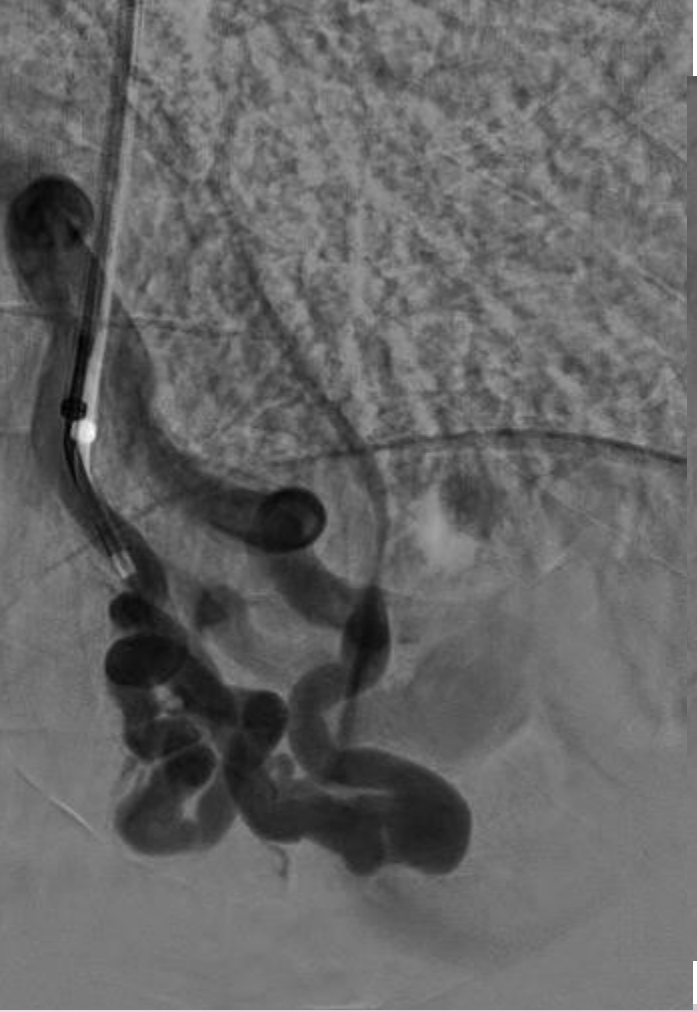



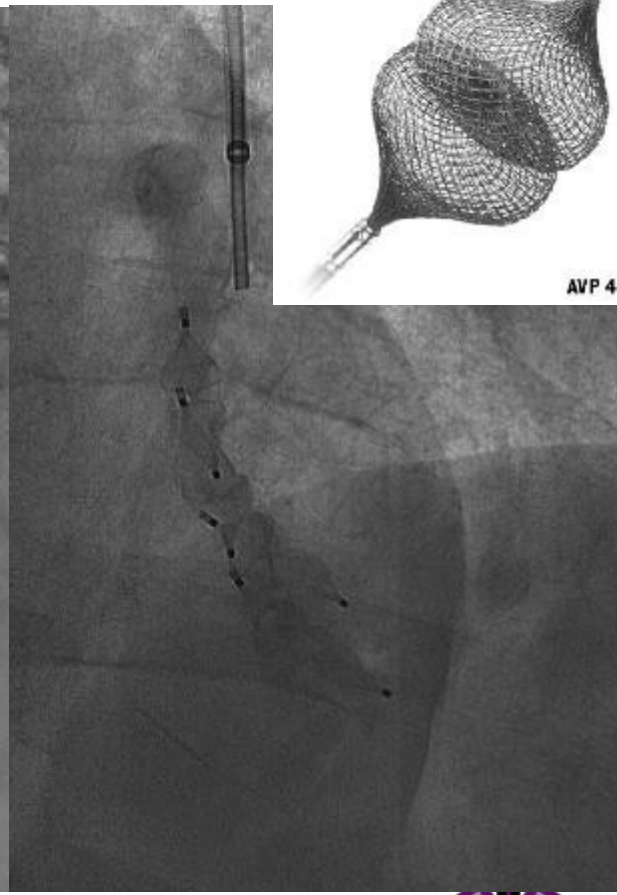

AVP 4

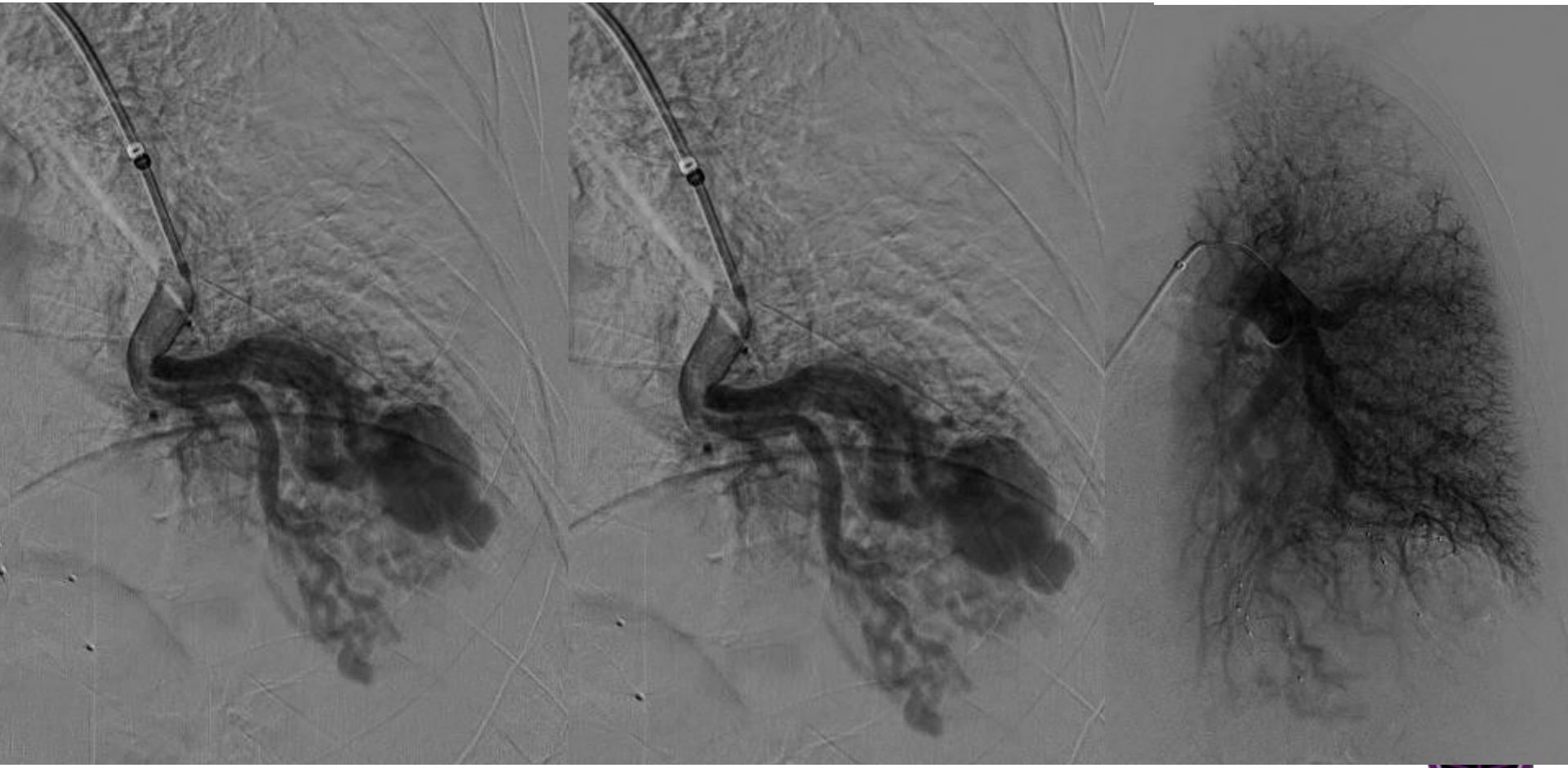

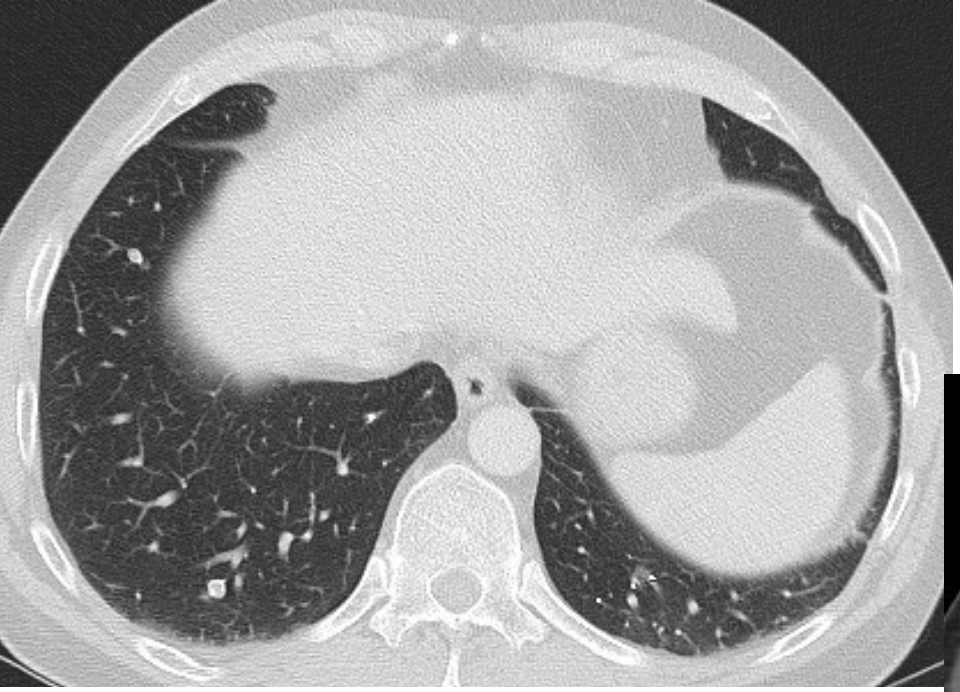




DFOV3
TILT


ADSICT13
12:10:
SE:15
IM:1
DFOV3
TILT



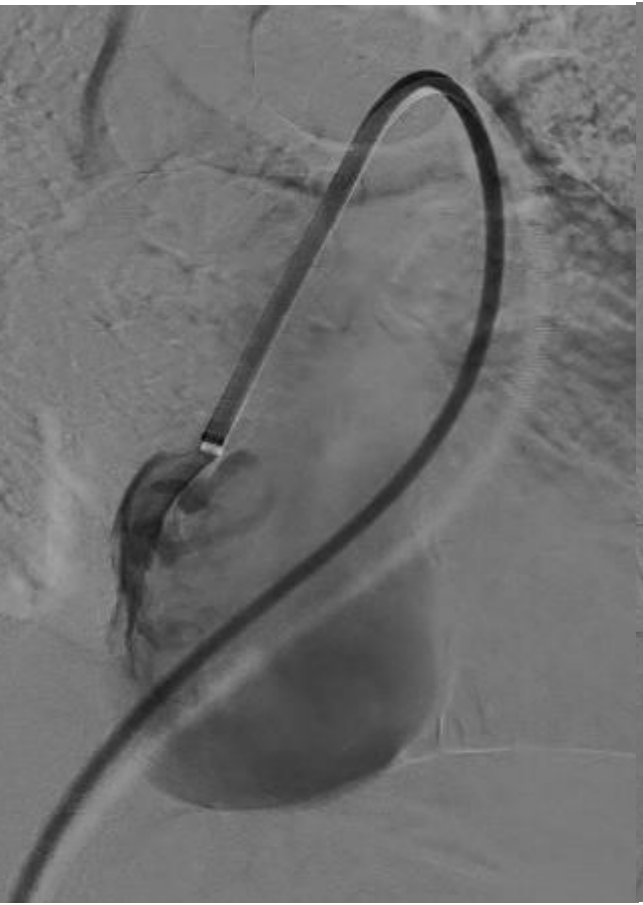
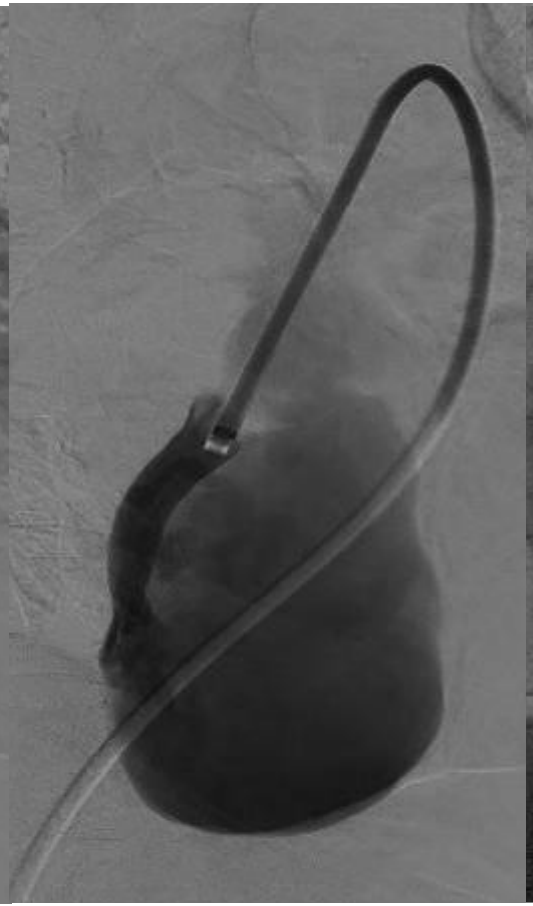
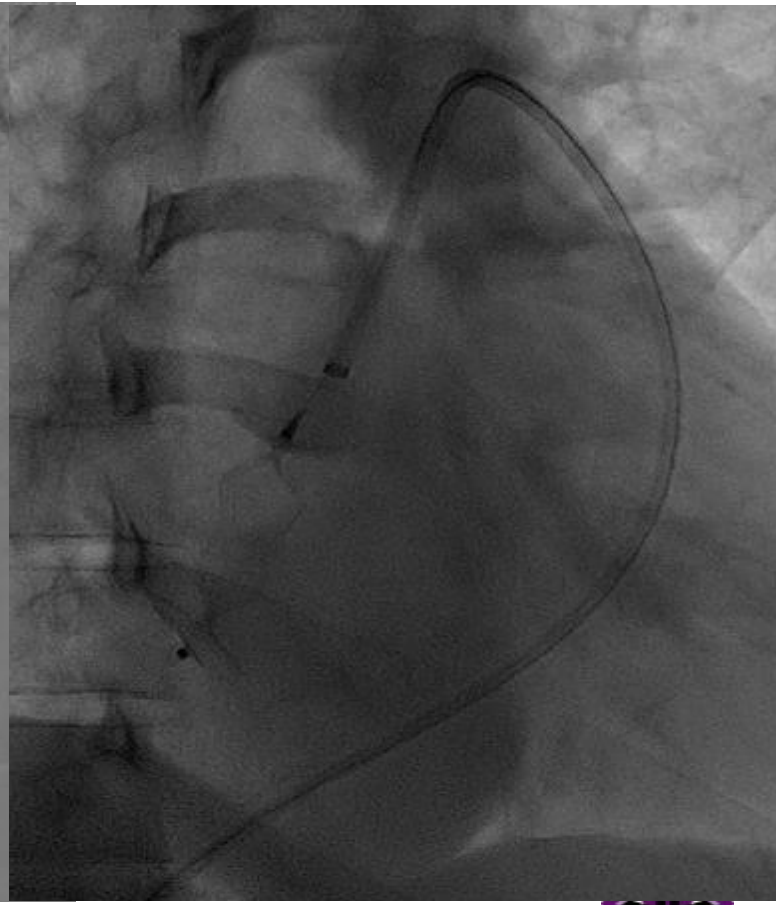



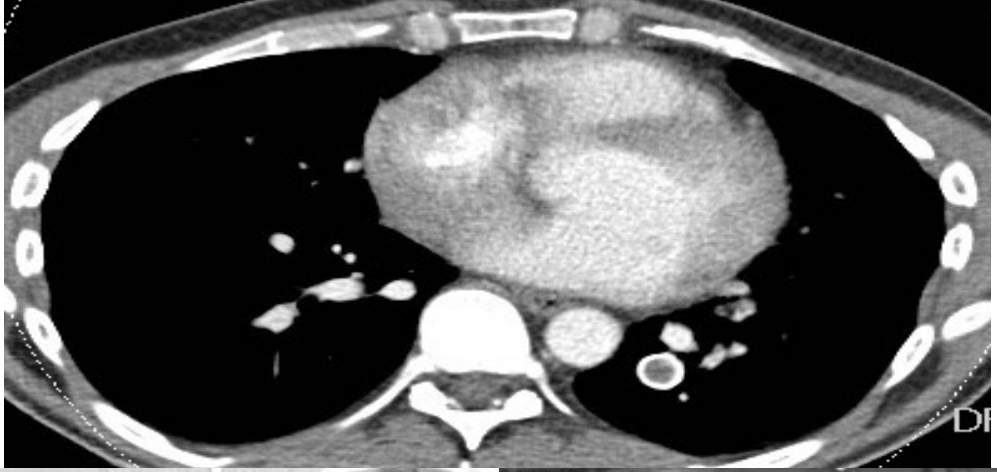

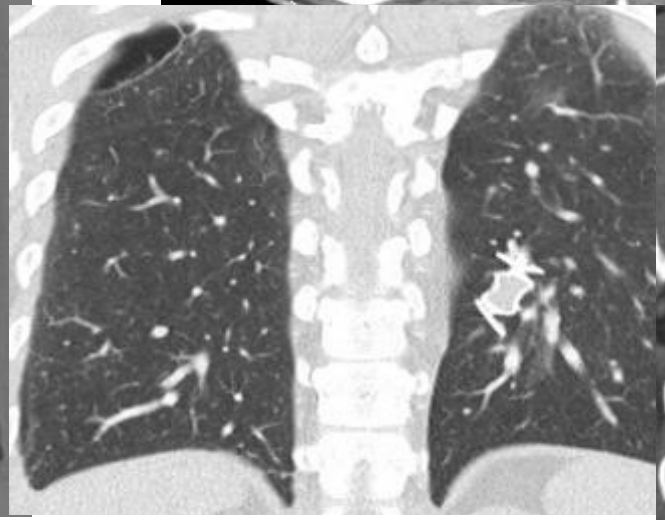

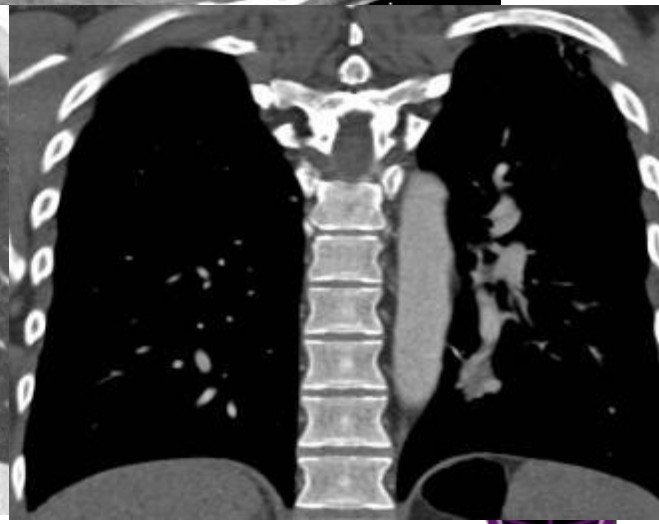

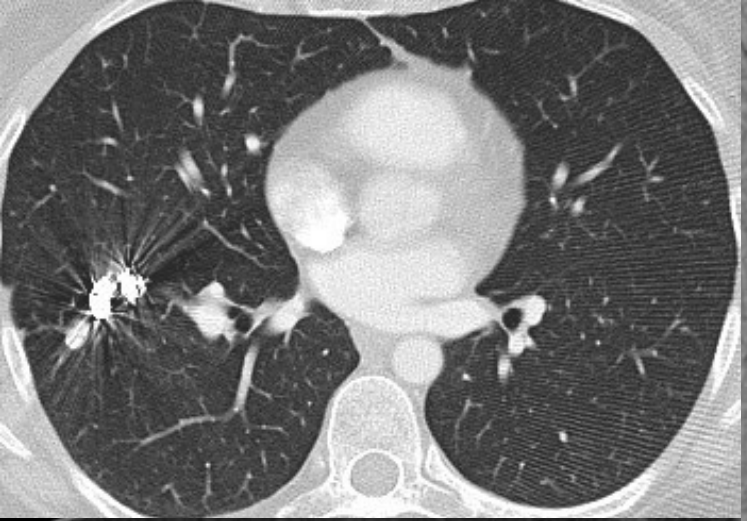



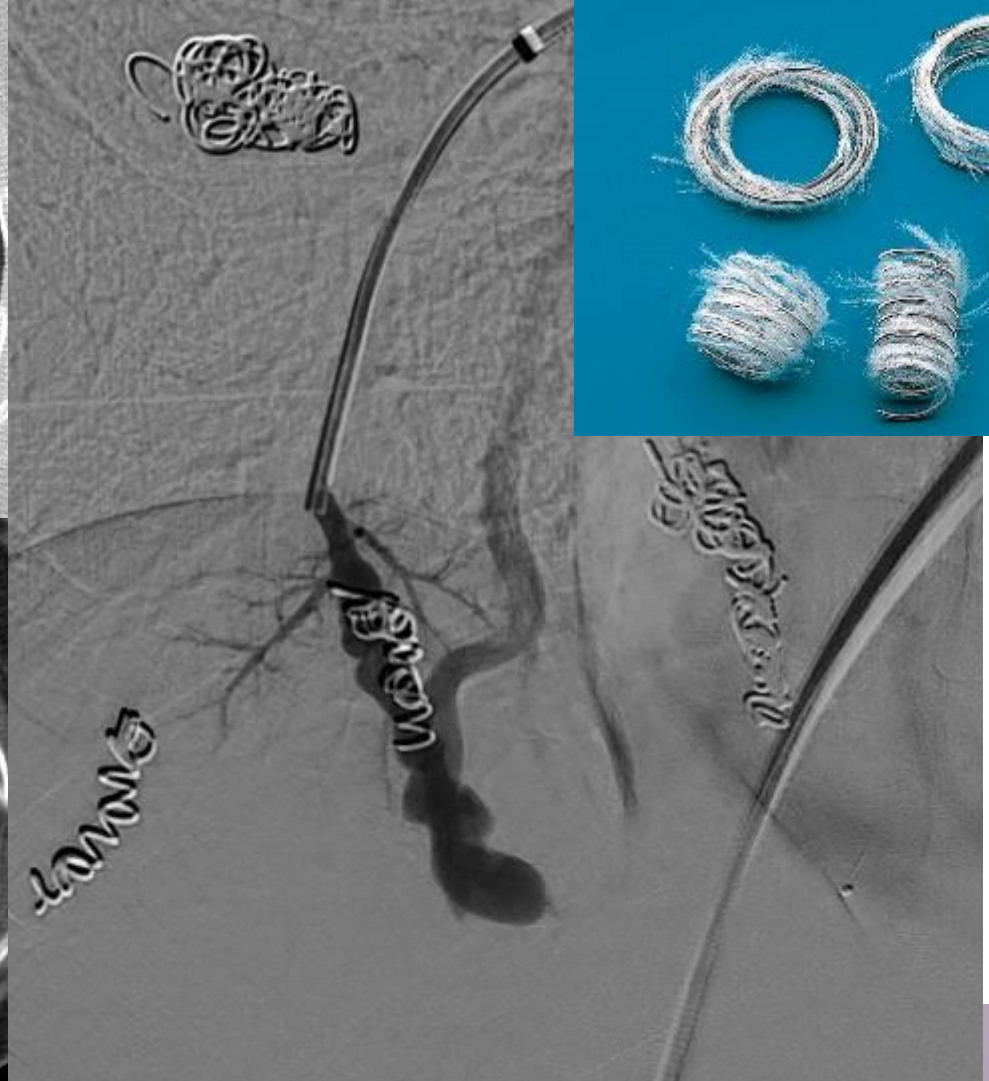

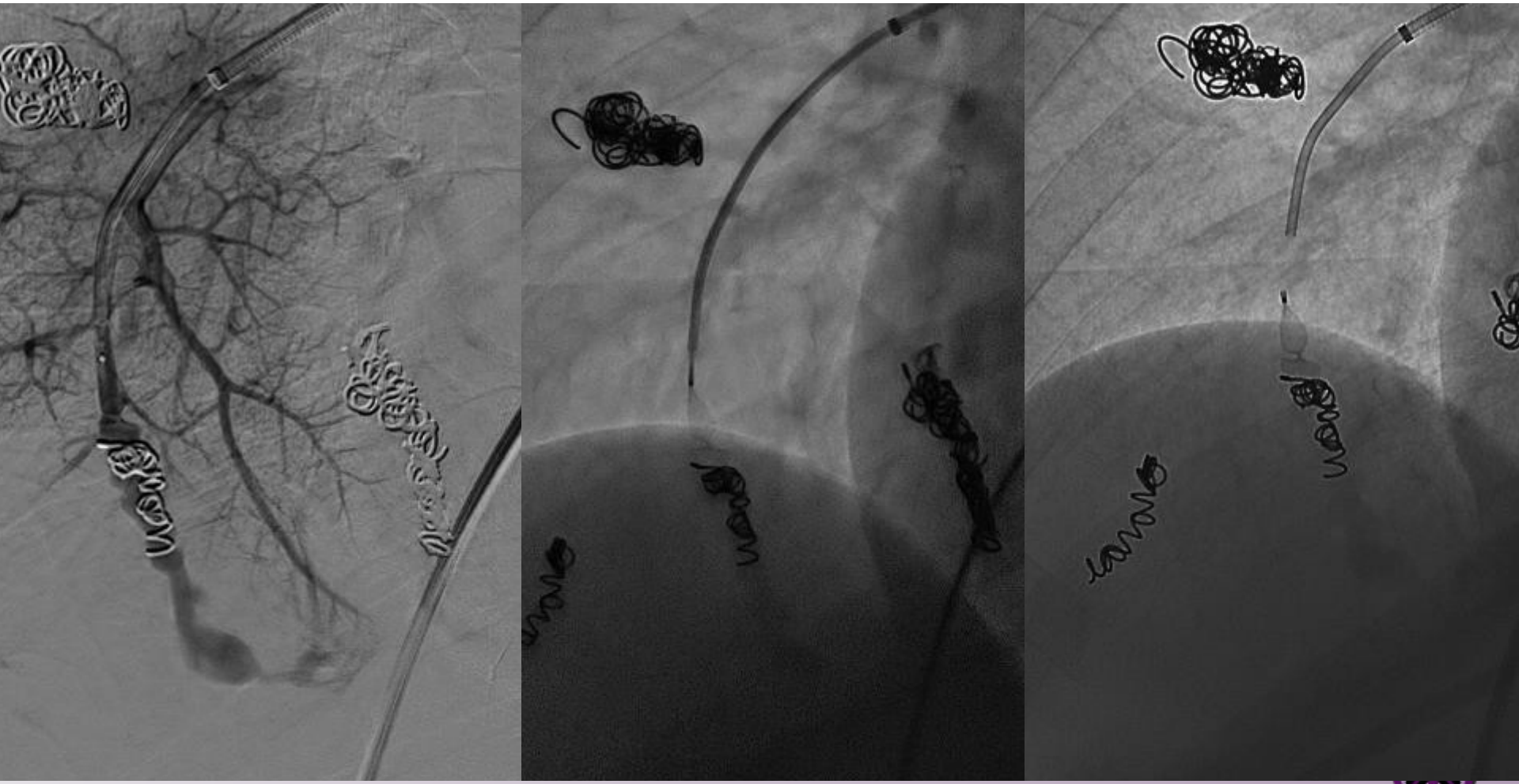

Study	Persistence (%)	Recanalization (%)	Previously Untreated Feeder (%)*	Systemic-to-Pulmonary Reperfusion (%)	Pulmonary-to-Pulmonary Reperfusion (%)	Success Rate in Retreatment (%)
Lee et al (3)	15 (8/52)	63 (5/8)	37 (3/8)	…	5 (3/60)	80 (4/5)
Mager et al (4)	8 (25/296)	…	…	…	…	…
Milic et al (5)	17 (33/194)	88 (29/33)	…	3 (1/33)	9 (3/33)	42 (14/33)
Pollak et al (6)	8 (11/144)	64 (7/11)	9 (1/11)	18 (2/11)	9 (1/11)	78 (7/9)
Prasad et al (7)	7% (18/267) for stainless steel coils; 10% (4/39) for platinum coils	50 (9/18) for stainless steel coils; 100 (4/4) for platinum coils	…	6 (1/18) for stainless steel coils	11 (2/18) for stainless steel coils	…
Remy-Jardin et al (9)	25 (16/64)	75 (12/16)	19 (3/16)	6 (1/16)	…	…
Trerotola and Pyeritz (15)	0 (0/37)	…	…	…	…	…
Present study	Not studied	91 (48/53)	15 (8/53)	0	25 (13/53)	84 (27/32) for recanalization; 44 (4/9) for reperfusion



Trerotola et al. Radiology 2013

Hepatische arterioveneuze malformaties

Screening

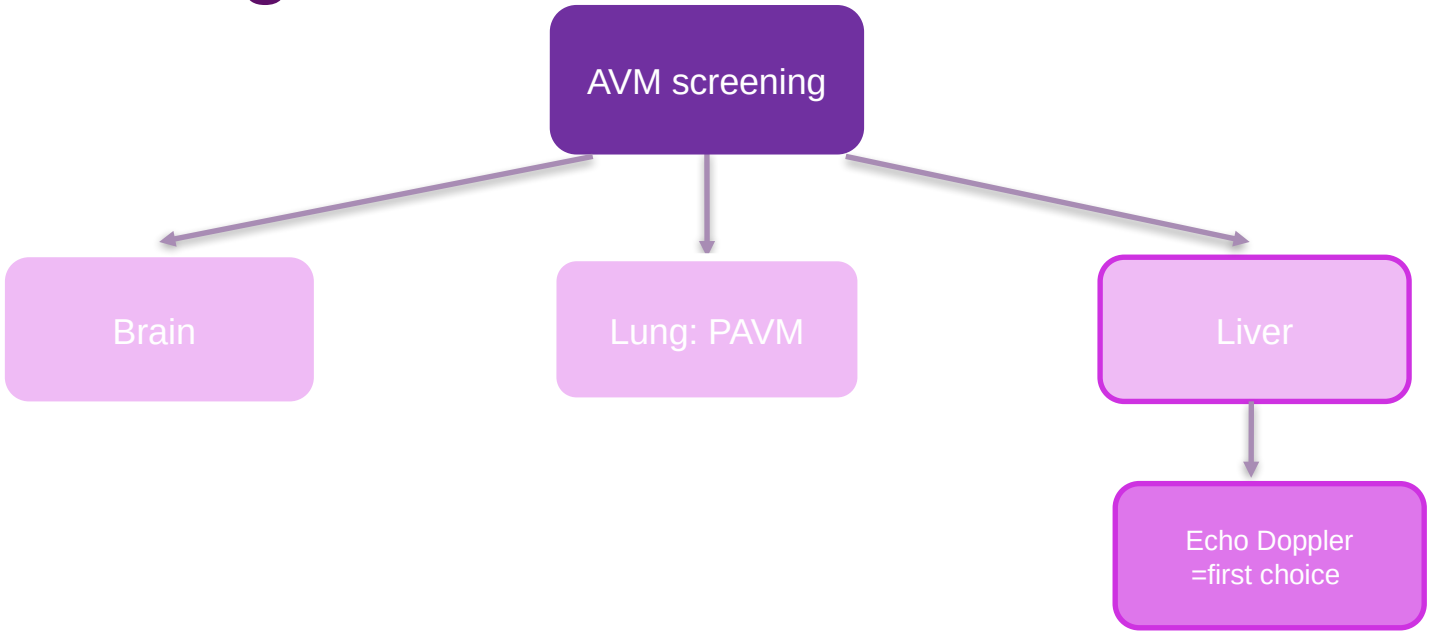

Based on Faughnan M, Ann Intern Med. 2020

Screening

VMs GRADE	Scheme	Doppler US findings
0+	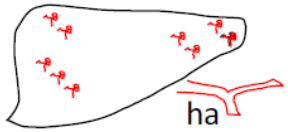	HA diameter > 5 < 6 mm, and/or PFV > 80 cm/s, and/or RI < 0.55, and/or Peripheral hepatic hypervascularization
1		HA dilatation, only extrahepatic > 6 mm, and PFV > 80 cm/s, and/or RI < 0.55
2	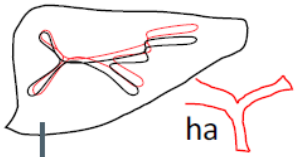	HA dilatation, extra- and intrahepatic ("double-channel" aspect) and PFV > 80 cm/s Possibly associated with moderate flow abnormality of hepatic and/or portal veins
3		Complex changes in hepatic artery and its branches (tortuous and tangled) with marked flow abnormalities Abnormality of hepatic and/or portal vein flow

Echo Doppler

VMs GRADE	Scheme	Doppler US findings
4	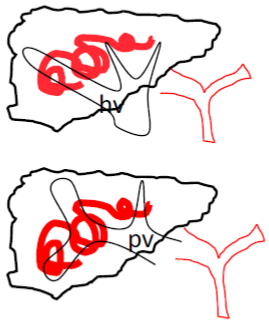	Decompensation of arteriovenous shunt with: Dilatation of hepatic and/or portal vein Marked flow abnormalities in both arteries and vein/s

Veno-venous shunts may be found and do not imply a VM up-grading. Nodular transformation of hepatic parenchyma progresses along with liver VMs severity, and it is generally found in grade 4
HA, hepatic artery; PV, portal vein; HV, hepatic vein

Screening

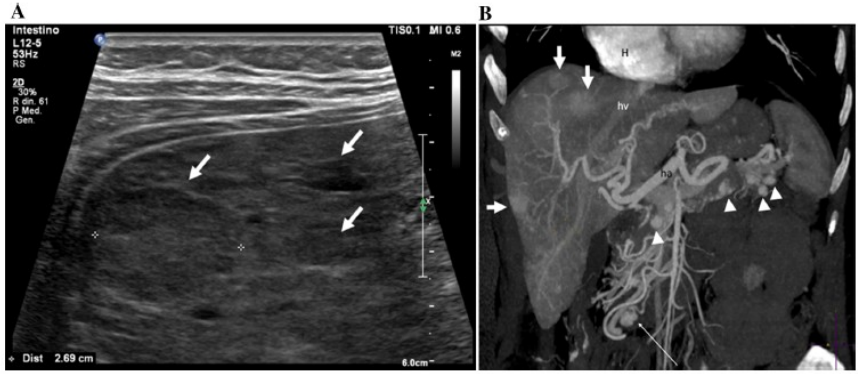

Fig. 6. **A** In a HHT patient with grade 3 liver VMs, US shows slightly hypoechoic oval lesions (arrows) of right liver lobe; **B** triple-phase CT angiography, arterial phase, shows prominent hepatic artery (ha) with tortuous intrahepatic branches, early enhancement of hepatic veins (hv) multiple enhancing nodules (arrows), diffuse VMs throughout the liver, pancreatic telangiectasias (arrowheads), and a VM with aneurysmal sac of duodenal wall (thin arrow). H, heart.

CT Lever

MRI lever

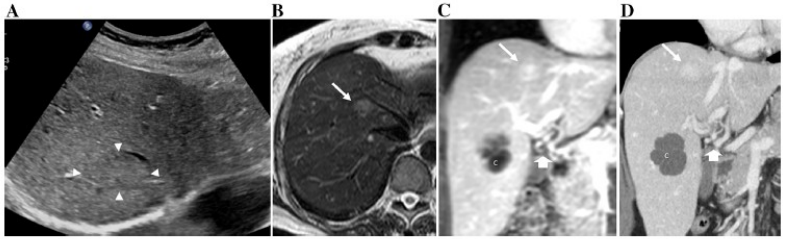

Fig. 7. In a HHT patient with grade 2 liver VMs **A** US shows an isoechoic oval lesion (arrowheads) close to the middle hepatic vein; **B** T2 weighed MR, axial image, showing a hyperintense liver lesion (arrow); **C** contrast-enhanced MR, venous phase, coronal image, showing sustained enhancement of the lesion (arrow); **D** triple-phase CT angiogram, venous phase, coronal image, showing superimposable findings, consistent with radiological characteristics of focal nodular hyperplasia (FNH). Large arrow, prominent arterial branches at the hilum; C, liver cyst.








0°
cm



Complicaties

- High-output hartfalen en pulmonale hypertensie
- Portale hypertensie
- Ischemische cholangitis

Aanpak

- Vocht- en zoutbeperking
- Diuretica
- Bevacizumab
- Levertransplantatie

Cerebrale vasculaire malformaties

Complicatie

- Epilepsie
- Ischemie
- Bloedingsrisico
- Ruptuur: 2-4%/jaar

Faughnan M. J Med Genet 2011, Willemse R. J Neurosurg 2000

Screening

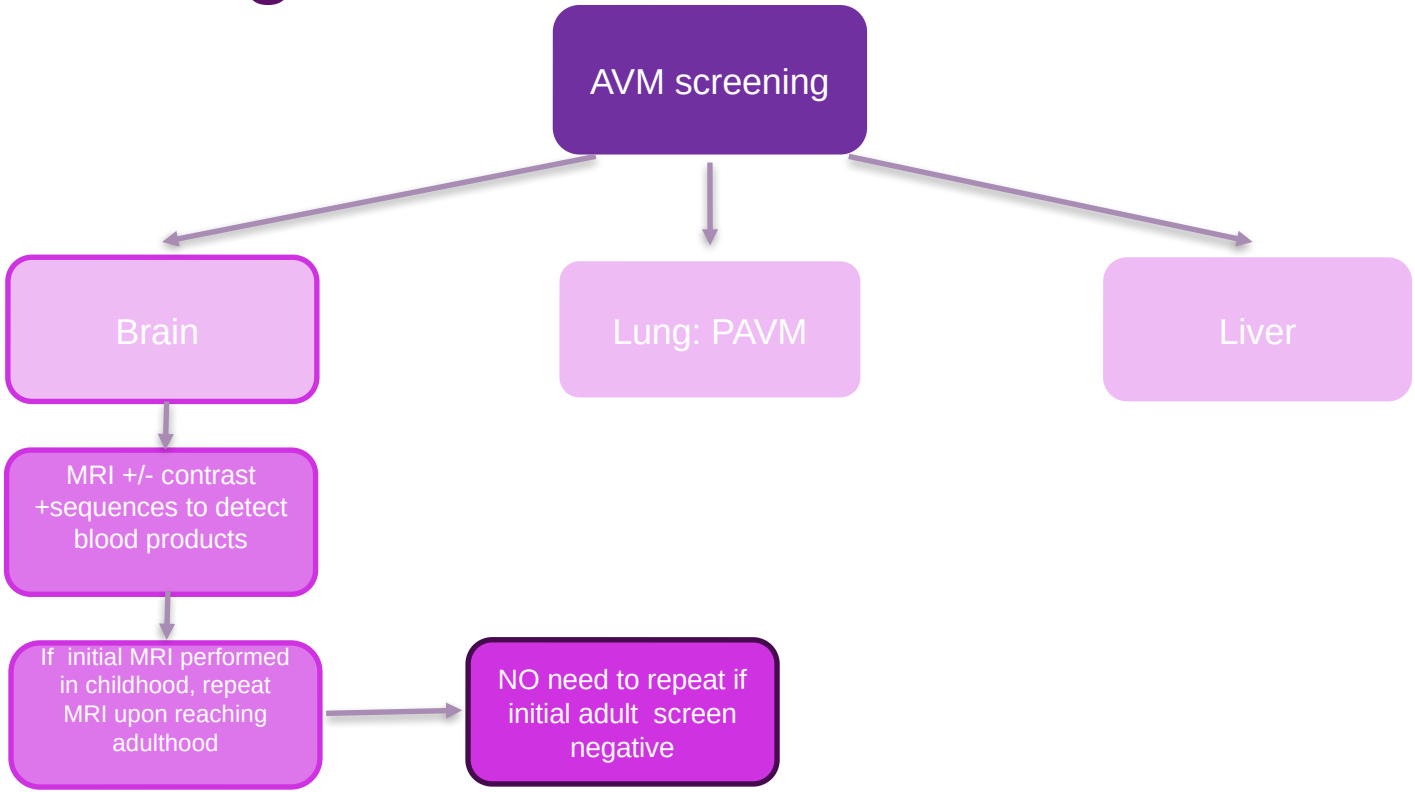

Based on Faughnan M, Ann Intern Med. 2020

Aanpak

Gezien soms spontaan favorabel verloop is verwijzing naar centrum met neurovasculaire expertise een must alvorens eventueel onnodige invasieve beeldvorming (catheter angiografie) te realiseren

Take home

- Levensbedreigende complicaties
- Vergeet AB profylaxe niet bij PAVM
- DENK AAN HHT /ROW



EPISTAXIS

OUDE en NIEUWERE therapieën

Peter W. Hellings

STAPSGEWIJZE BENADERING

1° Conservatief:

- preventieve maatregelen
- wees voorbereid
- Rapid Rhino°

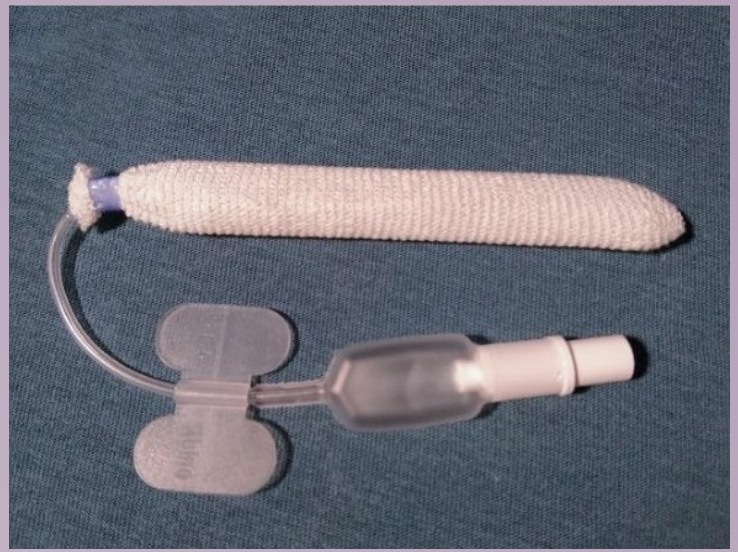

STAPSGEWIJZE BENADERING

2° Bij acute bloeding:

- vermijd manipulaties
- compressie van de neus
- resorbeerbaar compressie materiaal (+ AB dekking)
- (chemische of thermische cauterisatie)

STAPSGEWIJZE BENADERING

3° Therapeutische opties

Saunders’ dermoplasty
(evidentiegraad C)

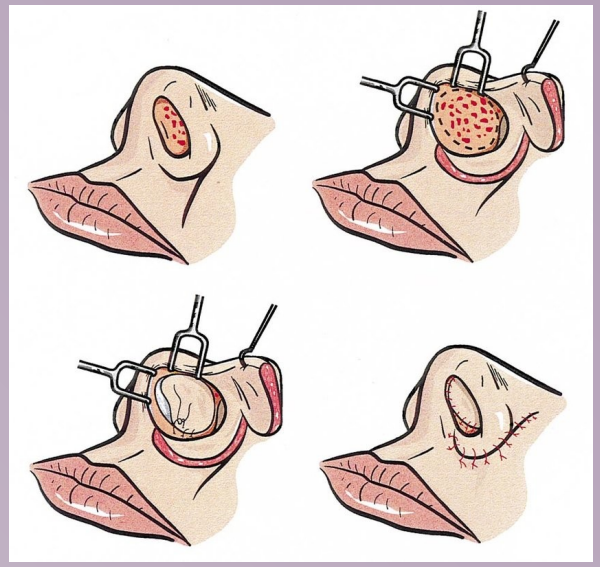

STAPSGEWIJZE BENADERING

3° Therapeutische opties

Young procedure

* indicatie
* weinig esthetische impact

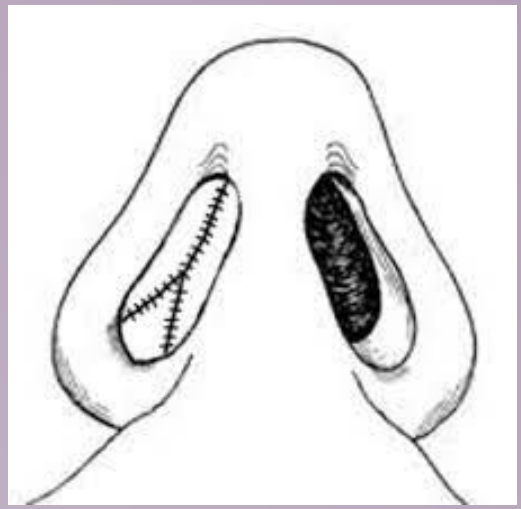

NIEUWE OPTIES

Injecties met fibrinelijm (Tissucol°)

Injectie met scleroserende molecules (aetoxiscerol)

Haemostatische gel (Surgiflo°)

Laser en radiofrequentie

Heden en Toekomst

- Ondersteunende maatregelen
- Interventies: Saunders’ or Youngs’ procedure
- Medische therapie:
  - Tranexaminezuur (Exacyl°, evidentieniveau B)
  - Bevacizumab (Avastin°, evidentieniveau B)



Rendu-Osler-Weber
Oude en Nieuwe therapieën
Multidisciplinaire Aanpak

Peter Verhamme
Bloedings- en Vaatziekten

ROW

- Progressieve “bloedings- en vaatziekte”
- Geen adequate medische therapie
- Procedurele behandeling van
  - Epixtaxis
  - Arterioveneuze malformaties

Medische behandeling

- Antifibrinolytische therapie (Tranexaminezuur 3x1g/d)
- Hormonale therapie (Tamoxifen)
- Anti-angiogene therapie (Thalidomide)

Anti-angiogene therapie

- Anti-VEGF (Bevacizumab)

An international, multicenter study of intravenous bevacizumab for bleeding in hereditary hemorrhagic telangiectasia: the InHIBIT-Bleed study

- Retrospectieve studie
- 238 pt; mediane opvolging 12 mnd
- Bevacizumab 5 mg/kg (/2weken ✉/4weken)

Haematologica 2021
Volume 106(8):2161-2169

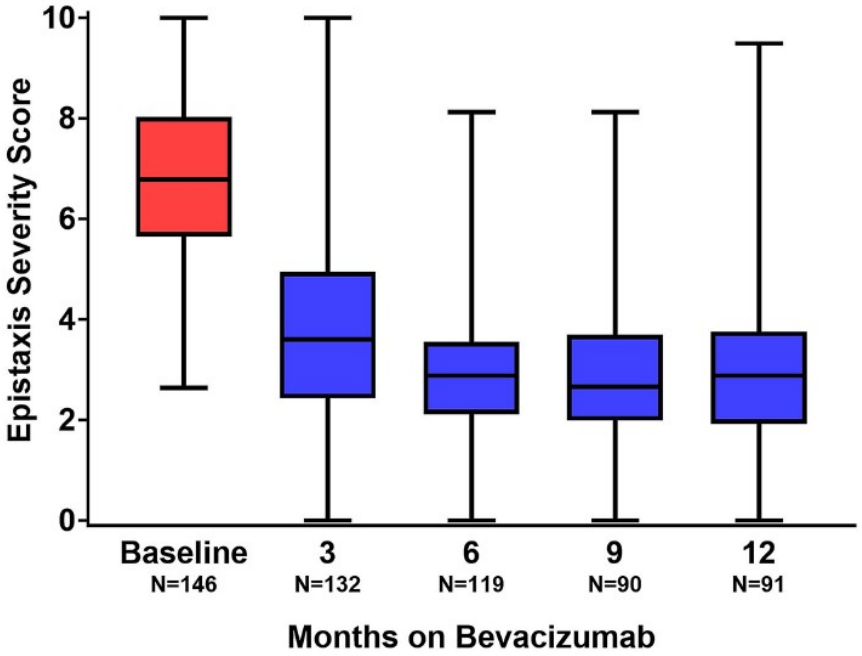
Epistaxis Severity Score
10
8
6
4
2
0
Baseline
N=146
3
N=132
6
N=119
9
N=90
12
N=91
Months on Bevacizumab

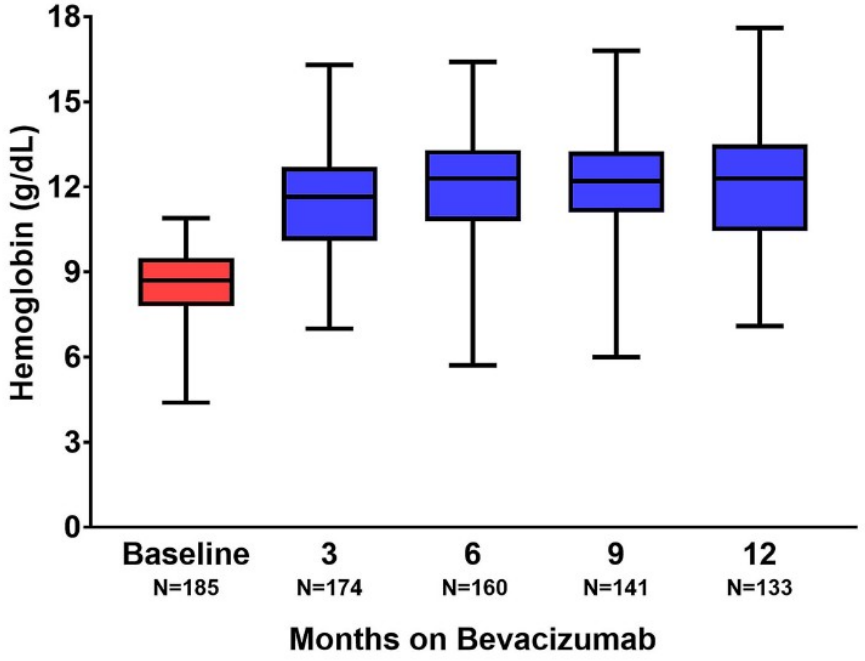
Hemoglobin (g/dL)
18
15
12
9
6
3
0
Baseline
N=185
3
N=174
6
N=160
9
N=141
12
N=133
Months on Bevacizumab

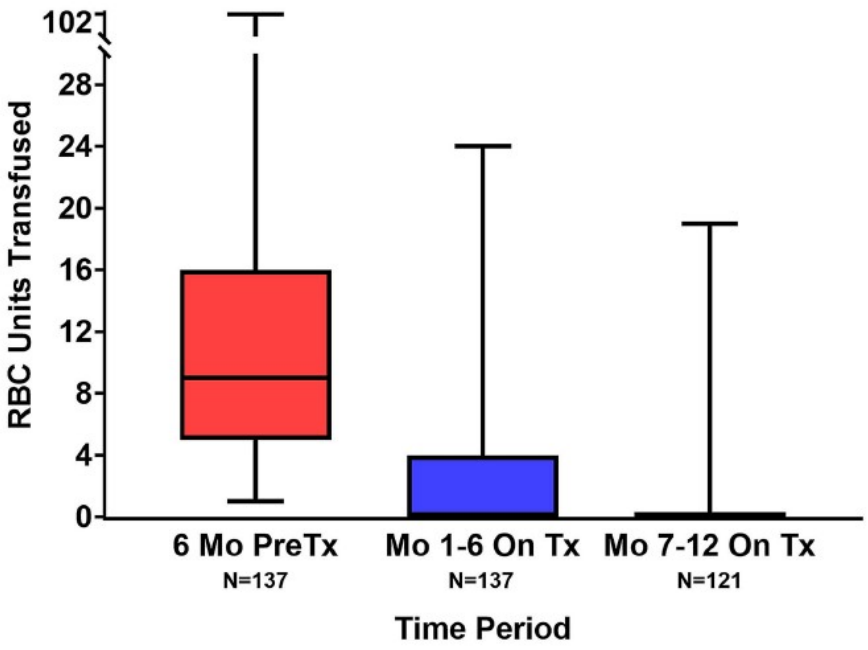
RBC Units Transfused
102
28
24
20
16
12
8
4
0
6 Mo PreTx
N=137
Mo 1-6 On Tx
N=137
Mo 7-12 On Tx
N=121
Time Period

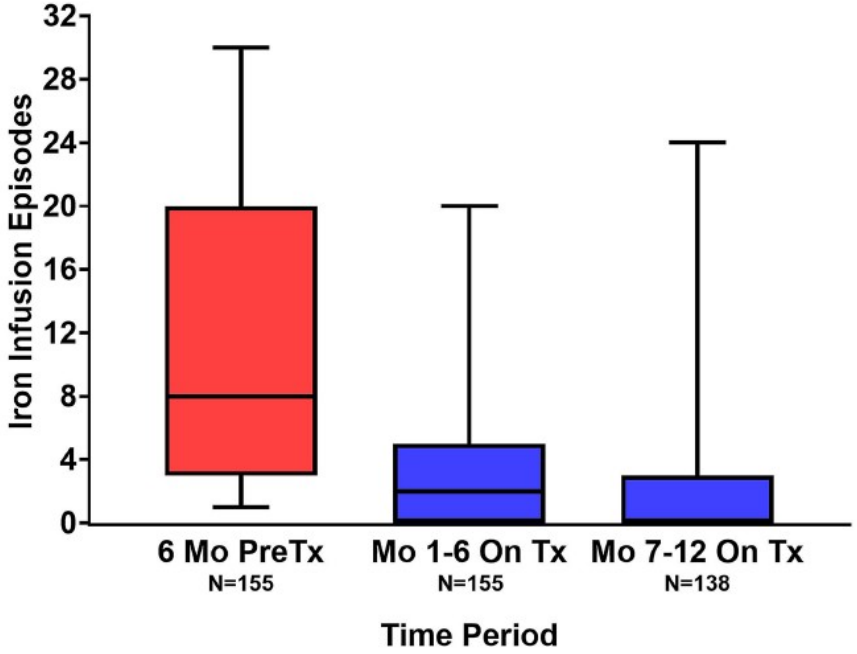
Iron Infusion Episodes
32
28
24
20
16
12
8
4
0
6 Mo PreTx
N=155
Mo 1-6 On Tx
N=155
Mo 7-12 On Tx
N=138
Time Period

TEAE	Number of patients (%)
Hypertension (new-onset or worse from baseline)	41 (18%)[a]
Fatigue	23 (10%)
Proteinuria	21 (9%)[b]
Myalgia and/or arthralgia	14 (6%)
Headache	9 (4%)
Venous thromboembolism	5 (2%)



Systemic bevacizumab to treat refractory bleeding in hereditary haemorrhagic telangiectasia: A single centre case series

J. Nelissen, MD[1], K.L. Wu, MD, PhD[2], N. Granacher, MD[2], D. Breems, MD, PhD[2]

	Case 1	Case 2	Case 3
Gender, age (years)	Female, 57	Female, 64	Male, 54
Mean haemoglobin 6 months prior to bevacizumab	8.5 g/dl	9.9 g/dl	9.0 g/dl
Mean haemoglobin 6 months after induction therapy with bevacizumab	11.6 g/dl	14.6 g/dl	13.2 g/dl
Iron infusions 6 months prior to bevacizumab (mg elemental iron)	6000 mg	4000 mg	13 000 mg
Iron infusions 6 months after induction therapy with bevacizumab (mg elemental iron)	2000 mg	1000 mg	600 mg
Number of haemostatic procedures 1 year prior to bevacizumab	3	0	7
Number of haemostatic procedures 6 months after bevacizumab	1	0	0
Treatment-emergent adverse events	Arterial hypertension	Arterial hypertension	Arterial hypertension

(BELG J HEMATOL 2023;14(3):135-8)

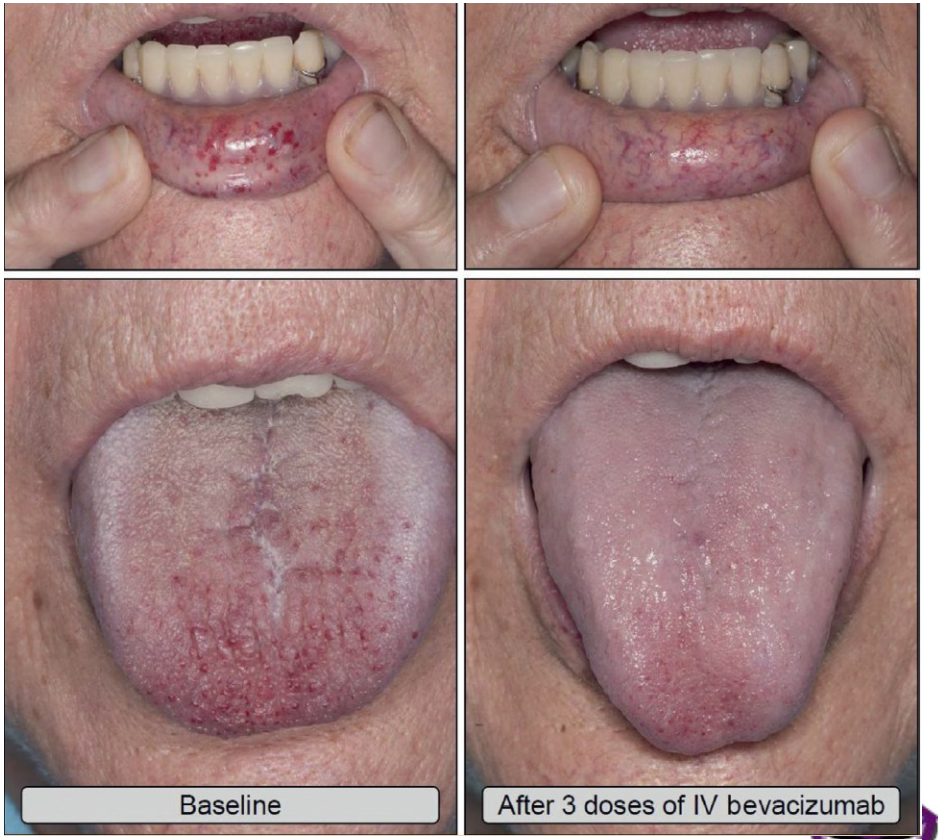

Mayo Clin Proc. 2018;93(2):155-166



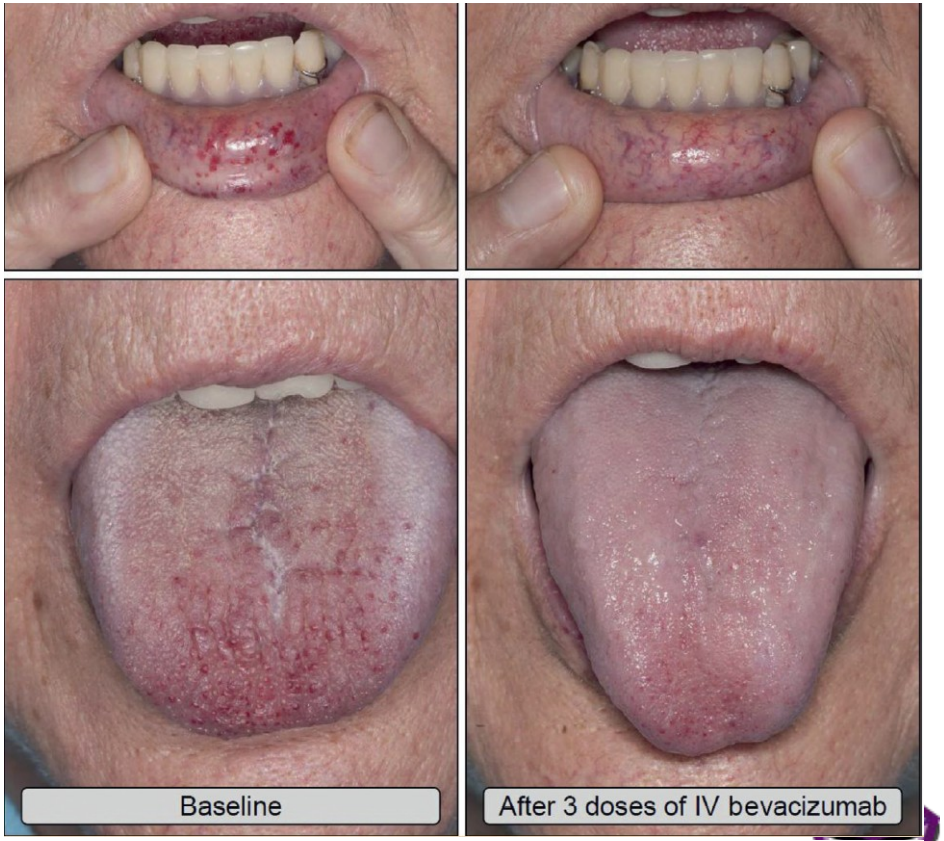

Mayo Clin Proc. 2018;93(2):155-166

Anti-angiogene therapie

- Anti-VEGF (Bevacizumab)
  - 5mg/kg /2 weken ✉ /4-12 weken
  - Monitor Bloedformule, Ijzerreserve, Bloeddruk en Proteinurie
  - Hoe selecteren?

Anti-angiogene therapie

- Anti-VEGF (Bevacizumab)
  - Non-responders?
  - Laattijdig falen? Laattijdige neveneffecten?
  - Intraveneus
  - Impact op arterioveneuze malformaties (long, lever)?

Anti-angiogene therapie

- Anti-VEGF (Bevacizumab)
- Tyrosine kinase inhibitoren (Pazopanib)
- Pomalidomide
- AKT-inhibitor (VAD044)

- Octreotide
- Sirolimus / Tacrolimus

Anti-angiogene therapie: Pazopanib

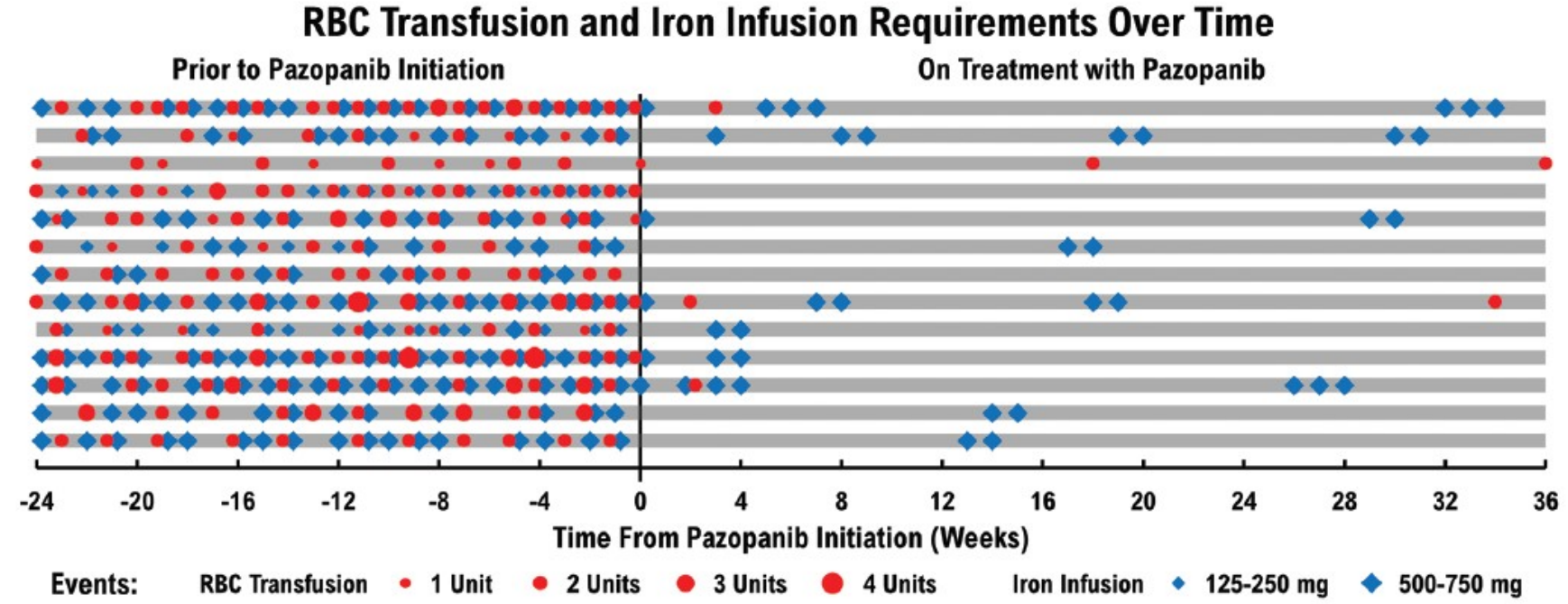

Semin Thromb Hemost 2022;48:514–528.

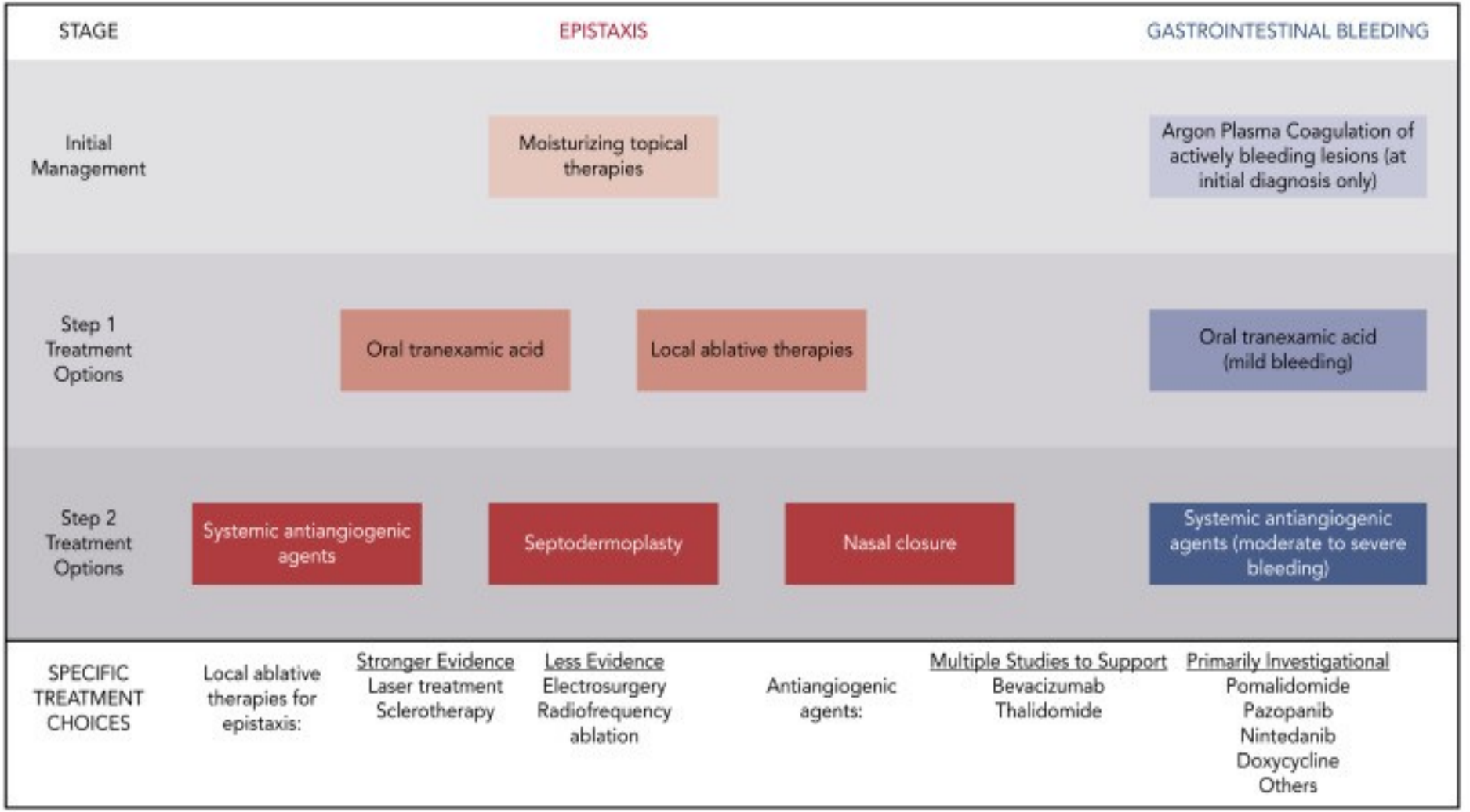
STAGE
EPISTAXIS
GASTROINTESTINAL BLEEDING
Initial Management
Moisturizing topical therapies
Argon Plasma Coagulation of actively bleeding lesions (at initial diagnosis only)
Step 1 Treatment Options
Oral tranexamic acid
Local ablative therapies
Oral tranexamic acid (mild bleeding)
Step 2 Treatment Options
Systemic antiangiogenic agents
Septodermoplasty
Nasal closure
Systemic antiangiogenic agents (moderate to severe bleeding)
SPECIFIC TREATMENT CHOICES
Local ablative therapies for epistaxis:
Stronger Evidence
Laser treatment
Sclerotherapy
Less Evidence
Electrosurgery
Radiofrequency ablation
Antiangiogenic agents:
Multiple Studies to Support
Bevacizumab
Thalidomide
Primarily Investigational
Pomalidomide
Pazopanib
Nintedanib
Doxycycline
Others

Ziekte van Rendu-Osler-Weber

- Oplossingen op Maat
  - Screening
  - Diagnostiek en Opvolging
  - Procedurele behandelingen
  - Medische therapieën

- Multidisciplinaire Opvolging

Zorgprogramma Rendu-Osler-Weber

Hereditaire hemorragische teleangiëctasieën (HHT)

Pediatrie	prof. dr. Veerle Labarque, prof. dr. Chris Van Geet
Bloedings- en vaatziekten	prof. dr. Peter Verhamme, prof. dr. Thomas Vanassche
Cardiologie	prof. dr. Werner Budts, prof. dr. Pieter De Meester
Centrum menselijke erfelijkheid	prof. dr. Jeroen Breckpot
Dermatologie	prof. dr. An Van Laethem
Hematologie	Prof. dr. Timothy Devos
Interventionele radiologie	prof. dr. Geert Maleux, dr. Jo Peluso, dr. Lawrence Bonne
Maag-, darm- en leverziekten	prof. dr. Wim Laleman, prof. Chris Verslype, prof. Ingrid Demedts
Neurochirurgie	prof. dr. Steven De Vleeschouwer, prof. dr. Johannes van Loon
Neus-, keel- en oorziekten	prof. dr. Peter Hellings
Pneumologie	prof. dr. Catharina Belge, prof. dr. Marion Delcroix

Gespecialiseerd Verpleegkundige ROW	Johan De Bent, Johan Vandesande

www.uzleuven.be/ROW - ROW@uzleuven.be