UZ LEUVEN

Imaging and COVID-19

W De Wever

J Verschakelen, J Coolen, A Dubbeldam

April 9, 2020

University Hospitals - Dept of Radiology
Leuven, Belgium
www.chestradiology.info

PENTALFA

MULTIDISCIPLINAIR INTERACTIEF
POSTGRADUAAT AFSTANDSONDERWIJS

Imaging and COVID-19

- “Guidelines”
- CT findings and CT reporting
- Results UZ Leuven
- Conclusion

Imaging: Low-dose chest CT

Radiology. 2020 Feb 26:200642. doi: 10.1148/radiol.2020200642. [Epub ahead of print]

Correlation of Chest CT and RT-PCR Testing in Coronavirus Disease 2019 (COVID-19) in China: A Report of 1014 Cases.

Ai T[1], Yang Z[1], Hou H[1], Zhan C[1], Chen C[1], Lv W[1], Tao Q[1], Sun Z[1], Xia L[1].

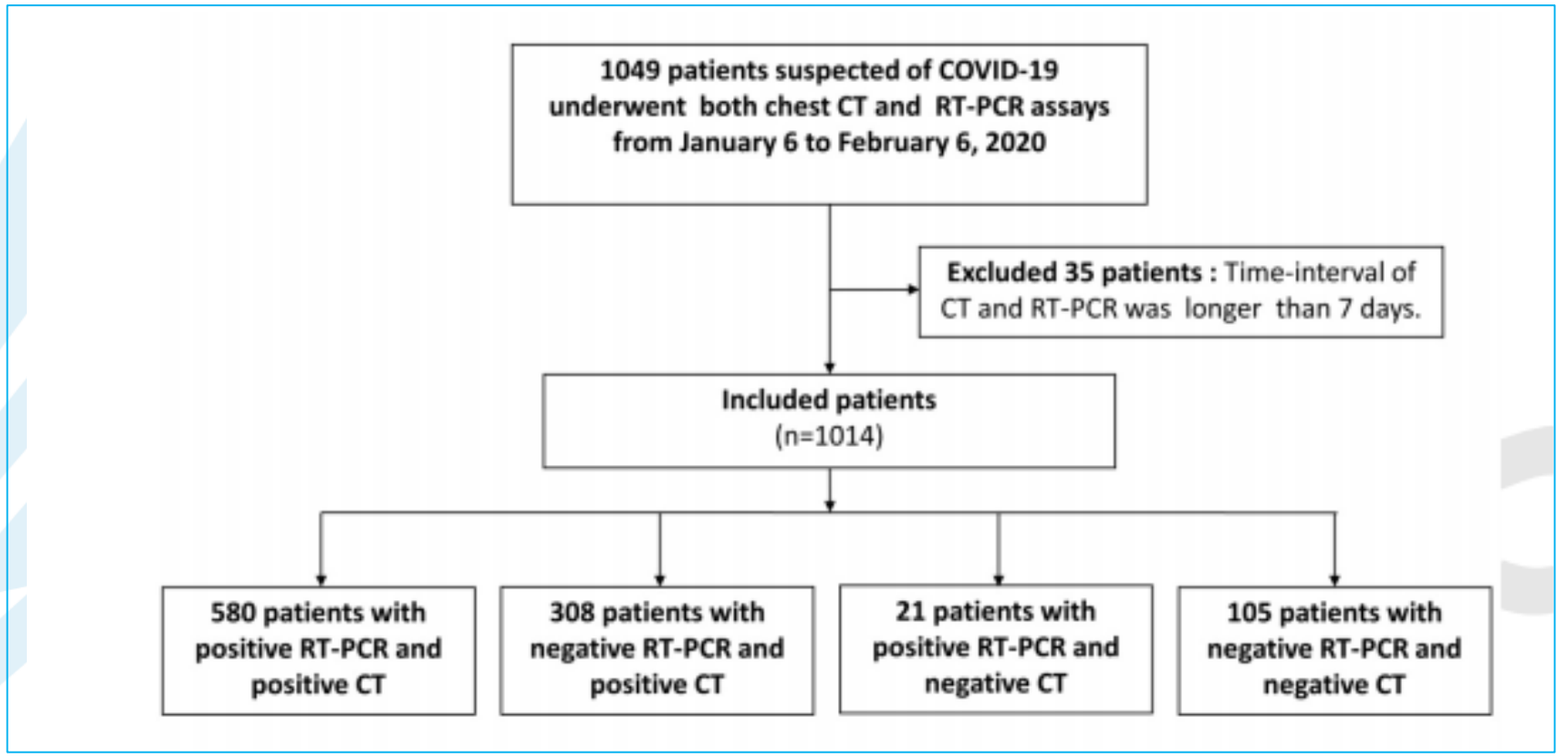

RT-PCR= reverse transcription polymerase chain reaction.

Table 2: The performance of chest CT for COVID-19 infection with RT-PCR result as reference.

	Results (n)				Test performance (%)					
	TP	TN	FP	FN	Sensitivity [95% CI]	Specificity [95% CI]	PPV [95% CI]	NPV [95% CI]	Accuracy [95% CI]	
Overall										
	580	105	308	21	97 (580/601) [95-98]	25 (105/413) [22-30]	65 (580/888) [62-68]	83 (105/126) [76-89]	68 (685/1014) [65-70]	
Age										
< 60 years	362	81	225	15	96 (362/377) [94-98]	27 (81/306) [22-32]	62 (362/587) [58-66]	84 (81/96) [76-90]	65 (443/683) [61 -68]	
≥ 60 years	218	24	83	6	97 (218/224) [94 -99]	22 (24/107) [16-31]	72 (218/301) [67-77]	80 (24/30) [63-91]	73 (242/331) [68-78]	
Sex										
Male	272	35	148	12	96 (272/284) [93-98]	19 (35/183) [14-25]	65 (272/420) [60-69]	75 (35/47) [61-85]	66 (307/467) [61-70]	
	308	70	160	9	97 (308/317) [95-99]	30 (70/230) [25-37]	66 (308/468) [61-70]	89 (70/79) [80-94]	69 (378/547) [65 -73]	
Female										

Radiology. 2020 Feb 26:200642. doi: 10.1148/radiol.2020200642. [Epub ahead of print]

Correlation of Chest CT and RT-PCR Testing in Coronavirus Disease 2019 (COVID-19) in China: A Report of 1014 Cases.

Ai T[1], Yang Z[1], Hou H[1], Zhan C[1], Chen C[1], Lv W[1], Tao Q[1], Sun Z[1], Xia L[1].

Imaging: Yes or No? Chest X-ray or CT

BELGIAN SOCIETY OF RADIOLOGY

COVID 19 guidelines for radiologists

please do not reply to this e-mail

2020-03-31

General remarks:

- Preferred imaging technique for Covid-19: (low-dose) chest CT
- CT should not be used as a diagnostic test to replace PCR testing
- When CT is used in specific indications for 'triage', this should always be followed by PCR testing
- Radiologists should be actively involved in multidisciplinary teams that decide on workflow of Covid-19 patients



General population, asymptomatic	→	No imaging
Emergency Department	Clinical suspicion Covid-19, but no need for hospitalization	→ No imaging
	Clinical suspicion Covid-19, hospitalized to triage-ward or isolation ward	→ CT (depending on clinical need)
	Patients with 'acute' pathology who need urgent surgery, intubation, invasive therapies,…	→ Consider (low-dose) chest CT
	Patients who will be hospitalized with high risk of infection, including patients with comorbidities (f.e. geriatric patients), or specific patient groups (f.e. neutropenic patients, …), …	→ Consider (low-dose) chest CT
Hospitalized patients Covid +	→	Imaging when clinical deterioration In general, no follow-up imaging to determine regression of findings

General remarks:

- Preferred imaging technique for Covid-19: (low-dose) chest CT
- CT should not be used as a diagnostic test to replace PCR testing
- When CT is used in specific indications for 'triage', this should always be followed by PCR testing
- Radiologists should be actively involved in multidisciplinary teams that decide on workflow of Covid-19 patients

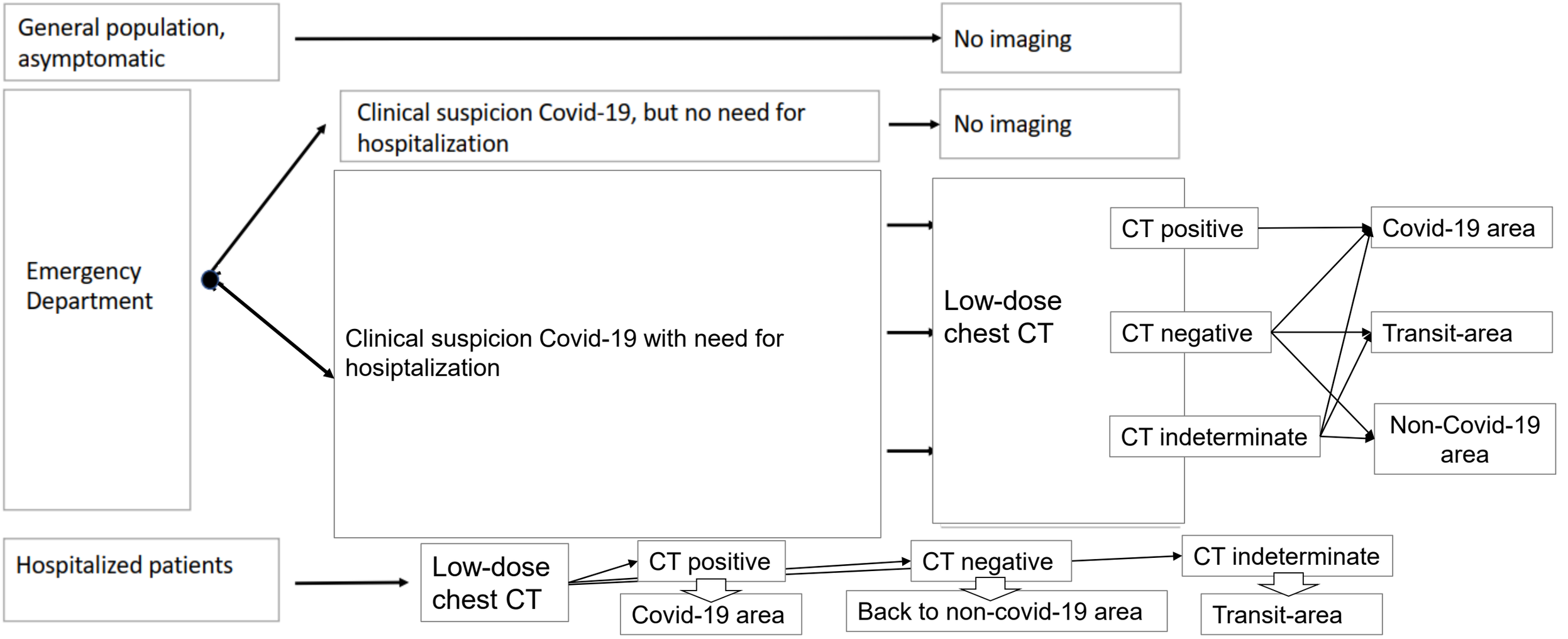

CT Findings

TABLE 2: Imaging Findings (continued)

Characteristic or Finding	All Patients (*n* = 101)	Nonemergency Group (*n* = 87)	Emergency Group (*n* = 14)	*p*
Imaging finding				
Ground-glass opacities	87 (86.1)	73 (83.9)	14 (100)	0.106
Consolidation	44 (43.6)	36 (41.4)	8 (57.1)	0.270
Mixed ground-glass opacities and consolidation	65 (64.4)	56 (64.4)	9 (64.3)	0.995
Centrilobular nodules	23 (22.8)	20 (23.0)	3 (21.4)	0.897
Architectural distortion	22 (21.8)	16 (18.4)	6 (42.8)	0.040
Bronchial wall thickening	29 (28.7)	22 (25.3)	6 (42.8)	0.173
Reticulation	49 (48.5)	39 (44.8)	9 (64.3)	0.176
Subpleural bands	28 (27.7)	23 (26.4)	4 (28.6)	0.867
Traction bronchiectasis	53 (52.5)	41 (47.1)	12 (85.7)	0.007
Intrathoracic lymph node enlargement	1 (1.0)	0 (0)	1 (7.1)	0.012
Vascular enlargement	72 (71.3)	59 (67.8)	13 (92.9)	0.109
Pleural effusions	14 (13.9)	9 (10.3)	5 (35.7)	0.011
Craniocaudal distribution				0.258
Upper lung predominant	6 (5.9)	6 (6.9)	0 (0)	
Lower lung predominant	55 (54.5)	48 (55.2)	7 (50)	
No craniocaudal distribution	32 (31.7)	25 (28.7)	7 (50)	
Transverse distribution				0.493
Central	1 (1.0)	1 (1.1)	0 (0)	
Peripheral	88 (87.1)	74 (85.1)	14 (100)	
No transverse distribution	4 (4.0)	4 (4.6)	0 (0)	
Lung region distribution				0.172
Unilateral	10 (9.9)	10 (11.5)	0 (0)	
Bilateral	83 (82.2)	69 (79.3)	14 (100)	
Scattered distribution				0.001
Focal	6 (5.9)	6 (6.9)	0 (0)	
Multifocal	55 (54.5)	52 (59.8)	3 (21.4)	
Diffuse	32 (31.7)	21 (24.1)	11 (78.6)	
Extent of lesion	6.39 (0–20)[b]	5.34 (3.84)[a]	12.86 (4.59)[a]	0.000
No. without CT findings	8 (7.9)	8 (9.2)	0 (0)	NA

Wei Zhao et al. AJR; May 2020

CT Findings

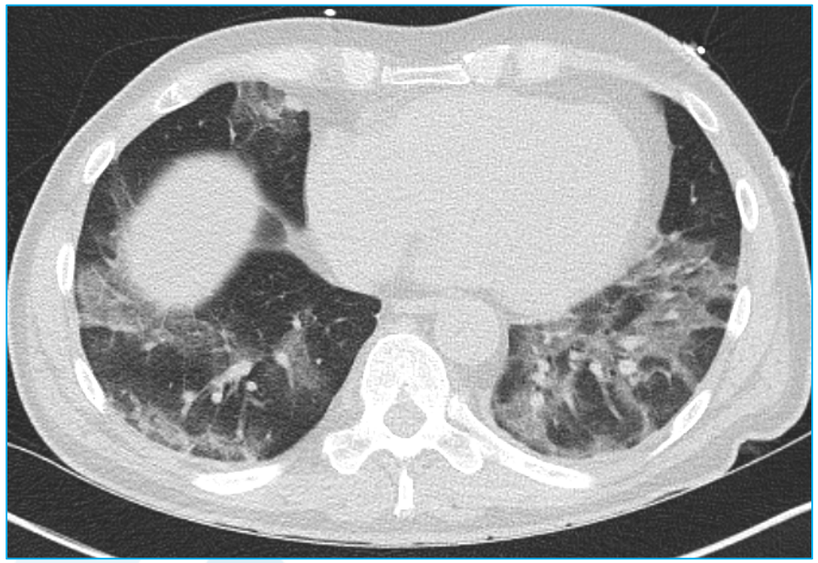

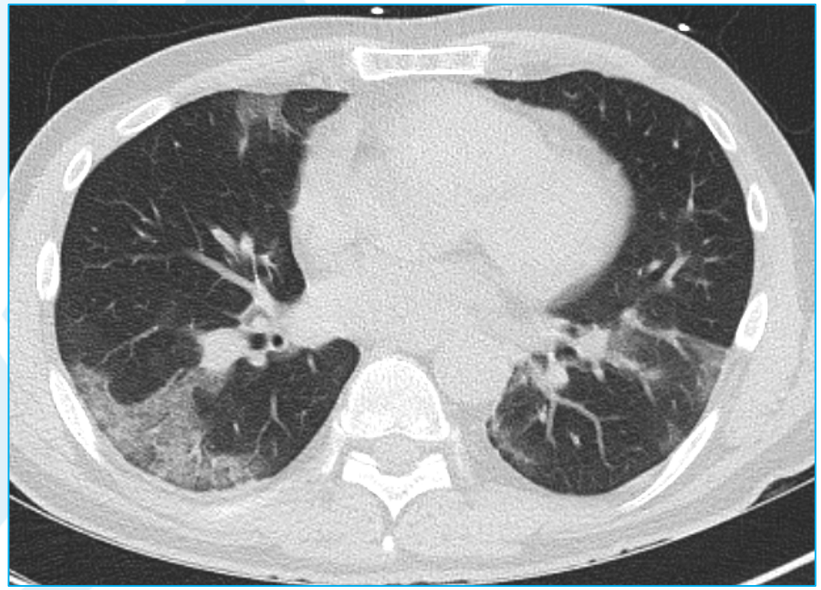

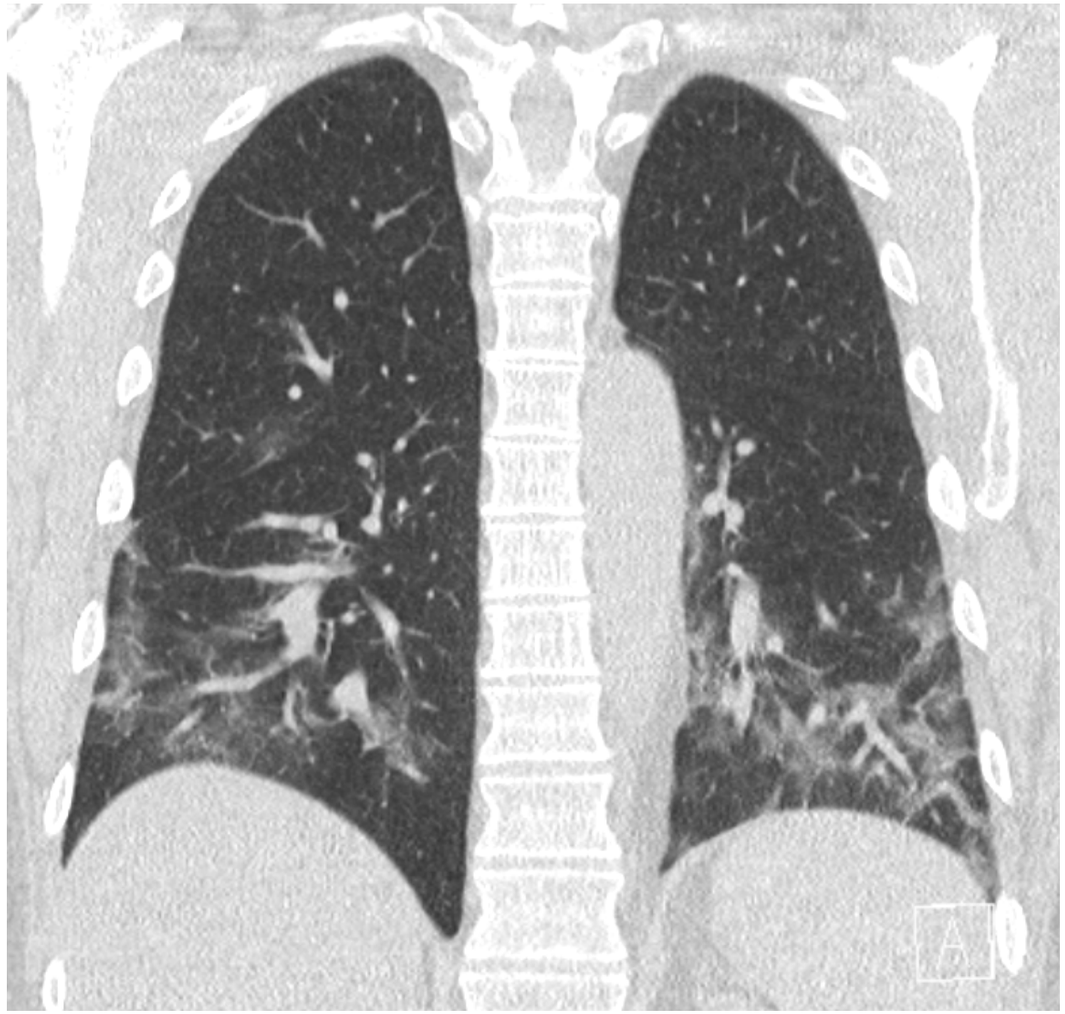

57-year-old man: cough and fever

CT Findings

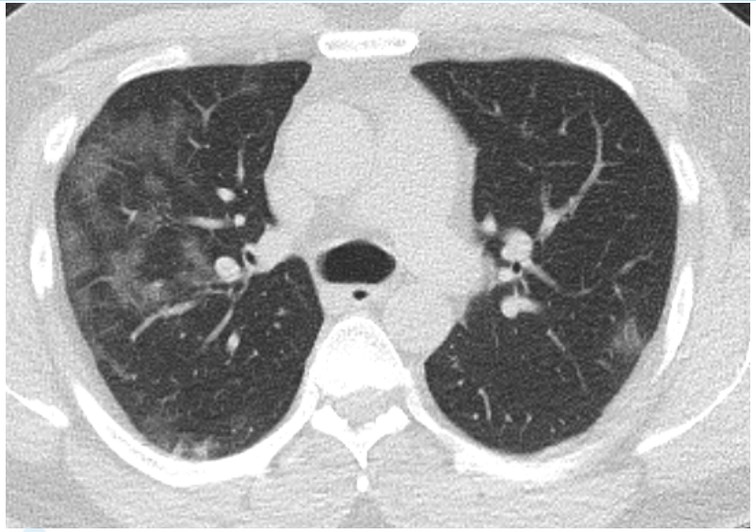

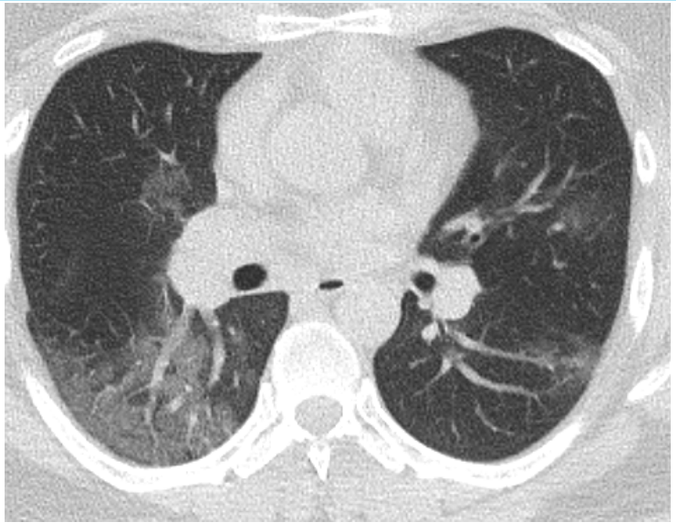

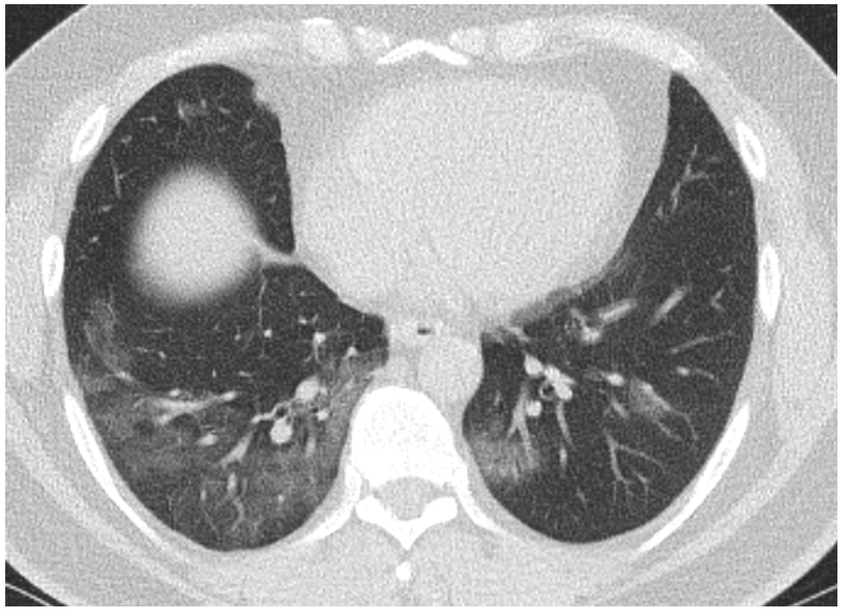

42-year-old man: fever, dyspnoe and diarrhea

CT Findings

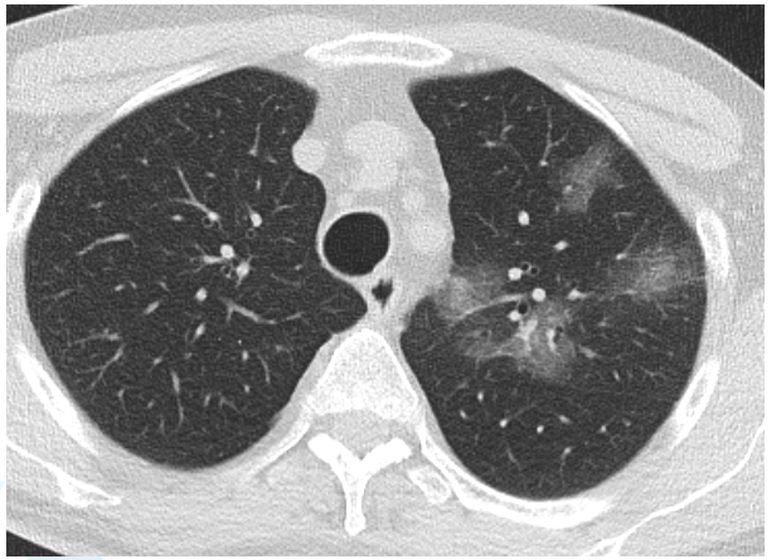

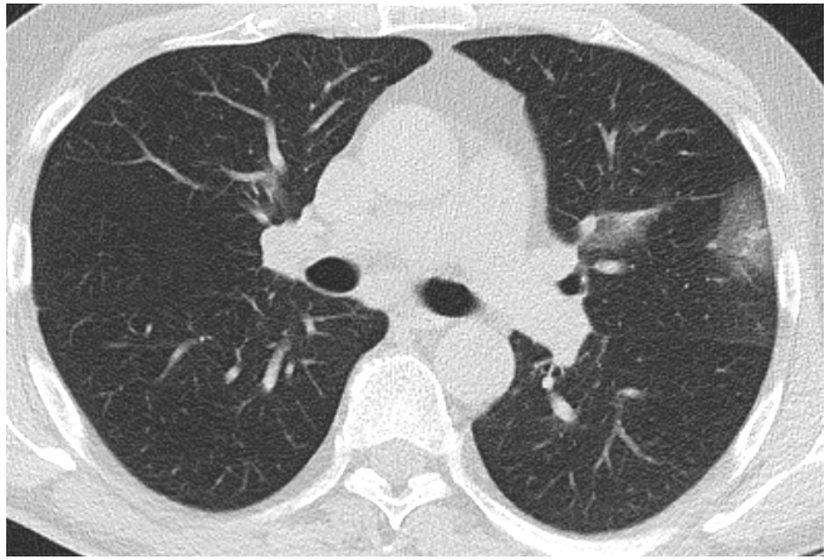

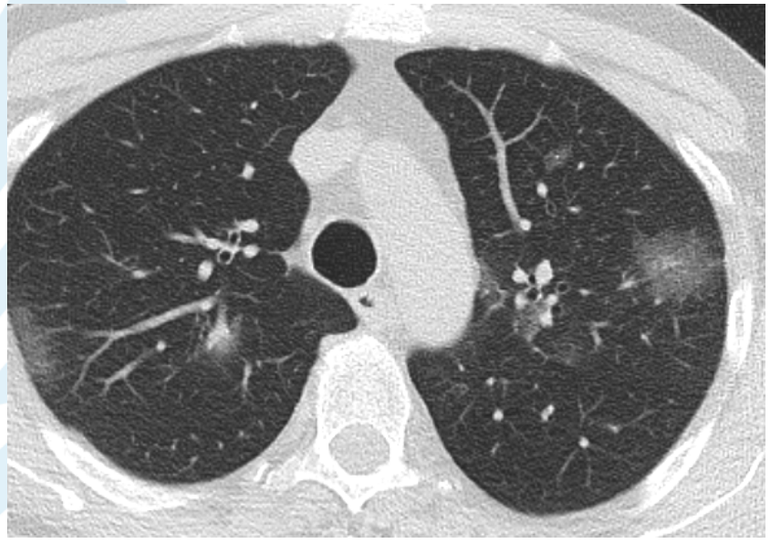

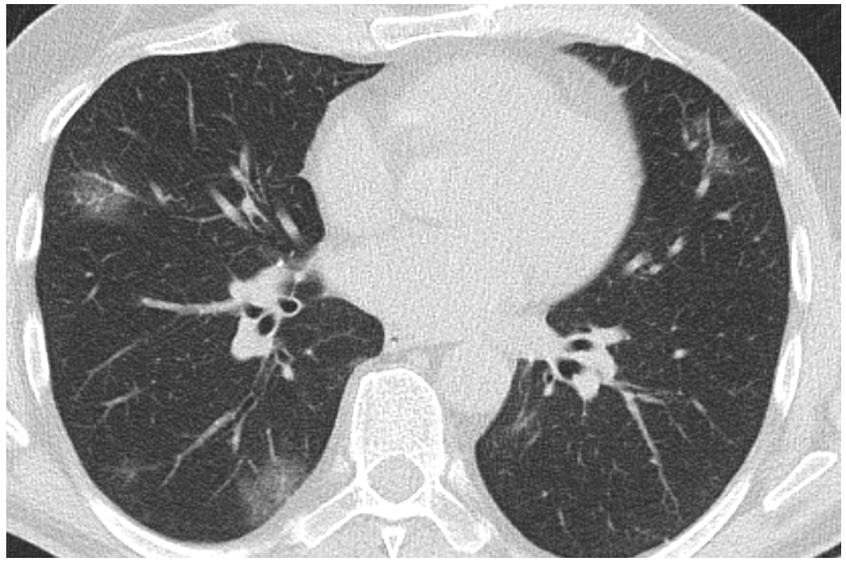

62-year-old man: cough and fever

CT Findings

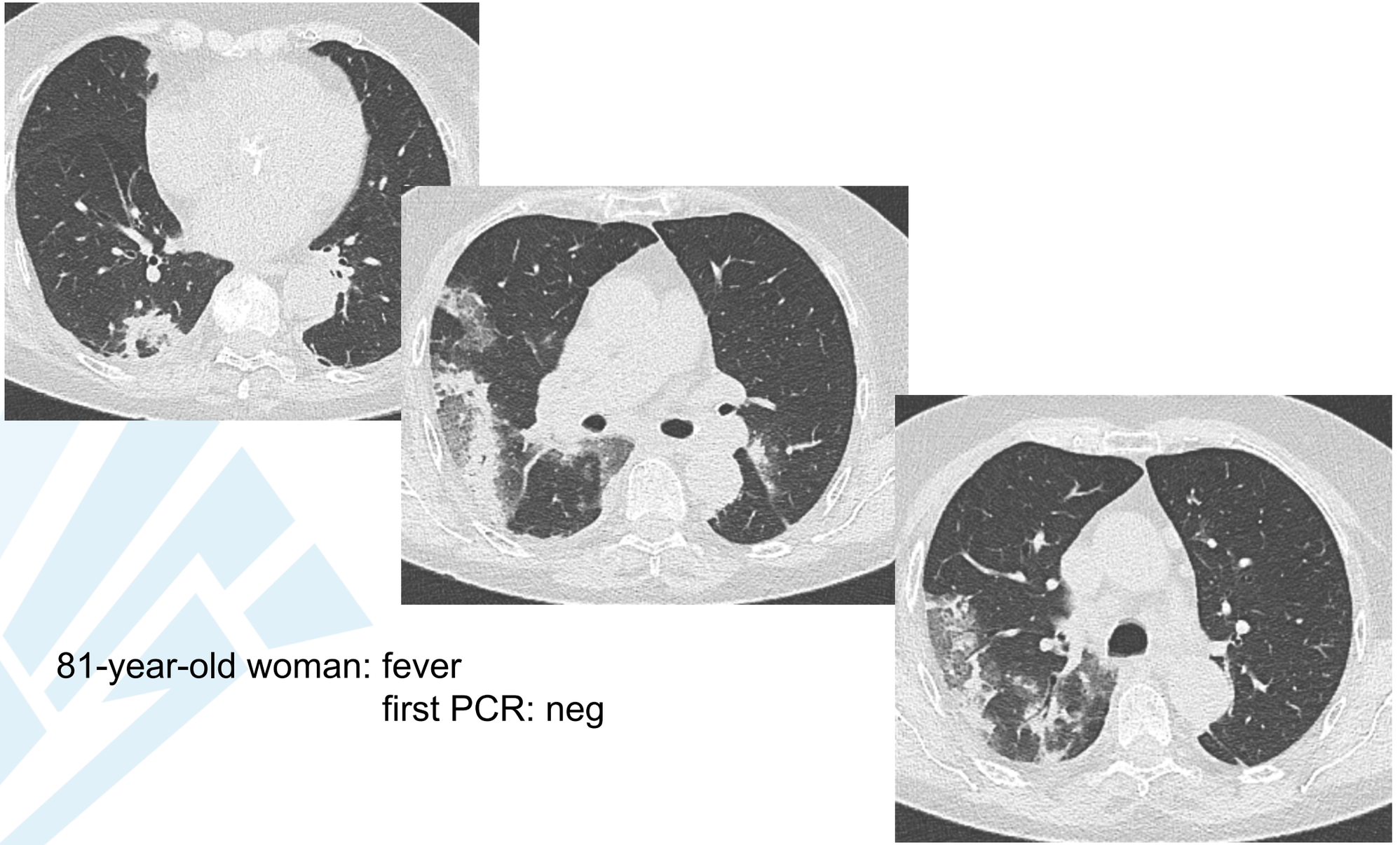

81-year-old woman: fever
first PCR: neg

CT reporting

Radiology Assistant

Siilo. WhatsApp for doctors
DOWNLOAD NOW & COLLABORATE SECURELY WITH YOUR TEAM
siilo.
PRACTICE MEDICINE TOGETHER

COVID-19 CORADS classification

COVID working group of the Dutch Radiological Society

CO-RADS*

Level of suspicion COVID-19 infection

		CT findings
CO-RADS 1	No	normal or non-infectious abnormalities
CO-RADS 2	Low	abnormalities consistent with infections other than COVID-19
CO-RADS 3	Indeterminate	unclear whether COVID-19 is present
CO-RADS 4	High	abnormalities suspicious for COVID-19
CO-RADS 5	Very high	typical COVID-19
CO-RADS 6	PCR +	

Radiology Reports Template for COVID-19 Imaging by COVID-19 Iran Radiologist Consultant Group (COVID-19 IRCG):

Findings that are highly suggestive for COVID-19 infection:

- Ground glass/consolidation opacities
- Bilateral/multilobar involvement
- Peripheral distribution
- Round opacities
- Linear opacities (late)
- Crazy-paving (late)
- Reversed halo (late)

Findings that are inconsistent with COVID-19 infection:

- Tree-in-bud opacities
- Centrilobular distribution
- Peribronchovascular distribution
- Predominantly nodular opacities
- Cavitation
- Lymphadenopathy
- Pleural effusion

Based on mentioned criteria, COVID-19 IRCG recommends reporting of chest imaging studies as either "highly suggestive" or "inconsistent":

- Highly suggestive: presence of any of highly suggestive findings without presence of inconsistent findings
- Inconsistent: presence of inconsistent findings
- Indeterminate: presence of multiple highly suggestive findings with one of inconsistent findings. These cases need consultation with COVID-19 IRCG.

Highly suggestive reports imply: Findings are highly suggestive for viral pneumonia including COVID-19. Isolation and COVID-19 essay is recommended.

Inconsistent reports imply: Findings are inconsistent with COVID-19 infection. However, in case of high clinical suspicion for COVID-19, follow up imaging is recommended.

CT reporting

Conclusion:

- *Positive: Very suggestive findings for COVID-19 pulmonary infection*

  (presence of very suggestive findings without presence of inconsistent findings)

- *Negative: Inconsistent with COVID-19 pulmonary infection*

  (no abnormalities or presence of inconsistent findings / other abnormalities)

- *Indeterminate*

  (presence of suggestive findings with presence of inconsitent findings)

Positive


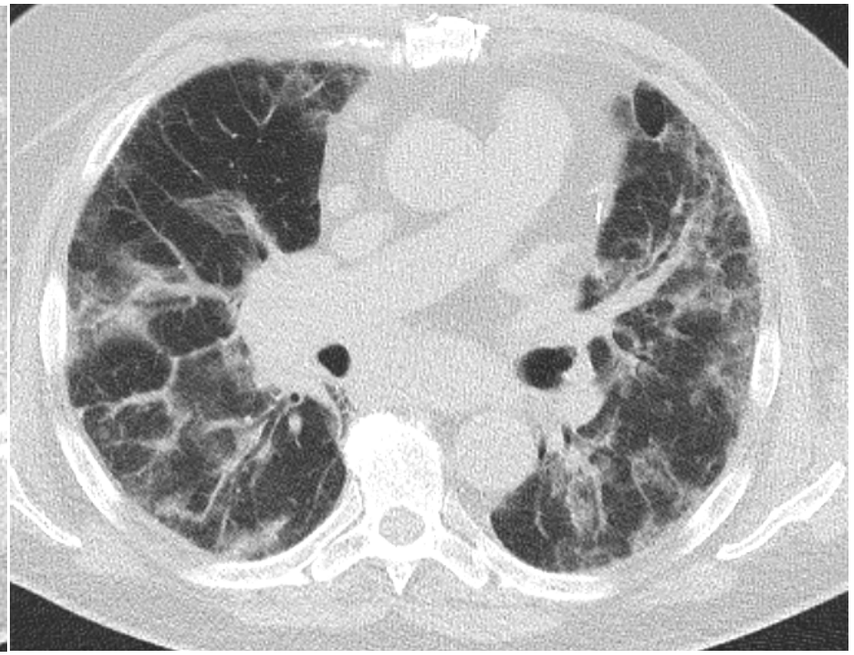
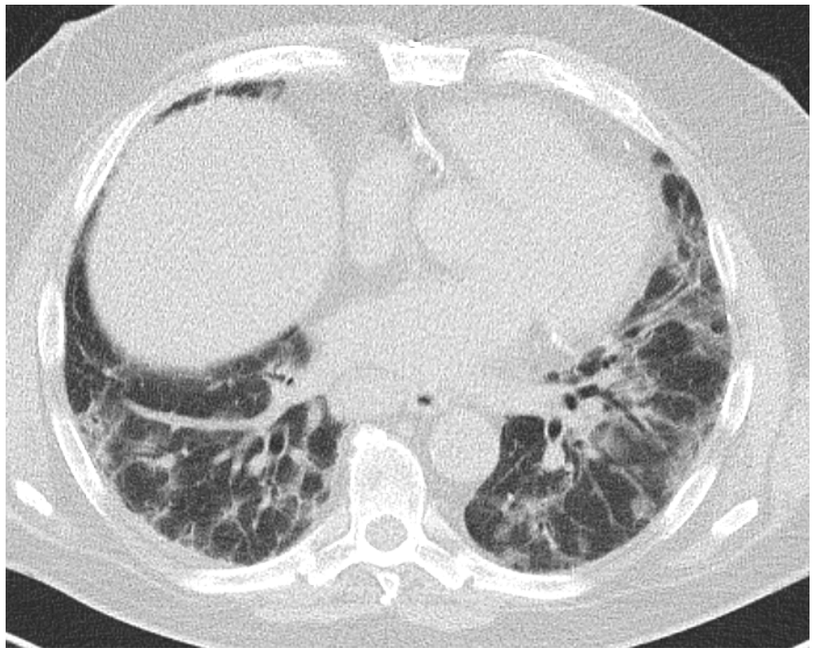

67-year-old man: dyspnea, cough, no fever
PCR positive
(† 7 days after this CT)

Positive

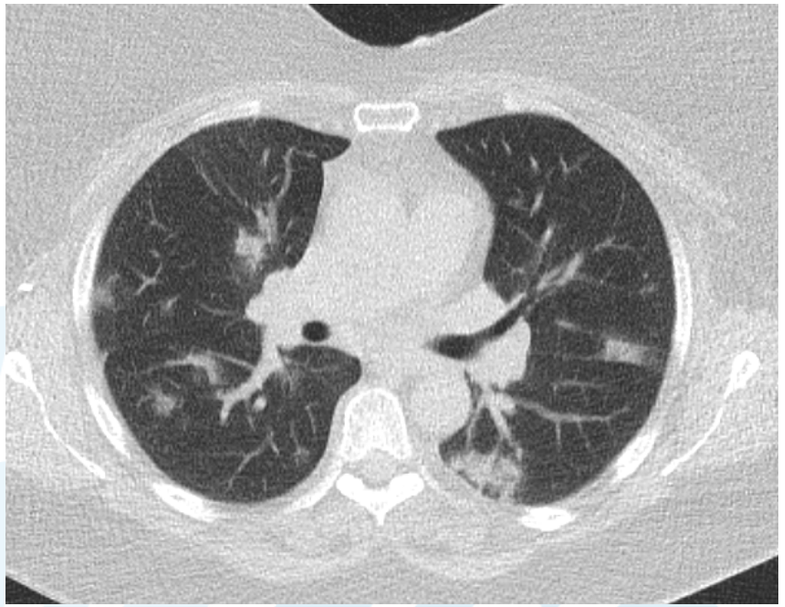
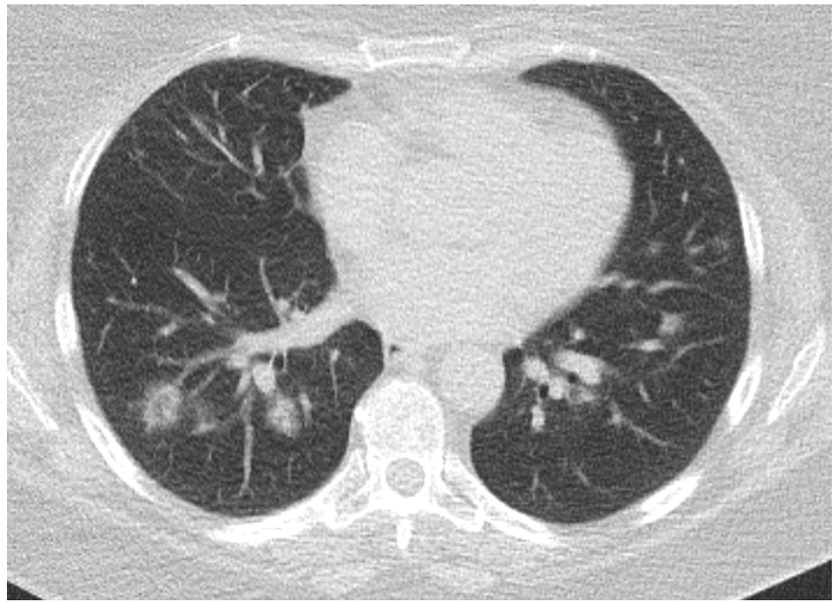
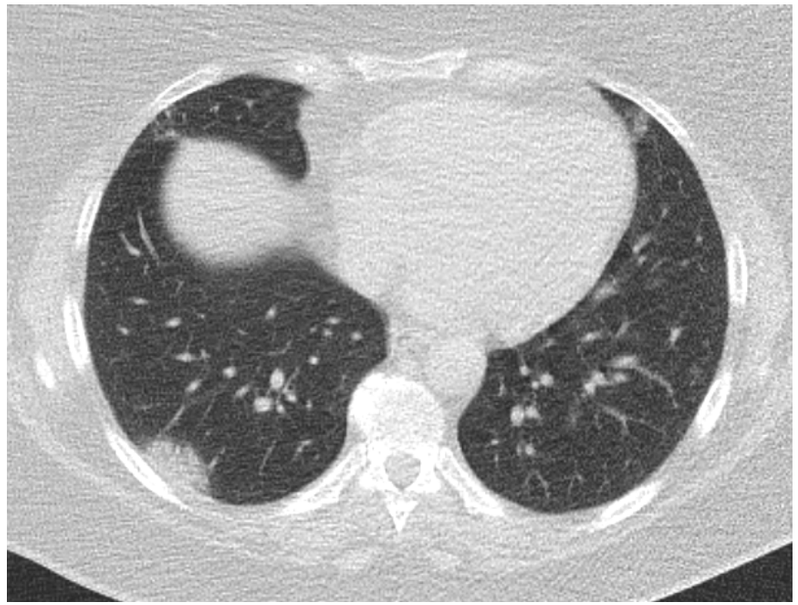

47-year-old woman: PCR positive

Negative

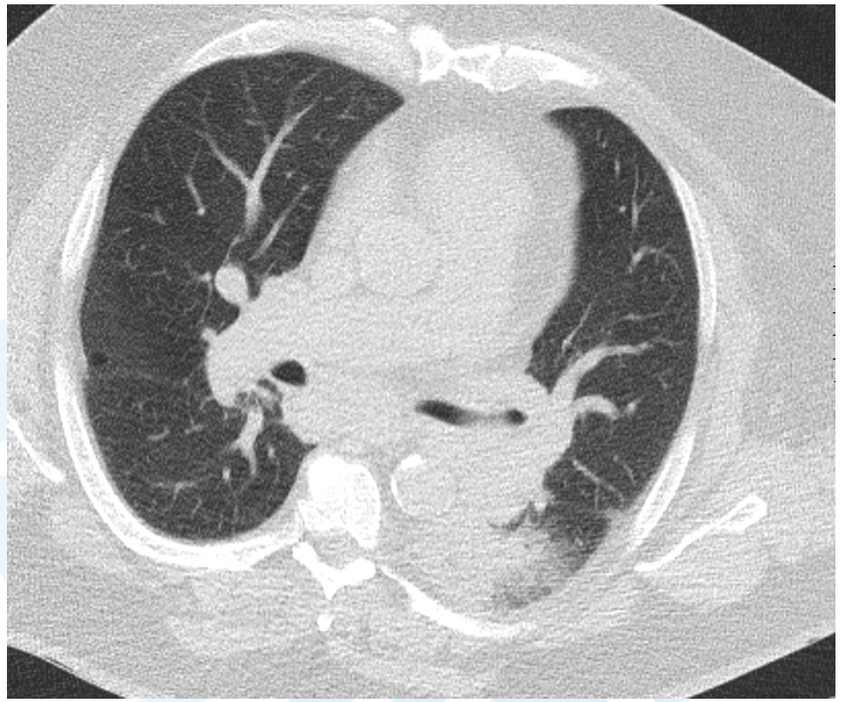

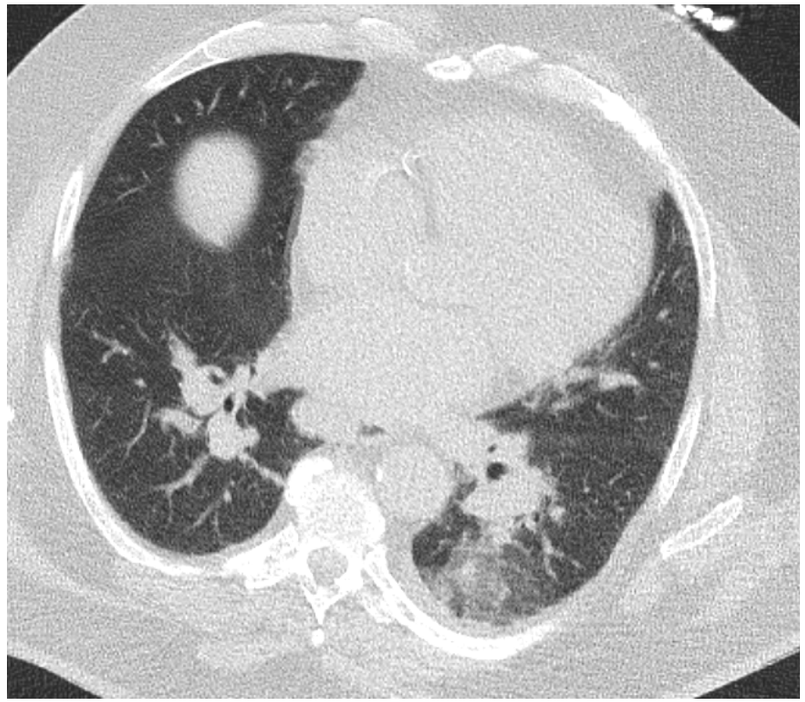

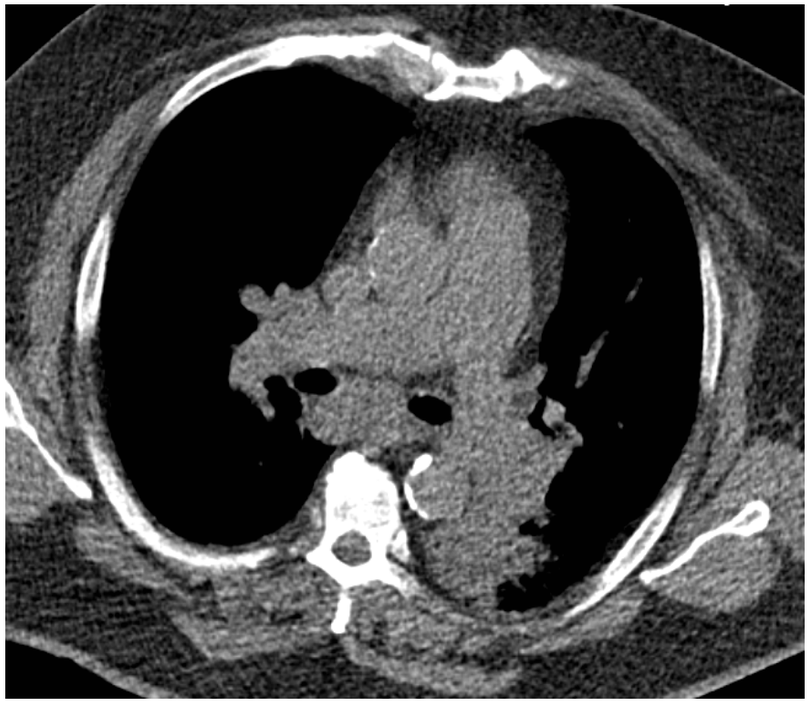

68-year-old man: dyspnea

Indeterminate

80-year-old woman: fever, dyspnea
PCR: two times negative
(23/3/2020)

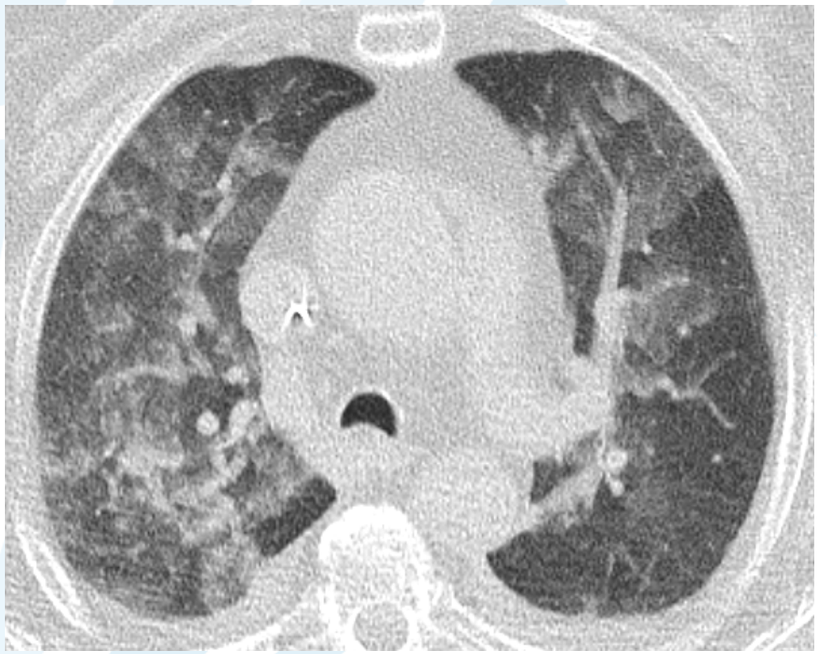



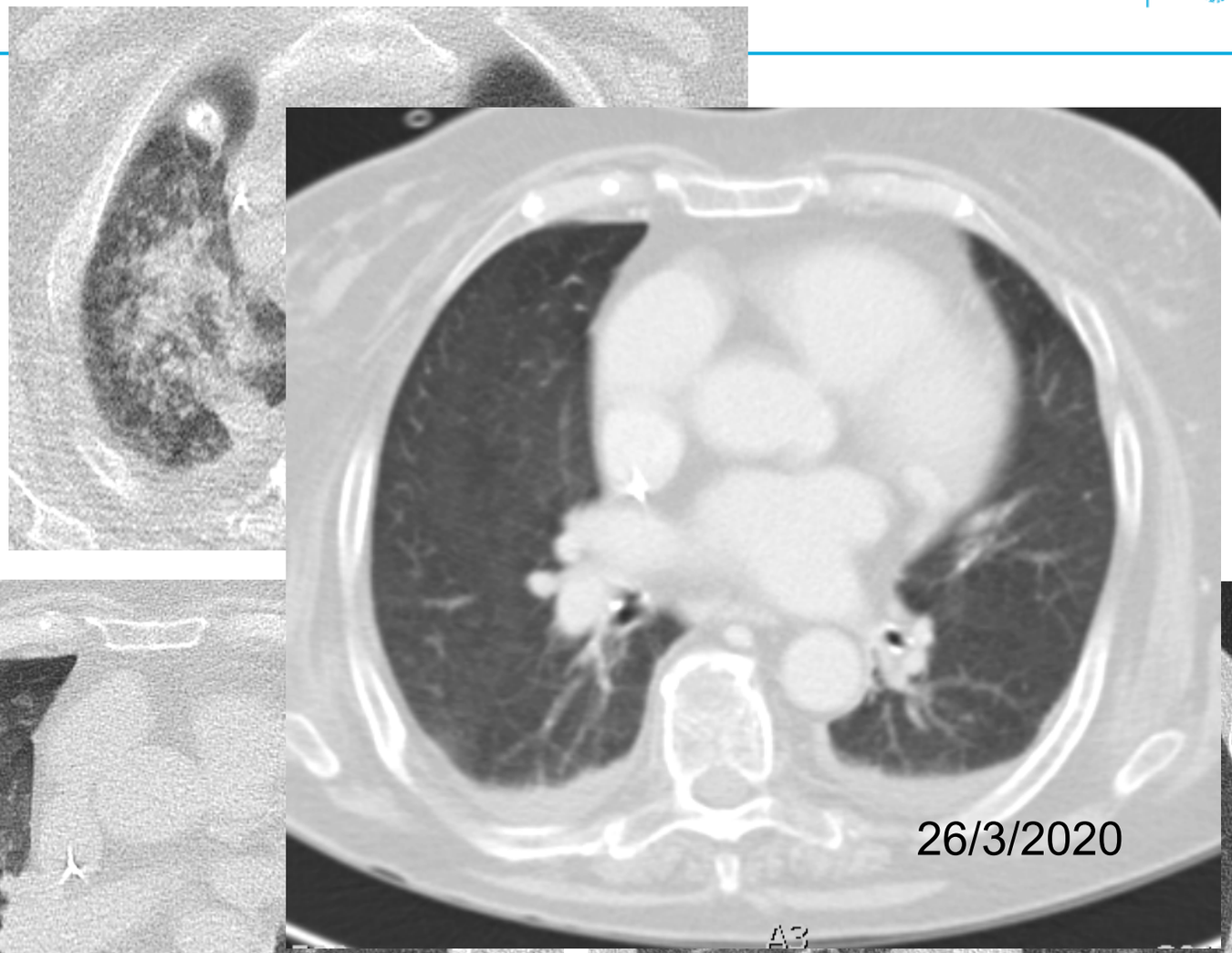

CT severity score

Optioneel*

- CT score ter evaluatie van de uitgebreidheid van het aangetaste longparenchym, met evaluatie per kwab. % aangetast. 5 punten per kwab, 25 in totaal.

  0%: 0 punten
  < 5%: 1 punt
  5-25%: 2 punten
  25-50%: 3 punten
  50-75%: 4 punten
  >75%: 5 punten

- Globale inschatting uitgebreidheid parenchymafwijkingen ten opzichte van het totale longvolume: <5% / 5-25% / 25-<50% / 50-<75% / >75%

*deze scores kunnen de clinicus een idee geven van de uitgebreidheid van het aangetaste longparenchym, maar zijn niet gevalideerd

CT: evolution and follow-up

Radiology

Temporal Changes of CT Findings in 90 Patients with COVID-19 Pneumonia: A Longitudinal Study

Yuhui Wang, PhD[1,2,*], Chengjun Dong, MD[1,2,*], Yue Hu, PhD[3], Chungao Li, MD[1,2], Qianqian Ren, MD[1,2], Xin Zhang, MD[1,2], Heshui Shi, PhD[1,2], Min Zhou, PhD[1,2]

CT: evolution and follow-up

Key Results

The extent of CT abnormalities progressed rapidly after symptom onset, peaked during illness days 6-11, and followed by persistence of high levels.

The predominant pattern of abnormalities after symptom onset was ground-glass opacity; the percentage of mixed pattern peaked during illness days 12-17, and became the second most prevalent pattern thereafter.

Sixty-six of the 70 patients (94%) discharged had residual disease on final CT scans, with ground-glass opacity the most common pattern.

Yuhui Wang et al. Radiology 2020; in press

CT: evolution and follow-up

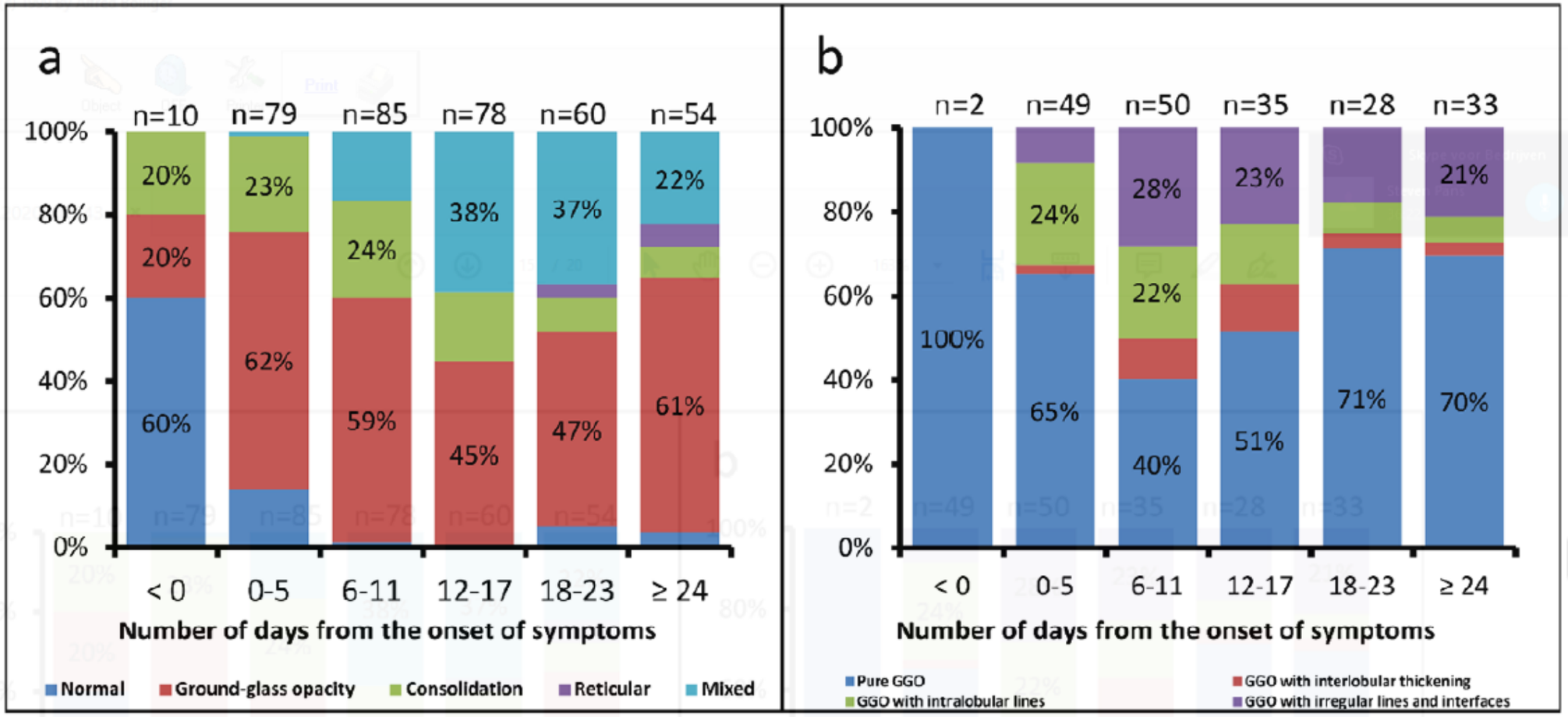

Yuhui Wang et al. Radiology 2020; in press

CT: evolution and follow-up

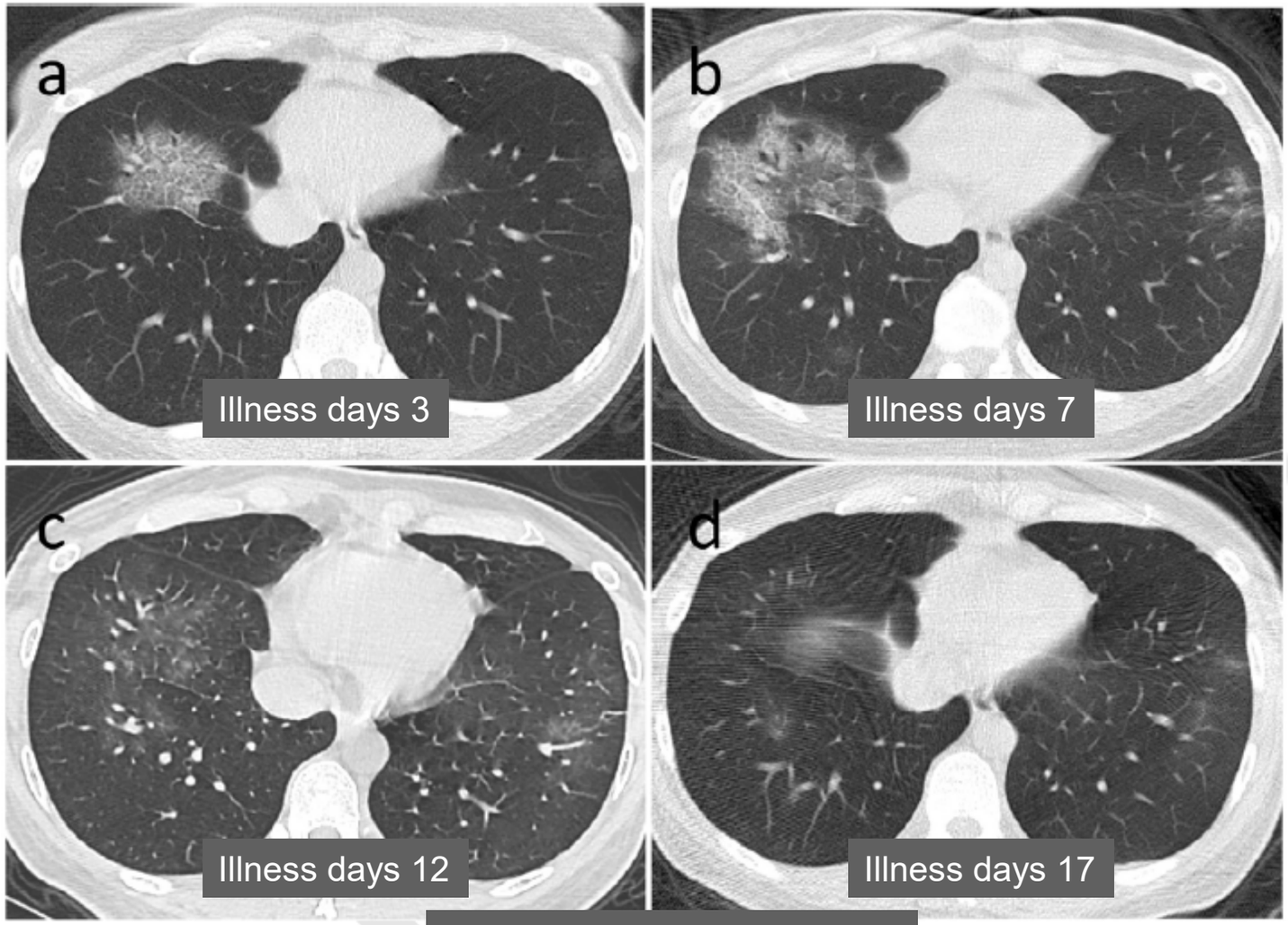

Discharged at illness days 20

Yuhui Wang et al. Radiology 2020; in press

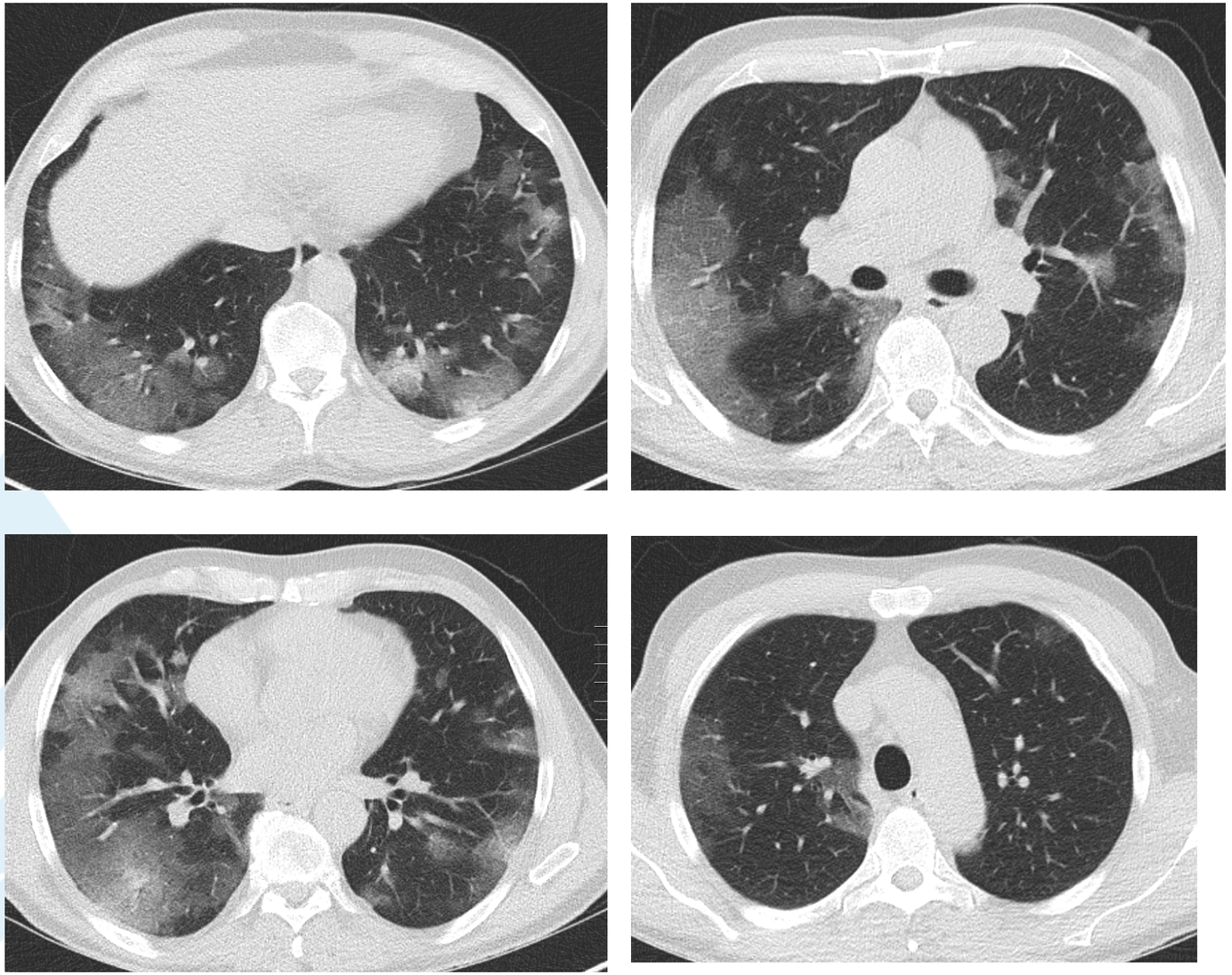

63-year-old man: cough, dyspnea and fever (22/3/2020)

PCR negative, IgM and IgG positive on 30/3/2020

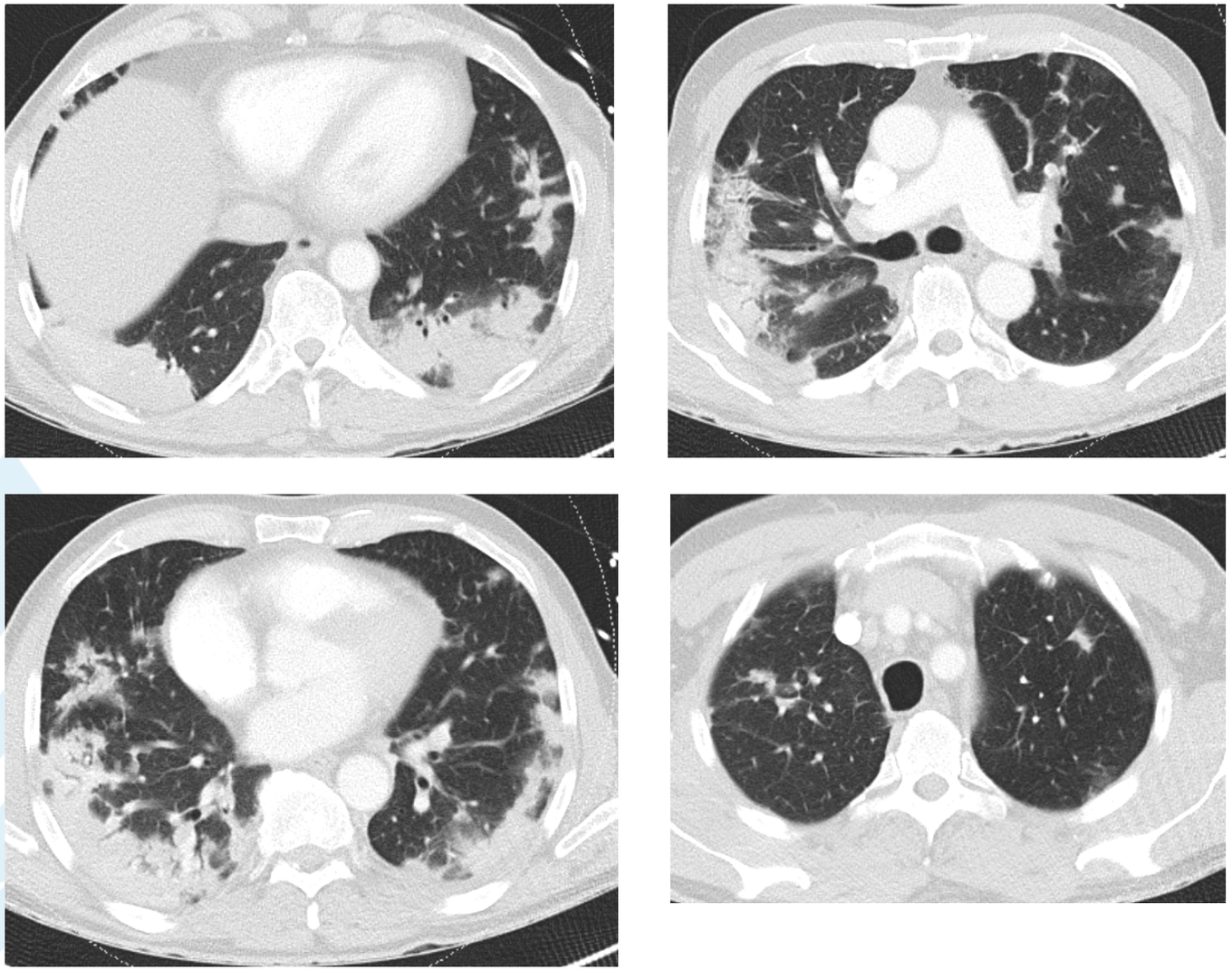

63-year-old man: DVT, increasing dyspnea (3/4/2020)

CT: evolution and follow-up

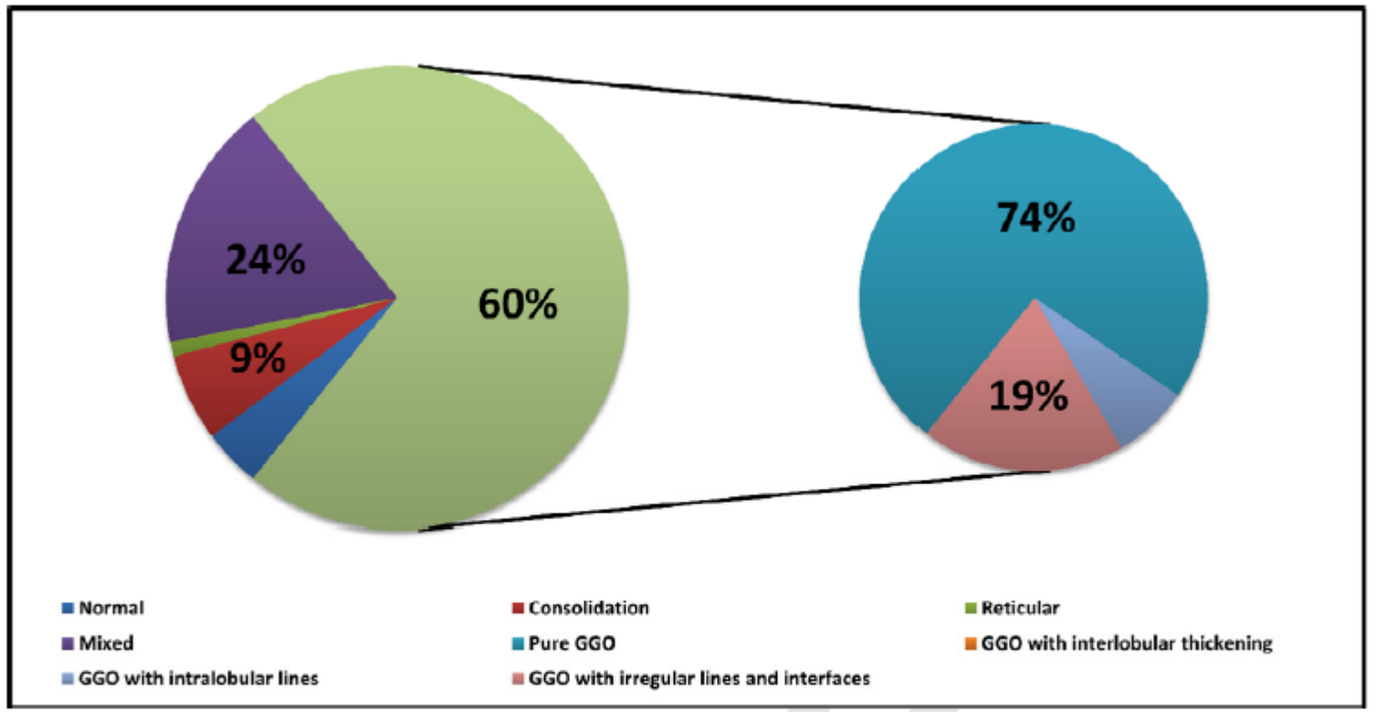

Figure 6. The distribution of CT patterns of the final CT scans at the time of hospital discharge in 70 patients. GGO = ground-glass opacity.

Yuhui Wang et al. Radiology 2020; in press

Results UZ Leuven

De onderzoekscode is in gebruik genomen op 20/3/2020.
In bijlage de resultaten van 20/3 t.e.m. 7/4.

Rijlabels	Aantal van interneAanvraagServKey
RAD ct thorax 54	687
Eindtotaal	**687**

- *Resultaten 200 CT:*
  - *Suggestief: 67 patiënten 33,5%*
  - *Inconsistent: 96 patiënten 48%*
  - *Onbepaald: 37 patiënten 18,5%*
- *187/200 patiënten (93,5%) werd PCR gedaan, hierbij:*
  - *Positief: 58 patiënten 31,1%*
  - *Negatief: 128 patiënten 68,4%*

Jeroen Desmet, work in progress

Concordantie CT – PCR:

- *Bij de suggestieve patiënten (67 patiënten, waarvan bij 63 patiënten PCR test gedaan):*
  - *§ 45 positieve PCR wissers: 71,4% concordantie*
    (bij een positieve CT, is 71,4% de PCR wisser ook positief)
  - *§ 18 negatieve PCR wissers: 28,6% disconcordantie*
    (bij een positieve CT, is bij 28,6% de PCR wisser negatief)
- *Bij de inconsistente patiënten (96 patiënten): hier bij 86 patiënten PCR-test gedaan:*
  - *§ 3 positieve PCR wissers: 3,5 % disconcordantie*
    (bij een negatieve CT, is bij 3,5 % een positieve PCR-wisser)
  - *§ 83 negatieve PCR wissers: 96,5 % concordantie*
    (bij een negatieve CT, is bij 96,5% een negatieve PCR-wisser)
- *Bij de **onbepaalde** patiënten (37 patiënten)*
  - *§ 10 positief op PCR (27%)*
  - *§ 27 negatief op PCR (73%)*

Conclusion

- Low-dose CT-scan not as a first-line examination technique
- Low-dose CT-scan as triage examination technique together with the clinical evaluation for choice between COVID and non-COVID area
- Low-dose CT scans give earlier and faster results with possibly higher sensitivity than RT-PCR, but low specificity

UZ LEUVEN

Thank you for your attention

W De Wever

April 9, 2020

University Hospitals - Dept of Radiology
Leuven, Belgium
www.chestradiology.info

PENTALFA

MULTIDISCIPLINAIR INTERACTIEF
POSTGRADUAAT AFSTANDSONDERWIJS

Is there a role for bronchoscopy during the COVID-19 pandemic ?

Christophe Dooms - Jonas Yserbyt
Department of Respiratory Diseases
University Hospitals KU Leuven

Detection of SARS-CoV-S in bronchoscopic specimens.

Limited data on BALF specimens reported.
High positive RT-PCR rates in BALF specimens.

Table 2. Detection of 2019-nCoV in respiratory sites of NCP cases.

Collection date	Sample types	NCP cases	
		Severe	Mild
0~7 d.a.o			
Positive rate (n/N, %)	Throat	12/20 (60.0)	46/75 (61.3)
	Nasal	11/15 (73.3)	147/204 (72.1)
	Sputum	8/9 (88.9)	37/45 (82.2)
	BALF	0/0 (0)	0/0 (0)
8~14 d.a.o			
Positive rate (n/N, %)	Throat	18/36 (50.0)	
	Nasal	34/47 (72.3)	
	Sputum	15/18 (83.3)	
	BALF	12/12 (100)	
≥15 d.a.o			
Positive rate (n/N, %)	Throat	14/38 (36.8)	
	Nasal	17/34 (50.0)	
	Sputum	11/18 (61.1)	
	BALF	11/14 (78.6)	

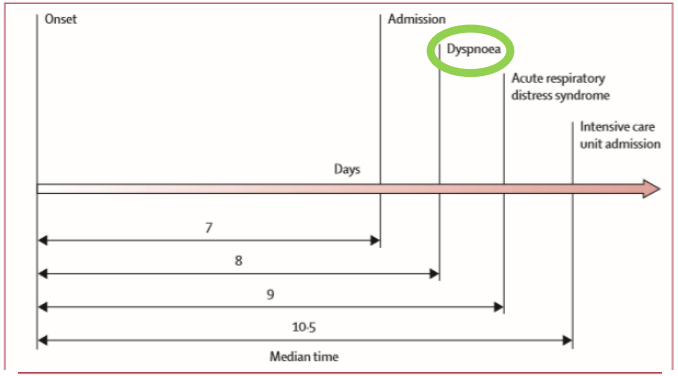

Timeline of 2019-nCoV cases after onset of illness

Table. Detection Results of Clinical Specimens by Real-Time Reverse Transcriptase–Polymerase Chain Reaction

Specimens and values	Bronchoalveolar lavage fluid (n = 15)	Fibrobronchoscope brush biopsy (n = 13)	Sputum (n = 104)	Nasal swabs (n = 8)	Pharyngeal swabs (n = 398)
Positive test result, No. (%)	14 (93)	6 (46)	75 (72)	5 (63)	126 (32)
Cycle threshold, mean (SD)	31.1 (3.0)	33.8 (3.9)	31.1 (5.2)	24.3 (8.6)	32.1 (4.2)
Range	26.4-36.2	26.9-36.8	18.4-38.8	16.9-38.4	20.8-38.6
95% CI	28.9-33.2	29.8-37.9	29.3-33.0	13.7-35.0	31.2-33.1

Yang Yang, *et al.* medRxiv 2020 (not peer-reviewed). Huang C, *et al.* Lancet 2020. Wang W, *et al.* JAMA 2020.

American Association for Bronchology and Interventional Pulmonology (AABIP) Statement on the Use of Bronchoscopy and Respiratory Specimen Collection in Patients with Suspected or Confirmed COVID-19 Infection

Momen M. Wahidi;* Carla Lamb, MD,* MD, MBA; Septimiu Murgu, MD; Ali Musani, MD; 12-03-2020 + update 19-03-2020.

Indications for Bronchoscopy in patients with suspected or confirmed COVID-19 infections

- Bronchoscopy is **relatively contra-indicated** in patients with suspected and confirmed COVID-19 infections.
  = bronchoscopy should *not* be done to rule in COVID-19 (risk of transmission ; risk of deterioration).
- The only role for bronchoscopy would be when
  # less invasive testing to confirm COVID-19 are inconclusive
  # an alternative diagnosis that would impact clinical management is suspected (e.g. patient with immunosuppression with concerns for other viral pneumonia, Pneumocystis pneumonia or fungal pneumonia)
  # an urgent life-saving intervention is deemed necessary.
- Bronchoscopy for *any non-urgent reason should be postponed* until after full recovery and the patient is declared free of infection.

https://aabronchology.org/wp-content/uploads/2020/03/AABIP-Statement-on-Bronchoscopy-COVID_3-12-2020-Statement-plus-3-19-2020-updates-V3.pdf

Ai *et al.* Wuhan (n=1014)

06-01 → 06-02-2020

chest CT scan and upper aw RT-PCR

- bias ++ (any time; fever±dry cough)
- retrospective CT reading for covid-19
- CT = positive or negative

≠

J. Desmet UZ Leuven (n=190)

20-03 → 25-03-2020

chest CT scan and nasofar RT-PCR

- bias + (ER; fever±respiratory symptoms)
- prospective CT reading (~ covid-19)
- CT = very suggestive/inconsistent/indeterminate

? SARS-CoV-S prevalence ?

80-85%		40-45%
59%	SARS-CoV-2 confirmed by RT-PCR	33%
88%	CT findings very suggestive for Covid-19 pneumonia	34%
		PCR+ 25% PCR- 9%
17%	CT findings inconsistent for Covid-19 and PCR positive	3%
10%	CT findings inconsistent for Covid-19 and PCR negative	46%
NA	CT findings indeterminate Covid-19 and PCR negative	11%
NA	CT findings indeterminate Covid-19 and PCR positive	7%

Indication for bronchoscopy ?

case-by-case discussion

Bronchoscopy with BAL at UZ Leuven (n=28)

21-03-2020 → 04-04-2020 (15 days)

Nasopharyngeal swab RT-PCR negative for SARS-CoV-2

COVID-19 MAYBE unit : case-by-case discussion with treating physician and/or physician involved in underlying medical history (e.g. haematologist, pulmonologist, …) in case of CT “suggestive” or “indeterminate”.

Who ? “stable” (HR ≤ 120/min ; RR ≤ 20/min ; SpO2 ≥ 93% with NC <5L O2/min)

How ? Small aliquots 10-20 mL of saline to obtain 2-3 mL of lavage fluid.
Secured endoscopy room (airborne precautions) + full Personal Protective Equipment.

18% (5 patients) SARS-CoV-2 confirmed by RT-PCR on BALF

- only SARS-CoV-S positive (3 patients)
- SARS-CoV-S positive & bacterial co-infection (2 patients)

82% (23 patients) negative for SARS-CoV-S by RT-PCR on BALF :

- other germ confirmed (19 patients ; 68%) … mainly immunocompromised patients
- full respiratory panel negative (4 patients ; 14%)

PJP ; CMV ; hMPV ; parainfluenza ; corona NL63 ; corona HKU ; rhino/enterovirus ; mycoplasma ; pseudomonas ; morganella

Respiratoir panel

Influenza A virus	negatief
Influenza B virus	negatief
Respiratoir syncytieel virus (RSV)	negatief
Humaan metapneumovirus (hMPV)	negatief
Parainfluenza virus 1	negatief
Parainfluenza virus 2	negatief
Parainfluenza virus 3	negatief
Parainfluenza virus 4	negatief
Adenovius	negatief
Entero-/Rhinovirus	negatief
Cytomegalovirus	negatief
Parechovirus	negatief
Coronavirus NL63	negatief
Coronavirus 229E	negatief
Coronavirus OC43	negatief
Coronavirus SARS / COVID-19 *Nieuwe test vanaf 25/01/2020*	sterk positief
Coronavirus HKU-1	negatief
Coronavirus MERS	negatief
Herpes simplex virus 1	negatief
Herpes simplex virus 2	negatief
Enterovirus D68	negatief
Mycoplasma pneumoniae	negatief
Coxiella burnetii	negatief
Pneumocystis jirovecii	negatief
Chlamydia pneumoniae	negatief
Chlamydia psittaci	negatief
Bocavirus	negatief
Streptococcus pneumoniae	negatief
Legionella pneumophila	negatief

Female 67 years old.

2004 Lupus R/ hydroxychloroquine ; 2020 RA.
Since 1 week URT symptoms, since 3 days fever.
NF swab negative.

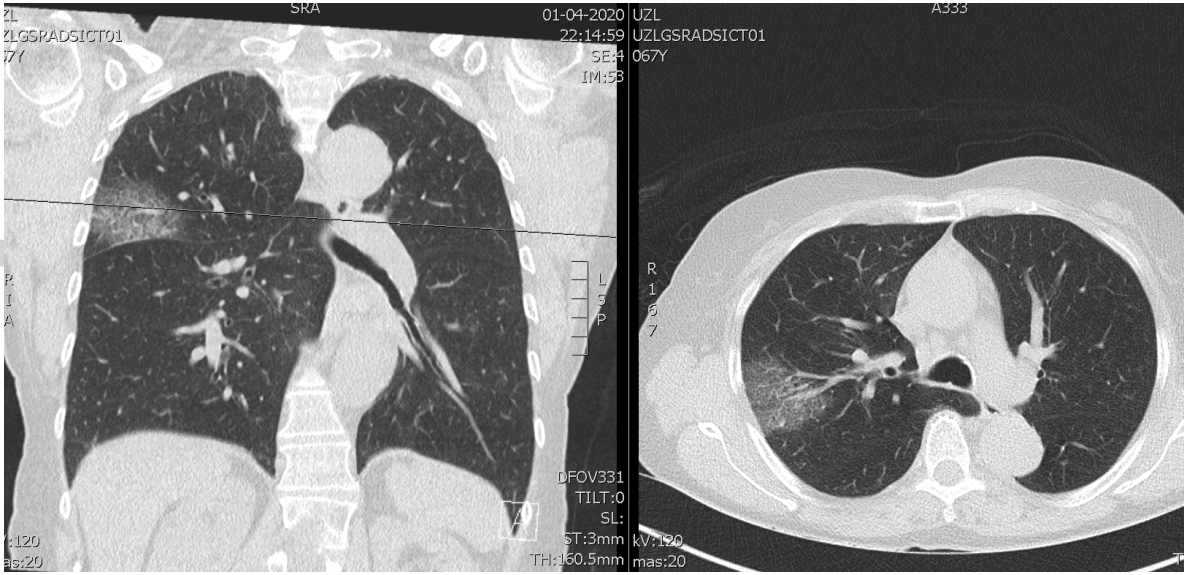

Indeterminate: suggestive + inconsistent findings

Respiratoir panel	
Influenza A virus	negatief
Influenza B virus	negatief
Respiratoir syncytieel virus (RSV)	negatief
Humaan metapneumovirus (hMPV)	negatief
Parainfluenza virus 1	negatief
Parainfluenza virus 2	negatief
Parainfluenza virus 3	negatief
Parainfluenza virus 4	negatief
Adenovius	negatief
Entero-/Rhinovirus	negatief
Cytomegalovirus	negatief
Parechovirus	negatief
Coronavirus NL63	negatief
Coronavirus 229E	negatief
Coronavirus OC43	negatief
Coronavirus SARS / COVID-19	negatief
Nieuwe test vanaf 25/01/2020	
Coronavirus HKU-1	negatief
Coronavirus MERS	negatief
Herpes simplex virus 1	positief
De voorspellende waarde van een positieve HSV PCR voor een	
Herpes simplex virus 2	negatief
Enterovirus D68	negatief
Mycoplasma pneumoniae	negatief
Coxiella burnetii	negatief
Pneumocystis jirovecii	negatief
Chlamydia pneumoniae	negatief
Chlamydia psittaci	negatief
Bocavirus	negatief
Streptococcus pneumoniae	positief
Legionella pneumophila	negatief

Male 75 years old.

Since 3 days dry cough, fever 38°C, now dyspnea.
NF swab SARS-CoV-S PCR negative.



Indeterminate: suggestive + inconsistent findings

Male 67 years old

04-2019 JAK2 myelofibrosis > allo Tx.
Since months cough.
Now : ER < increased dyspnea and dry cough.

Respiratoir panel

Influenza A virus	negatief
Influenza B virus	negatief
Respiratoir syncytieel virus (RSV)	negatief
Humaan metapneumovirus (hMPV)	negatief
Parainfluenza virus 1	negatief
Parainfluenza virus 2	negatief
Parainfluenza virus 3	negatief
Parainfluenza virus 4	negatief
Adenovius	negatief
Entero-/Rhinovirus	negatief
Cytomegalovirus	negatief
Parechovirus	negatief
Coronavirus NL63	negatief
Coronavirus 229E	negatief
Coronavirus OC43	negatief
Coronavirus SARS / COVID-19	negatief
Nieuwe test vanaf 25/01/2020	
Coronavirus HKU-1	sterk positief
Coronavirus MERS	negatief
Herpes simplex virus 1	positief
De voorspellende waarde van een positieve HSV PCR voor een herpes simp	
Herpes simplex virus 2	negatief
Enterovirus D68	negatief
Mycoplasma pneumoniae	negatief
Coxiella burnetii	negatief
Pneumocystis jirovecii	positief, compatibel met Pneumocystis jirovecii pneumonie
Chlamydia pneumoniae	negatief
Chlamydia psittaci	negatief
Bocavirus	negatief
Streptococcus pneumoniae	negatief
Legionella pneumophila	negatief



NF swab SARS-CoV-S PCR negative
Indeterminate: suggestive + inconsistent findings.

Respiratoir panel

Influenza A virus	negatief
Influenza B virus	negatief
Respiratoir syncytieel virus (RSV)	negatief
Humaan metapneumovirus (hMPV)	negatief
Parainfluenza virus 1	negatief
Parainfluenza virus 2	negatief
Parainfluenza virus 3	negatief
Parainfluenza virus 4	negatief
Adenovius	negatief
Entero-/Rhinovirus	positief
Cytomegalovirus	negatief
Parechovirus	negatief
Coronavirus NL63	negatief
Coronavirus 229E	negatief
Coronavirus OC43	negatief
Coronavirus SARS / COVID-19	negatief
Nieuwe test vanaf 25/01/2020	
Coronavirus HKU-1	negatief
Coronavirus MERS	negatief
Herpes simplex virus 1	sterk positief
De voorspellende waarde van een positieve HSV PCR voor een her	
Herpes simplex virus 2	negatief
Enterovirus D68	negatief
Mycoplasma pneumoniae	negatief
Coxiella burnetii	negatief
Pneumocystis jirovecii	negatief
Chlamydia pneumoniae	negatief
Chlamydia psittaci	negatief
Bocavirus	negatief
Streptococcus pneumoniae	negatief
Legionella pneumophila	negatief

Male 67 years old

2017 ssLTX < COPD

Now : 4d weakness, 2d increased dyspnea & 40°C.

NF swab SARS-CoV-S PCR negative.

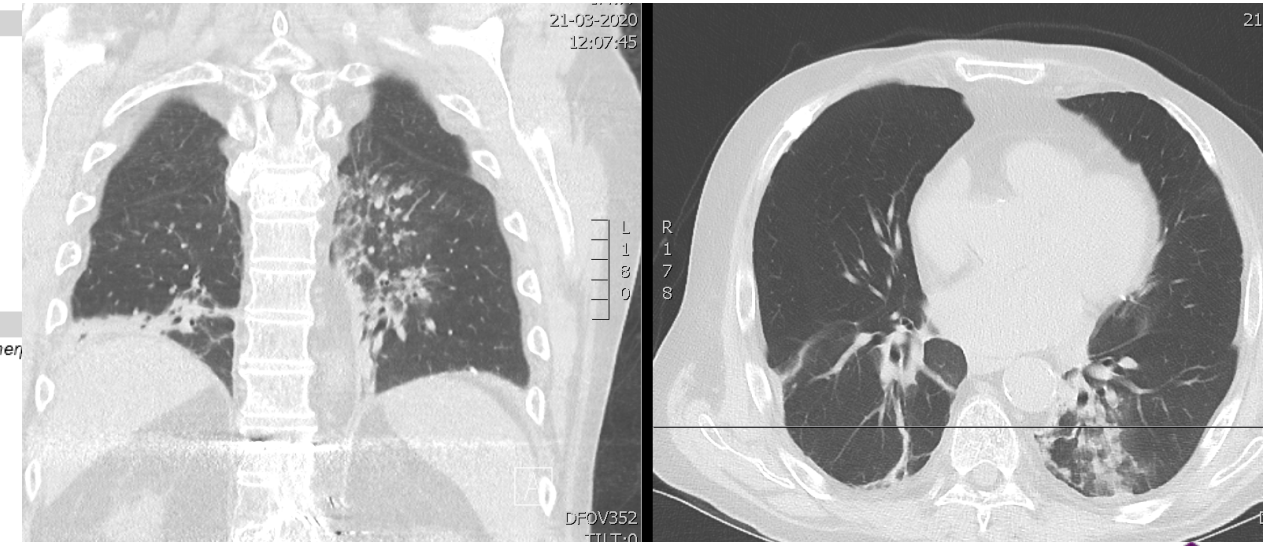

Indeterminate: suggestive + inconsistent findings.

Female 53 years old

2017 Multiple Myeloma; 05-2018 autologous BM Tx

Since 1 week cough, fever, dyspnea

Respiratoir panel

Influenza A virus	negatief
Influenza B virus	negatief
Respiratoir syncytieel virus (RSV)	negatief
Humaan metapneumovirus (hMPV)	negatief
Parainfluenza virus 1	negatief
Parainfluenza virus 2	negatief
Parainfluenza virus 3	negatief
Parainfluenza virus 4	negatief
Adenovius	negatief
Entero-/Rhinovirus	negatief
Cytomegalovirus	positief
Parechovirus	negatief
Coronavirus NL63	negatief
Coronavirus 229E	negatief
Coronavirus OC43	negatief
Coronavirus SARS / COVID-19 *Nieuwe test vanaf 25/01/2020*	negatief
Coronavirus HKU-1	negatief
Coronavirus MERS	negatief
Herpes simplex virus 1	negatief
Herpes simplex virus 2	negatief
Enterovirus D68	negatief
Mycoplasma pneumoniae	negatief
Coxiella burnetii	negatief
Pneumocystis jirovecii	positief, compatibel met Pneumocystis jirovecii pneumonie
Chlamydia pneumoniae	negatief
Chlamydia psittaci	negatief
Bocavirus	negatief
Streptococcus pneumoniae	negatief
Legionella pneumophila	negatief



Nasopharyngeal swab SARS-CoV-S negative

Indeterminate: suggestive + inconsistent findings

Adapted from *Consensus statement from Fleischner Society. Published Online: Apr 7 2020*

Moderate to severe features consistent with COVID-19
Any pre-test probability of COVID-19
No significant resource constraints

https://doi.org/10.1148/radiol.2020201365

Diagnostic work-up for alternative diagnosis

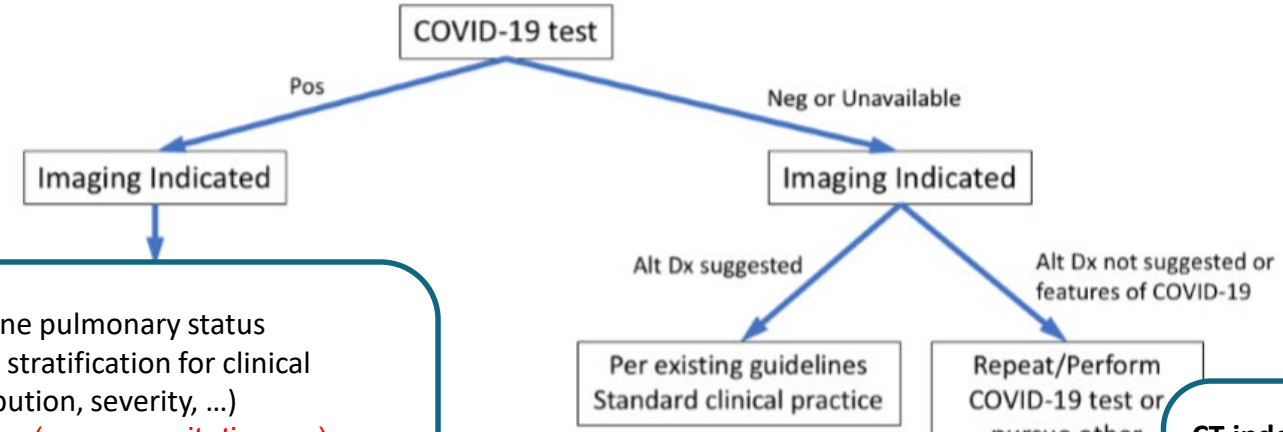

- establishes baseline pulmonary status
- may facilitate risk stratification for clinical worsening (distribution, severity, …)
- can identify **other** (mass, cavitation, ...) underlying pulmonary abnormalities

Timing of bronchoscopy ?

CT **features inconsistent** with covid-19 pneumonia
- central distribution
- peribronchial ; tree-in-bud

Bronchoscopy ?

CT indeterminate or suggestive findings for covid-19 pneumonia in immunocompromised pt

Bronchoscopy BAL ?

Work-up other than COVID-19.

Version 1.2 25 March 2020

Recommendations for day case bronchoscopy services during the COVID-19 pandemic

BTS recommendations

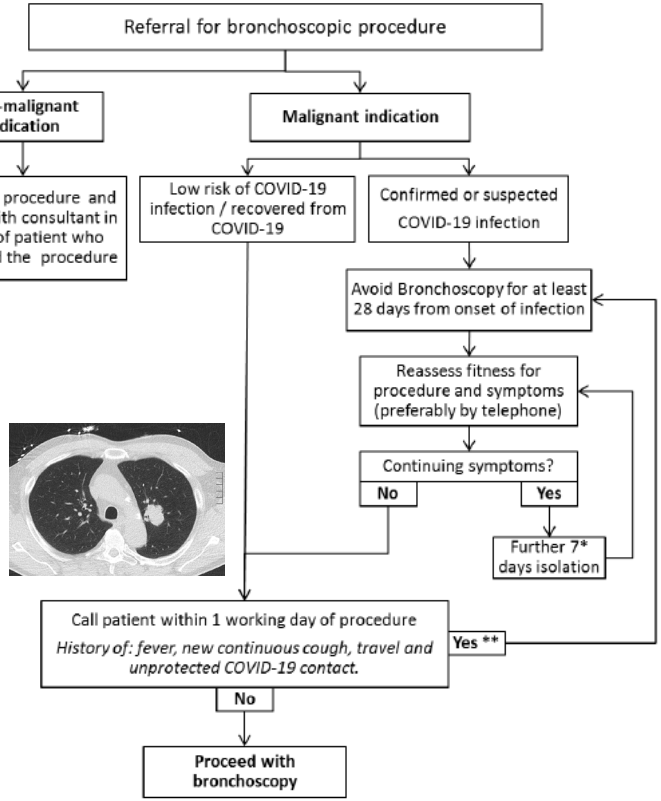

*14 days for low risk patients with household members, according to latest guidance
** This does NOT apply to people who have recently recovered from COVID-19 infection confirmed by PCR, who will not have COVID-19 infection and can proceed to bronchoscopy

Guidance Authorship:
DR Baldwin, WS Lim, R Rintoul, N Navani, L Fuller, I Woolhouse, M Evison. R Booton, S Janes, R Thakrar, M Callister, M Munavvar.

Is there a role for bronchoscopy during COVID-19 pandemic?

- should not be done to rule in COVID-19 infection
- could be considered in COVID-maybe patient when
  # inconclusive / indeterminate findings after less invasive testing.
  # alternative diagnosis is suspected that would impact clinical management (e.g. immunocompromised patient with concern for other viral or pneumocystis or other fungal pneumonia).

  The patient should be “stable” to tolerate a bronchoscopy.
- work-up other findings (e.g. malignancy)



Is there a role for bronchoscopy during COVID-19 pandemic?

World Health Organization

